



DR. SAMUEL HAHNEMANN
GERMANY

GASTRIC DISEASES

Vision of Impossible to Possible

**Treatment of
Incurable Diseases
Like Cancer, Kidney
Failure, Coma, Surgical,
Autoimmune, Life Style
& Life Threatening
Diseases**



PROF. DR. ARPIT CHOPRA JAIN

**M.D Homoeopathy
Critical and Surgical Disease Specialist (India)**

**INVENTOR OF
AAROGYA SUPER SPECIALITY MODERN HOMEOPATHY**

COMPLETE, EASY SAFE, FAST & COST-EFFECTIVE CURE



Dr. Arpit Chopra Jain M.D Homeopath

Critical and Surgical Disease Specialist

Dr. Arpit Chopra Jain: Transforming Global Healthcare with Aarogya super Speciality Modern Homeopathy.

Dr. Arpit Chopra Jain, a pioneer in advanced homeopathic medicine, is set to present groundbreaking clinical data comprising over 3,000 successfully treated cases of critical and surgical diseases — all cured without the need for surgery. This revolutionary treatment approach, developed and practiced exclusively by Dr. Jain, utilizes high-potency homeopathic medicines formulated by him, offering fast, safe, and side-effect-free results.

With over 21 years of experience, Dr. Jain has dedicated his life to providing an alternative yet powerful medical solution that not only preserves the body's original organs but also ensures deep, lasting cures. **His work has gained national and international recognition. He has been honored by India's Vice President, Defense Minister Shri Rajnath Singh, Health Minister Shri J. P. Nadda, and several other dignitaries.** In acknowledgment of his contributions, he has also received a prestigious honorary doctorate from the USA.

Dr. Arpit Chopra Jain proudly represents India on the international stage as the **Homeopathic Representative for BRICS (Russia)** and continues to raise the global profile of homeopathy through his one-of-a-kind center based in Indore, Madhya Pradesh, India. From this single center, he has reached and treated patients from over 19 countries, offering remote consultations and delivering life-changing results globally.

Recently, **Dr. Jain was invited as the Guest of Honor at the highly esteemed United Nations Global Excellence Awards held at the UN Headquarters in New York, hosted by the United Nations Global Peace Council.** This momentous occasion was a testimony to his relentless commitment and global vision for homeopathy.

His work is supported by real, verifiable patient testimonials, including pre- and post-treatment reports, available on his official website and YouTube channel. These authentic stories reflect the effectiveness and rapid healing power of his treatment.

This book is a humble attempt to introduce Dr. Jain's extraordinary journey and his mission — to make the world healthier without surgery, promoting natural healing through scientifically advanced homeopathic medicine. His goal is to create a safer, more cost-effective, and organ-preserving healthcare alternative for patients across the globe.





The identity of any person is his real wealth.

INTRODUCTION

Inventor of Aarogya Super Speciality Modern Homoeopathy, revolutionized treatment for complex diseases

Professor Dr. Arpit Chopra Jain

Professor Dr. **Arpit Chopra Jain**, with over 20 years of medical experience and research, has revolutionized classical homeopathy by developing a future-oriented, super-speciality modern homoeopathy treatment system. His innovative approach has given new physical, mental, and social life to thousands of patients who were once considered incurable, including those suffering from nearly 300 different diseases such as cancer, kidney failure, coma, aplastic anemia, and other serious conditions requiring surgical intervention. In doing so, he has also fulfilled the World Health Organizations (WHO) belief that true health encompasses physical, mental, and social well-being.

Originally from Chhattisgarh, Dr. Arpit Chopra Jain received his primary education in his home state before moving to Indore to pursue a Bachelors degree in Homeopathy. After completing his BHMS, he earned an MD in Homeopathy from DKMM Homoeopathic Medical College in Aurangabad, Maharashtra. During his studies and career, he worked alongside many renowned allopathic doctors in Indore and other locations, acquire practical experience and contributing to medical advancements.

Currently, Dr. Arpit Chopra Jain is providing medical services through the Aarogya Super Speciality Modern Homoeopathy Clinic, located at Janjirwala Square in Indore, where he leads a team of experienced professionals. In addition to his clinical work, Dr. Arpit Chopra Jain plays a pivotal role in shaping homeopathic education as an educator at RN Kapoor Homoeopathic Medical College. His research focuses on complex blood-related diseases, including aplastic anemia and sickle cell anemia.. Driven by a commitment to innovation, Dr. Jain has been nationally and internationally recognized for his groundbreaking contributions to the treatment of complex and incurable diseases. His exceptional service during the COVID-19 pandemic further highlights his dedication to advancing modern homeopathic medicine.

Many of Dr. Arpit Chopra Jain's patients regard him as a godsend, praising his unwavering commitment to serving humanity. Beyond his medical practice, Dr. Arpit Chopra Jain, who hails from a family of 19 physicians, is making significant contributions to society and the Nation.

He firmly believes that Aarogya Super Speciality Modern Homoeopathy - instant, effective, affordable, and without side effects is the future of homoeopathy. While homoeopathy may have originated in Germany, Dr. Arpit Chopra Jain is confident that India's revolutionary modern homoeopathic medical system will one day be recognized globally, inscribing India's name in golden letters on the world health chart. He and his team are making every possible effort to achieve this vision and will continue to do so.



Golden India's Revolutionary Discovery: Pioneering the Future of Healthcare with Advanced Homoeopathy

Homoeopathy, a system of alternative medicine established over 200 years ago by German physician Dr. Samuel Hahnemann, has experienced widespread adoption across various countries, including India. However, over time, it faced criticism and was even banned in certain regions due to persistent myths and misconceptions, such as its alleged placebo effect. Critics claimed that homoeopathic remedies were ineffective, slow to act, and not backed by scientific evidence, leading to widespread skepticism among both the public and the scientific community.

One significant issue was that classical homoeopathy relied heavily on treating patients based on symptoms alone, without extensive clinical documentation or diagnostic reports. This absence of empirical evidence made it challenging to validate its effectiveness through conventional medical research methods.

In response to these challenges, Dr. Hahnemann later developed a more potent form of homoeopathic medicine, known as the 50 millesimal potency, or 5 million power. However, by the time this advancement was introduced, classical homoeopathy had already established deep roots, and the lack of continued research, documentation, and clinical validation led to its gradual decline in some regions.

Recognizing the need to address these limitations, Professor Dr. Arpit Chopra Jain, with over 20 years of clinical and hospital experience, pioneered a groundbreaking approach known as Super Speciality Modern homoeopathy. Utilizing the powerful 50 lakh potency homoeopathic medicines, along with mother tinctures, biochemic treatments, and dilutions, Dr. Jain's revolutionized the practice by effectively treating severe autoimmune conditions, including cancer, kidney failure, aplastic anemia, sickle cell anemia, rheumatoid arthritis, ankylosing spondylitis, and many other life-threatening illnesses. This innovative treatment approach has produced remarkable results, enabling patients suffering from complex and incurable diseases to recover without any side effects or lifelong medication dependency. Dr. Jain's method has proven particularly effective in cases previously deemed untreatable, such as patients in comas, those with brain tumors, or those in the terminal stages of illness.



His success extends beyond India, benefitting patients in countries such as Pakistan, Dubai, Bangladesh, the United States, and the United Kingdom.

A key differentiator of Super Speciality Modern Homoeopathy is its integration of clinical pathology alongside traditional symptom-based diagnosis. Dr. Jain's has meticulously collected pre- and post-treatment test reports from over 3,000 successfully treated patients, along with their written testimonials and interviews, both online and offline. This substantial body of evidence aims to secure recognition for his treatment methodology within the broader medical community, ensuring future generations of homoeopathic practitioners can offer hope to patients who might otherwise remain hopeless.

Dr. Jain's innovative work continues to shape the future of homoeopathy providing a new path forward for both patients and healthcare providers worldwide.



Complete Cure, Permanent, Easy, Safe, Fast, Cost Effective.

Aarogya Super Specialty Modern Homoeopathy -

It is a modern medical science which incorporates the basic nature of homoeopathy and keeps it as its basis and includes many other new features.



Easy Method -

In Aarogya Super Speciality Modern Homoeopathy, a variety of homoeopathic medicines are utilized, including decimal potency, centesimal potency, 50 millesimal potency, mother tinctures, biochemic medicines, The method of administering these medicines is straightforward and can be easily followed in the prescribed dosage under the guidance of a qualified homoeopathic doctor. One of the unique aspects of Aarogya Super Speciality Modern Homoeopathy is that it does not work with the traditional restrictions often associated with homoeopathic treatment, such as avoiding strong-smelling substances during medication. Due to the high quality and potency of the medicines used, these minor misconceptions hold no relevance in this advanced system of treatment. This approach allows for effective treatment without the need for strict dietary restrictions, making it more accessible and easier for patients to adhere to. Aarogya Super Speciality Modern Homoeopathy excels in providing top-tier treatment with minimal medication, even for complex and difficult-to-treat conditions. In this system, various diseases are treated directly and comprehensively, whether through homoeopathic medicines alone or in combination with supportive medicines from other medical systems, depending on the patients condition and the nature of the disease. This holistic approach ensures that patients receive the most effective and personalized care

Harmless Medical Method -

One of the most remarkable aspects of Aarogya Super Speciality Modern Homoeopathy is its safety profile, even when high potencies are used. Unlike conventional treatments where the risk of side effects increases with the dosage of active ingredients, homoeopathic medicines are carefully prepared through a process called potentiation. In this process, the original substance is diluted while simultaneously increasing its potency. This unique method ensures that only a minimal amount of the chemical or raw material remains in the final product. As a result, Aarogya Super Speciality Modern Homoeopathy offers highly effective treatments without the risk of harmful side effects. The approach is practically unmatched in other branches of medical science, where larger doses of active substances can often lead to adverse reactions. In this way, modern homoeopathy provides a safe and natural healing method, making it an ideal option for individuals seeking a harmless yet potent solution to their health issues.

Fast Aggressive Treatment -

One of the most remarkable aspects of Aarogya Super Speciality Modern Homoeopathy is its fast and aggressive healing process, setting it apart from conventional homoeopathy. In this advanced system, medical expertise is combined with cutting-edge technology, including computerized software, to ensure rapid, accurate diagnosis and treatment. Doctors utilize a vast array of over 4,000 potent medicines, with strengths ranging from zero potency to an astonishing 50 lakh potency, making the treatment scientifically robust and effective for a wide range of diseases. The precision of this method allows doctors to quickly gather and analyze detailed information about a patients condition, helping them select the most suitable remedy. This tailored approach ensures that even severe, surgical, or seemingly incurable conditions are addressed efficiently and effectively. What makes this treatment truly revolutionary is its ability to provide fast relief without any side effects, transforming it into a powerful, unique, and highly reliable branch of medical science.

Complete cure of diseases from the root -

Aarogya Super Speciality Modern Homoeopathy aims to heal the patient completely body, mind, and soul ensuring not only recovery from current ailments but also preventing the recurrence of diseases throughout life. This holistic approach to treatment is a crucial aspect of any effective medical science.

This fast and aggressive treatment approach embodies the future of homoeopathy, offering hope to patients facing complex diseases while maintaining the core principles of safety, simplicity, and efficacy.

Cost-Effective Treatment with Aarogya Super Speciality Modern Homoeopathy

Despite its advanced and multifaceted approach, Aarogya Super Speciality Modern Homoeopathy remains highly affordable and accessible, making it a preferred choice for many. Compared to other medical systems, it offers a cost-effective solution while providing complete, safe, and test treatment. This affordability, combined with its ability to deliver immediate results without harmful side effects, has contributed to the growing global popularity of modern homoeopathy. Today, homoeopathy is trusted by millions, with affordable medicines available to those in need. Every fourth person in the world now benefits from homoeopathy in some form, relying on its holistic and comprehensive approach to healthcare.



Dr. Arpit Chopra Jain, M.D. in Homoeopathy and the inventor of Aarogya Super Speciality Modern - Homoeopathy, has been instrumental in making this revolutionary treatment accessible to people from all walks of life. His commitment to providing effective, affordable, and harmless treatment has redefined the landscape of healthcare, offering hope and healing to thousands.



Dr. Arpit Chopra (Jain)
 M.D. HOMOEOPATHY
 Inventor of Aarogya Super Speciality Modern Homoeopathy



Aarogya Super Speciality Modern Homoeopathy



Successful Treatment of Critical Health Conditions

Dr. Jain's innovative treatment method has shown exceptional results in managing and curing serious health conditions, including:

- Cancer
- Kidney Diseases
- Coma
- Blood Disorders such as sickle cell anemia and aplastic anemia
- Arthritis
- Autoimmune Diseases
- Neurological Disorders
- Heart Diseases
- Skin Conditions like psoriasis and dermatitis

Through a deep understanding of the body's internal balance, Aarogya Super Speciality Modern Homoeopathy targets the root causes of these diseases, promoting natural self-healing without the need for invasive procedures or lifelong medications.

Revolutionizing Disease Treatment

Aarogya Super Speciality Modern Homoeopathy, developed by Dr. Arpit Chopra Jain, has introduced a groundbreaking, holistic approach to treating a wide range of complex and chronic diseases. This method offers a comprehensive, harmless, cost-effective, and permanent solution, achieving remarkable success where conventional treatments often fall short.

Efficacy Across a Wide Range of Diseases

With a proven record of success in treating nearly 300 different diseases, Aarogya Super Speciality Modern Homoeopathy offers relief from conditions that affect various aspects of health. Patients suffering from:

- Allergies
- Womens Health Issues
- Urological and Gastric Problems
- Rheumatoid Arthritis
- Pediatric Conditions
- Spinal Cord Disorders

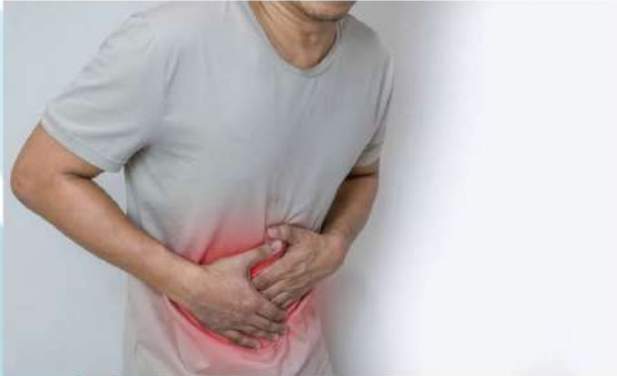have all experienced life-changing results through this pioneering method.



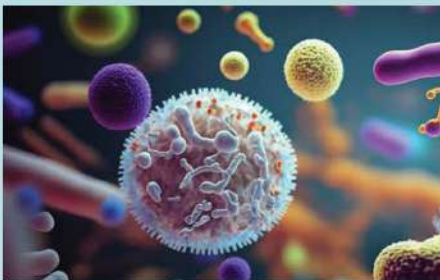A New Lease on Life

What truly sets this treatment apart is its ability to provide lasting and permanent relief. Patients who were previously dependent on lifelong medication or faced invasive surgeries have regained their health, returning to a normal, medication-free life. Aarogya Super Speciality Modern Homoeopathy continues to transform lives, offering a new, holistic approach for those suffering from complex and chronic diseases.

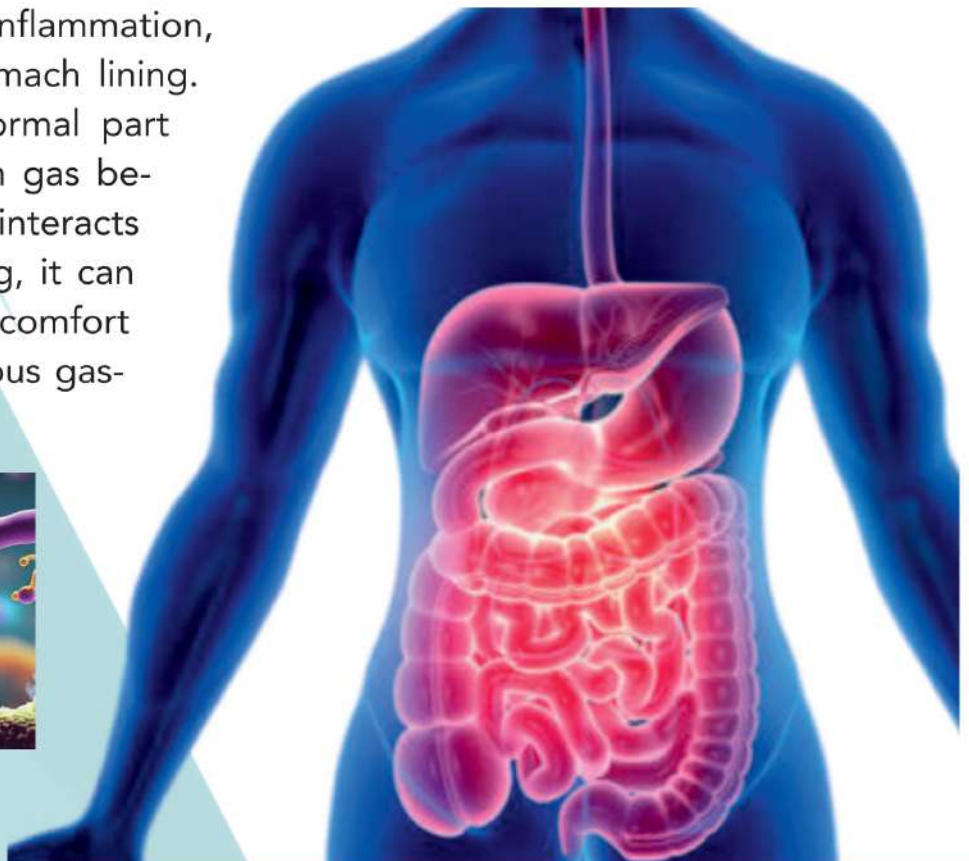
Gastric Diseases




Gastric issues are among the most prevalent health concerns worldwide, often emerging after the age of 40. These problems can manifest as burning sensations, inflammation, or damage to the stomach lining. Gas formation is a normal part of digestion, but when gas becomes trapped and interacts with the stomach lining, it can lead to significant discomfort and contribute to various gastrointestinal diseases.



Dr. Arpit Chopra Jain's, a distinguished expert in homoeopathy with over 20 years of medical experience, offers a promising alternative. His innovative treatment approach has successfully addressed severe gastric and gas-related issues without side effects, dietary restrictions, or the high costs associated with traditional treatments. Dr. Arpit Chopra Jain's Super Speciality Modern Homoeopathy method has provided many patients with lasting relief and a return to normalcy.

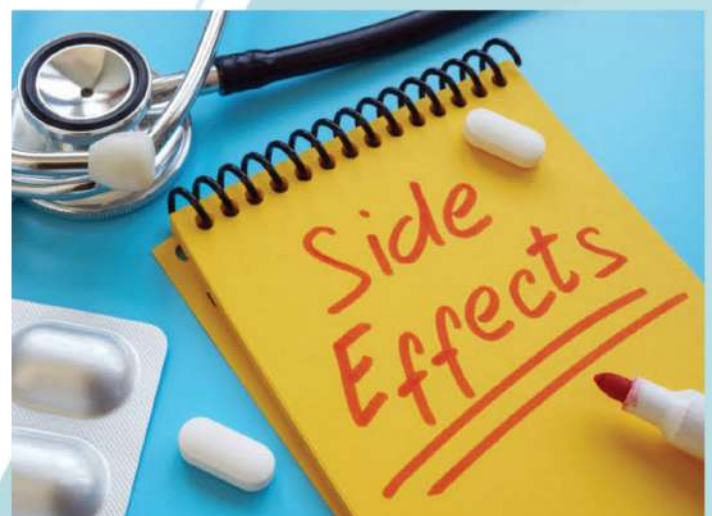

Common gastric conditions include Chronic Pancreatitis, Fatty Liver Disease, Gallstones, Hepatocellular Carcinoma, Gastroesophageal Reflux Disease (GERD), Liver Cirrhosis, Ulcerative Colitis, Anal Fissures, Irritable Bowel Syndrome (IBS), and Celiac Disease. These issues can affect both adults and children, often exacerbated by lifestyle factors. While gas problems might seem minor, they can cause considerable distress, particularly for those who experience them frequently or from a young age.



In summary, while gastric problems are common and can significantly impact quality of life, traditional treatments may not always offer permanent solutions. Dr. Arpit Chopra Jain's Super Speciality Modern Homoeopathy approach presents a viable option for those seeking effective and affordable treatment for gastric issues, leading to improved health and well-being.

The main contributors to excessive gas include poor eating habits, overeating, inadequate chewing, excessive worry, alcohol consumption, and sometimes, the overuse of medications. Conventional allopathic treatments often struggle to offer a permanent solution, typically relying on long-term medication management.





डॉ. अर्पित चोपड़ा (जेन)
एम.टी. होम्योपैथी
जटिल, असाध्य एवं
शान्त रोग विशेषज्ञ

आरोग्य सुपर स्पेशलिटी मॉडर्न होम्योपैथिक क्लीनिक



कम्पलिट * परमानेंट * ईजी * सेफ * फास्ट एण्ड कॉस्ट इफैक्टिव

* कैंसर * किडनी फेलियर * अस्पताल में गंभीर रूप से भर्ती मरिजों का उपचार * कोमा *
* शल्य चिकित्सा योग्य रोग * आँटो इम्यून रोग * जीवनभर दवाई लेने वाले रोगों की रोकथाम
एवं 300 प्रकार के असाध्य जटिल रोगों की चिकित्सा।

102, 104, प्रथम मंजिल, कृष्णा टॉवर, क्योरवेल हॉस्पिटल के सामने, जंजीरवाला चौराहा, न्यू पलासिया, इन्दौर (म.प्र.)

फोन : 0731-4977076, मो. : 97130-92737, 97130-37737, 79999-78894, 99075-27914

Swastik Diagnostic Centre
Showroom No. 2 Basement, R.D.A. Complex, Jail Garden Road Raebareilly

Name: Mrs. Anur Kati
Ref By: Dr. Virendra Singh M.S.
Part Scanned: WHOLE ABDOMEN

Age: 45yrs F
Date: 24/02/2020
1 अप्रैल 2020 से सैनिक
लेक रिपोर्ट को बन्द रखें
दिनवार को कुर्बि लेंगे।

REPORT

Liver: Liver is seen normal in size with liver parenchyma is homogeneous in echogenicity. Margins are smooth & regular. Intrahepatic biliary radicles are not dilated & vascular structures are normal. No diffuse or focal mass seen.
CBD: CBD is seen dilated (11.4mm) in size. Single echogenic shadow of 6.7mm size with post. Acoustic shadowing is seen in distal end of CBD, suggestive of calculus. Portal vein - Portal vein at porta hepatis is normal in size (11.4mm).

Gall Bladder: GB is not seen. GB fossa is seen clear.

Pancreas: Normal in size, shape & echogenicity. Margins are smooth & regular. Pancreatic duct is not dilated. No diffuse or focal lesions seen.

Spleen: Spleen is seen normal 91.3mm in size & normal in shape & echogenicity. Margins are smooth & regular. No diffuse or focal lesion seen. No calcifications in splenic hilum.

Kidneys: Both the kidneys are seen normal in shape & size. Corticomedullary differentiation is maintained. Pelvicocalyceal system are not dilated. No evidence of hydronephrosis. Cortical echoes are normal. No diffuse or focal lesions are seen. Perinephric area appeared normal.
Right Kidney: (86.5mm * 37.4 mm)
Left kidney: (87.3 mm * 39.1 mm)

Urinary Bladder: Normal in filling & contour. Wall thickness is normal. Lumen is anechoic. Both VUJ appear normal. No calculus or mass lesion seen.

Uterus: Uterus is seen anteverted & measures approx. 64.1 * 36.3 * 47.0 mm. Endometrial echoes are seen normal in midline & its thickness is 4mm. Myometrial echoes are normal. No evidence of any mass lesion.

Adnexae: Both ovaries are seen normal. No evidence of any adnexal mass or fluid collection seen.
No retroperitoneal lymphadenopathy.
No free fluid is seen in peritoneal cavity.
Bowel loops are seen normal with normal peristaltic movement.
Both domes of diaphragm showed normal movement with no evidence of pleural effusion or subdiaphragmatic pathology.
Both ureters are not visualized in their whole of length due to gas in adv. X-ray KUB for ureters if needed.

Impression: Dilated CBD with Cholelithiasis. Liver, Pancreas, spleen appear normal. Kidneys, Uterus, Adnexa appear normal.

Dr. Shailja Gupta
M.B.B.S. (Sardar)

समर्पण
Imaging & Diagnostics

15-20, Ground Floor, Yashwanth Plaza, Opp. Railway Station, Indore (M.P.)
0731-4068123, 4967633, 88899-33684
samarpanimaging@gmail.com
www.samarpanimaging.com

Patient Name: ANARKALI YADAV
Date: 25/12/2020
Ref. by: DR. ARPIT CHOPRA
Age/ Sex: 42y/F

WHOLE ABDOMEN SONOGRAPHY

This examination was performed as an essential examination during the Covid-19 with all precaution & inherent limitation to results.

Hepatic contour is smooth & span (15.5 cm) is normal. Parenchymal echotexture is raised. No focal lesion is seen. Intrahepatic biliary radicles are undilated.

Gall bladder is not visualized (Post operative status).
No sludge or calculus seen in CBD. Portal vein is normal in caliber.

Pancreas is normal in shape & size. Parenchymal echoes are normal. Pancreatic duct is undilated.

Spleen is normal 9.5 cm. No focal lesion seen.

Both kidneys are normal in position & size. Renal contour is smooth. Cortical echoes are normal. Pelvicocalyceal system is undilated.
Right kidney is 9.6 x 3.8 cm and Left kidney is 9.5 x 4.7 cm in size.

Urinary bladder shows normal walls & echo free lumen.
Pre-void urine = 404.4 ml (approx).

Uterus is anteverted & normal in size. It measures 7.5 x 3.7 x 3.9 cm. No focal myometrial lesion seen. Endometrial is measuring 6.6 mm.

Both adnexa & ovaries are normal in size.
No significant retroperitoneal lymphadenopathy seen.
No free fluid seen in peritoneal cavity. The dependent pleural recess are normal.

IMPRESSION:- FATTY INFILTRATION OF LIVER GRADE I.

Clinical Correlation.

DR. HEMLATA MUJALDA,
MBBS, MD, RADIOLOGIST
REG. NO. MP- 12294

क्या आप गाल ब्लैडर स्टोन से परेशान हैं

गाल ब्लैडर स्टोन कैसे खत्म करें

Gallstone blocking common bile duct

Gallstones

20:20

Treatment Of Gall Bladder Stone By Modern Home

Monday 28

Cholelithiasis

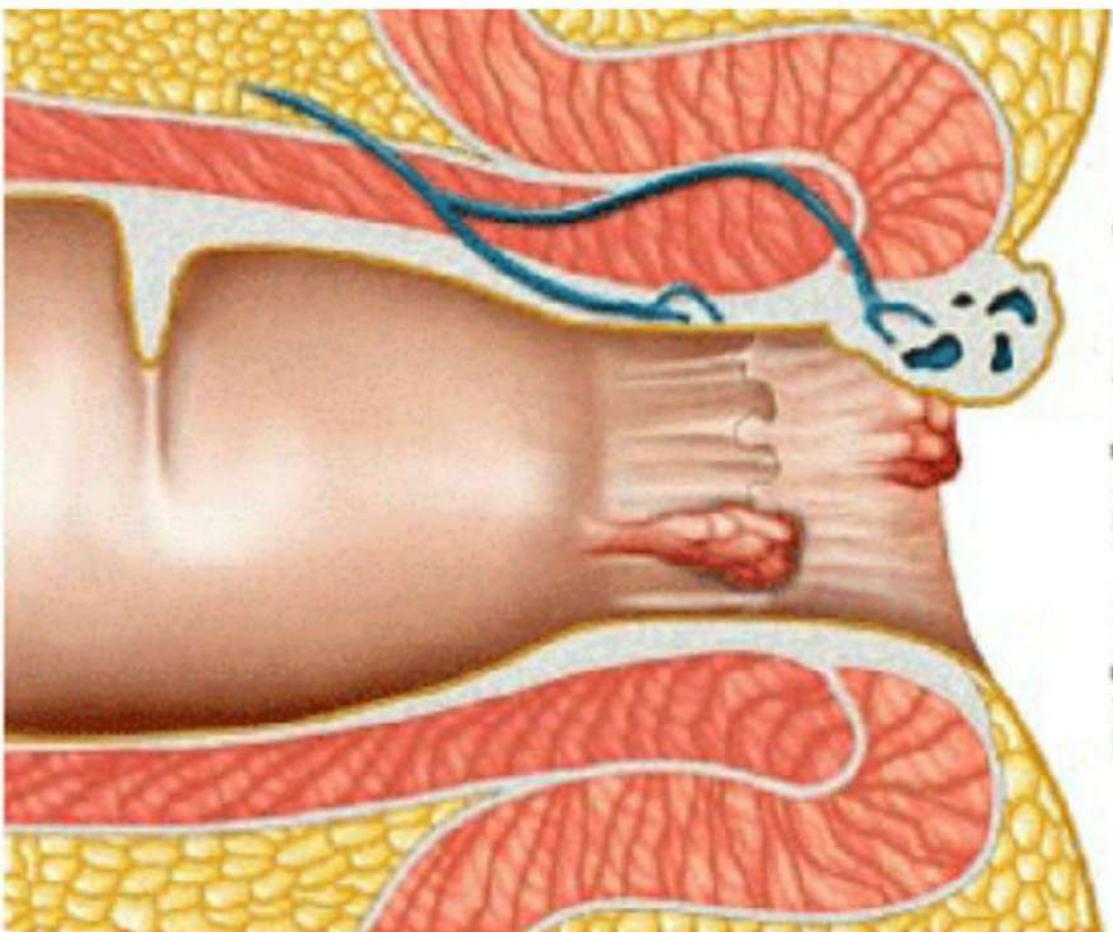
ना नाम चोपड़ा जी साहब जी मे
राम मुबारक जिनो प्रायोग (उ.प्र.)
रुग्ना है। मेरे आँटो की नदी से 6mm
की पथरी केस हो रही है। इसे
उपचार के बिना मेरे शरीर में
बहुत बुरा हो सकता है। मेरे
को उपचार करवा देना। मेरे
बच्चे को भी इससे बचाने के लिए
मेरी पत्नी को उपचार करवा देना।
मेरे बच्चे को भी उपचार करवा देना।
मेरे बच्चे को भी उपचार करवा देना।
मेरे बच्चे को भी उपचार करवा देना।

9754621729

DR. Arpit Chopra (Jain)
M.D. HOMOEOPATHY

AROGYA SUPER SPECIALITY MODERN HOMEOPATHIC CLINIC

Piles Advise & Treatment Option



SHITIA

09

Thursday
32nd Week • 221-144

(Piles)

Alcalist 2018

09:00

मेरी पेशेवर सेवा भारत में 55 साल
पुर्वे 25 वीं उम्र में पारिस की प्राणिक

10:00

मेरी बहुत प्रेरणा थी मैं कभी कभी
लेने के बाद केवल कुछ कायादा नहीं हुआ

11:00

फिर मेरे आयरसन ठहराया लिया और
कुछ समय बाद मुझे देवारो देवोडा

12:00

देने लगी, फिर मुझे 1000 प्रतिदिन के
आरोप्य, सुपर स्पेशलिटी, डॉ. अश्विनी
ज्यासा के निषय में जानाया मुझे.

14:00

3 महीने के कुछ दिनों में
होना शुरू हुआ जोड़ जायम नहीं

16:00

वर्षिका पूरी तरह से बढ़ दी गई
और अब मैं सब रोग स्थानी है

17:00

18:00

10016 परेशानों से
डॉ. श्री. 9826889119

20:00

19:00

Dr. Arpit Chopra (Jain)

MD-Homoeopathy (Reg.No-14367)

AAROGYA SUPER SPECIALITY

Modela Homoeopathic Clinic/Computerized

1 2 112, First Floor, Krishna

AUG

2018

19

20

21

22

23

24

25

26


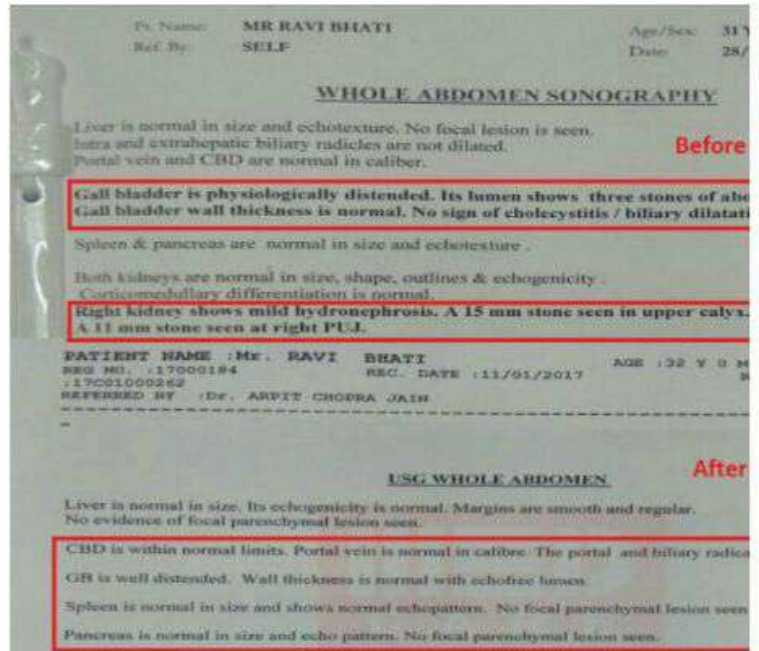

27

28

29



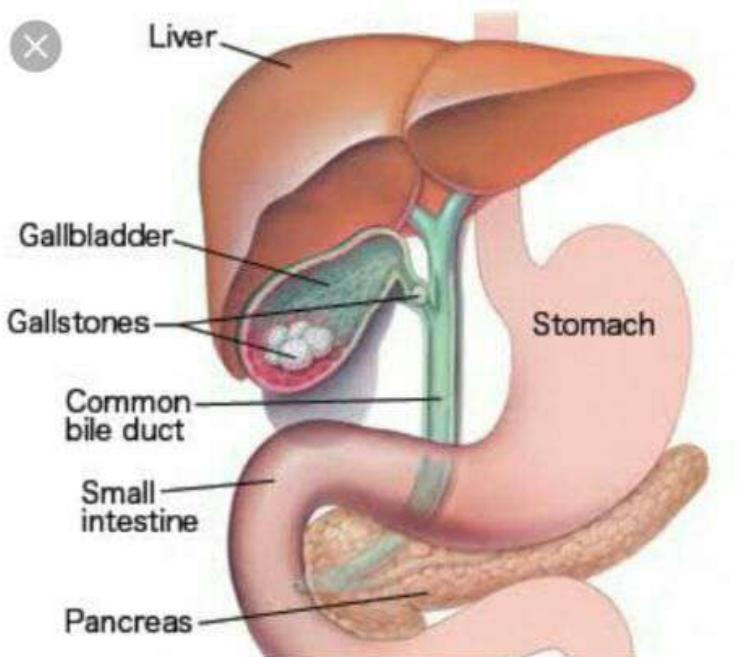
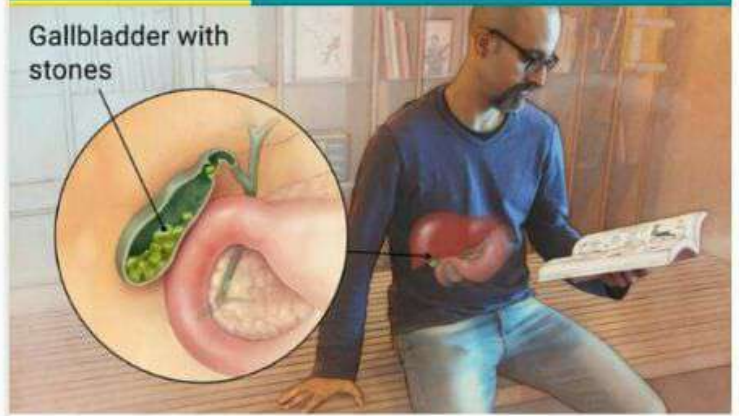
30

31

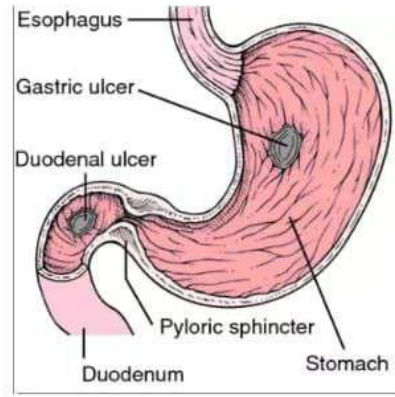
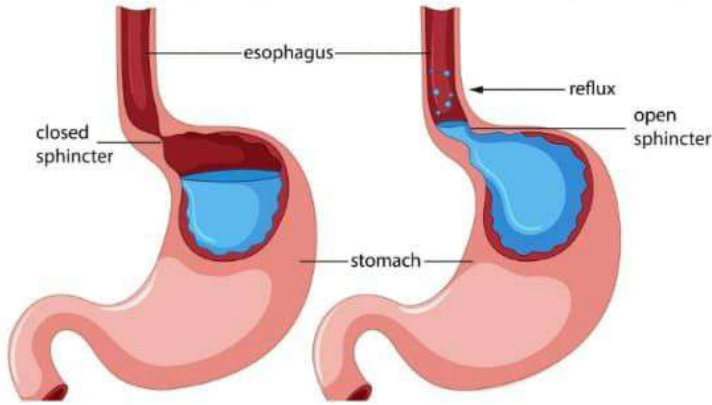


Gallstones
 Also called: cholelithiasis

ABOUT **SYMPTOMS** **TREATMENTS**



Gastroesophageal reflux disease (GERD)



कैंसर, किडनी फेलियर, अस्पताल में गंभीर रूप से भर्ती मरिजों का उपचार, कोमा, शल्य चिकित्सा योग्य रोग, ऑटो इम्यून रोग, जीवनभर दवाई लेने वाले रोगों की रोकथाम एवं 300 प्रकार के असाध्य जटिल रोगों की चिकित्सा।

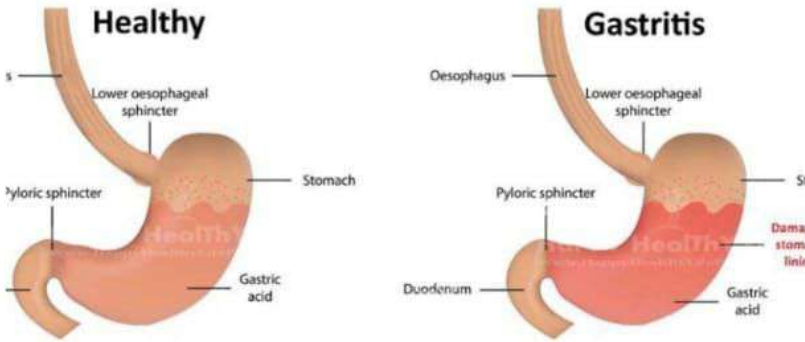
आरोग्य सुपर स्पेशलिटी माडर्न होमियोपेथी
 कम्पलिट, परमानेन्ट, ईजी, सेफ, फास्ट एण्ड कॉस्ट इफैक्टिव

102, प्रथम मंजिल, कृष्णा टॉवर, बयोरसेल हॉस्पिटल के सामने, जंजीरवाला चौराहा, न्यू पलासिया, इन्दौर म.प्र.
 99075 27914 संपर्क : 0731-4977076, 79999 78804
 www.homeoopathyure.in www.aarogyahomeoopathyindore.com Email : arpitchoora23@gmail.com

इंडियन होम्योपैथी
 Modern Homeopathy - Complete, Permanent, Easy, Safe, Fast & Cost Effective

आरोग्य सुपर स्पेशलिटी माडर्न होमियोपेथी
 Complete, Safe, Fast & Cost-effective Permanent Modern Homeopathy Cure with A
 Phone : 0731-4977076, Mobile : 97130-92737, 97130-37737, 79999-7889

Gastritis



माडर्न होम्योपैथी
 Modern Homeopathy - Complete, Permanent, Easy, Safe, Fast & Cost Effective

ANIL KUMAR

Dr. Arpit Chopra (Jain)
 (MD) HOMEOPATHY
 Critical & Surgical Disease Specialist
 Mentor, Of Super, Speciality, Modern Homeopathy

आरोग्य सुपर स्पेशलिटी माडर्न होमियोपेथी
 Complete, Safe, Fast & Cost-effective Permanent Modern Homeopathy Cure with A
 Phone : 0731-4977076, Mobile : 97130-92737, 97130-37737, 79999-7889

Gallstones

Also called: cholelithiasis

- Overview
- Symptoms
- Treatments

A hardened deposit within the fluid in the gallbladder, a small organ under the liver.

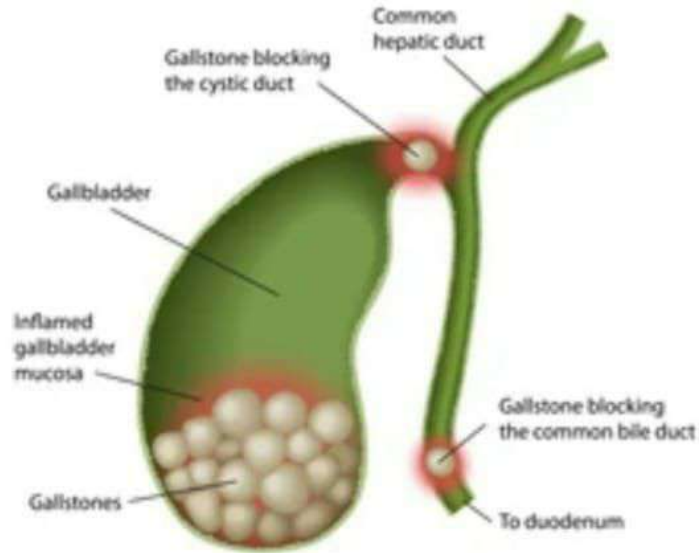
Gallstones are hardened deposits of digestive fluid.

Very common

More than 10 million cases per year (India)

- Treatable by a medical professional
- Requires a medical diagnosis
- Lab tests or imaging always required
- Chronic: can last for years or be lifelong

Gallstones



NAGPAL CLINIC & ULTRASOUND
 G-6, Santa Vihar, New Delhi - 110 076
 Ph. : +91-11-29941886, 9811147137, E-mail : nagpal@yashwan.com
 IAF ISO 9001:2008 Certified

NAME: Mr. ATUL SAXENA
 REF BY: SELF
 AGE: 59 YRS/M
 DATE: 02/05/2022

ULTRASOUND WHOLE ABDOMEN

Liver is normal in size, contours and echogenicity. Intrahepatic biliary radicles are not dilated. Portal and hepatic veins are normal.

Gall bladder shows two mobile echogenic foci with distal acoustic shadowing measuring 5.3 mm & 3.7 mm in the lumen. However, gall bladder shows smooth thin walls. No pericholecystic fluid collection seen. Porta hepatis and extrahepatic biliary system are normal.

Spleen is normal in size, contours and echogenicity.

Pancreas is normal in size, contours and echogenicity.

Right kidney shows normal size, shape, outline, echotexture. Cortico-medullary differentiation is maintained. No evident pelvicalyceal dilatation or renal calculus is seen. Right kidney measures 97 x 47 mm.

Left kidney shows normal size, shape, outline, echotexture. Cortico-medullary differentiation is maintained. No evident pelvicalyceal dilatation or renal calculus is seen. Left kidney measures 101 x 50 mm.

Retroperitoneal structures and great vessels are normal. No evident lymphadenopathy or free fluid collection is seen.

Urinary bladder is normal.

There is evidence of enlargement of prostate with hypertrophy of median lobe of prostate, projecting into bladder base. Prostatic volume is 34.1 cc. Calcification noted in prostatic parenchyma.

Post-void is insignificant.

before Treatment

OPINION: - ULTRASOUND FEATURES ARE SUGGESTIVE OF:

- CHOLELITHIASIS WITH PROSTATIC PARENCHYMA
- PROSTATOMEGALY WITH PROSTATIC PARENCHYMA
- CALCIFICATION - LIKELY BHP

Please correlate clinically.

DR. KANIKA NAGPAL
 M.D. RADIODIAGNOSIS

THIS IS ONLY A PROFESSIONAL OPINION AND NOT THE DIAGNOSIS NOT VALID FOR MEDICO-LEGAL PURPOSE.

NAGPAL CLINIC & ULTRASOUND
 G-6, Santa Vihar, New Delhi - 110 076
 Ph. : +91-11-29941886, 9811147137, E-mail : nagpal@yashwan.com
 IAF ISO 9001:2008 Certified

NAME: Mr. ATUL SAXENA
 REF BY: SELF
 AGE: 59 YRS/M
 DATE: 07/06/2022

ULTRASOUND WHOLE ABDOMEN

Liver is normal in size, contours and echogenicity. Intrahepatic biliary radicles are not dilated. Portal and hepatic veins are normal.

Gall bladder shows echofree lumen with smooth thin walls. No pericholecystic fluid collection seen. Porta hepatis and extrahepatic biliary system are normal.

Spleen is normal in size, contours and echogenicity.

Pancreas is normal in size, contours and echogenicity.

There are mild backpressure changes in bilateral kidneys in full bladder state which decrease in post void state.

Right kidney shows normal size, shape, outline, echotexture. Cortico-medullary differentiation is maintained. No evident renal calculus is seen. Right kidney measures 98 x 49 mm.

Left kidney shows normal size, shape, outline, echotexture. Cortico-medullary differentiation is maintained. No evident renal calculus is seen. Left kidney measures 109 x 53 mm.

Retroperitoneal structures and great vessels are normal. No evident lymphadenopathy or free fluid collection is seen.

Urinary bladder is normal in position, outline & capacity.

Prostatomegaly noted. Prostatic volume is 36.4 cc. Prostate is normal in echotexture.

Post-void urine volume measures 53 cc.

after Modern Homoeopathy treatment

Please correlate clinically & with other investigations.

DR. KANIKA NAGPAL
 M.D. RADIODIAGNOSIS

* c/o Cholelithiasis
 → two mobile calculi 5.3 mm & 3.7 mm
 → BHP (Calcification noted in Prostatic Parenchyma)
 Volume - 34.1 cc
 → Urinary stricture obstruction 20%
 → Drizzling micturition
 → Flatulence ++
 → Anxiety +
 → H/o Covid 19 (Dec 2020)
 → Bacteraemia

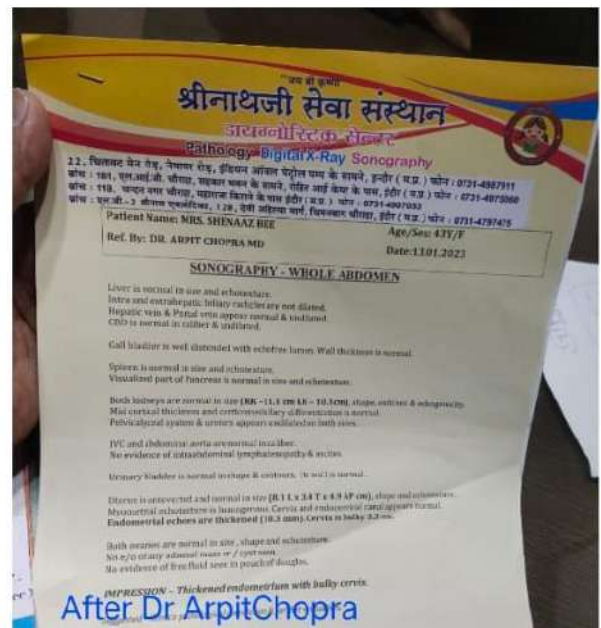
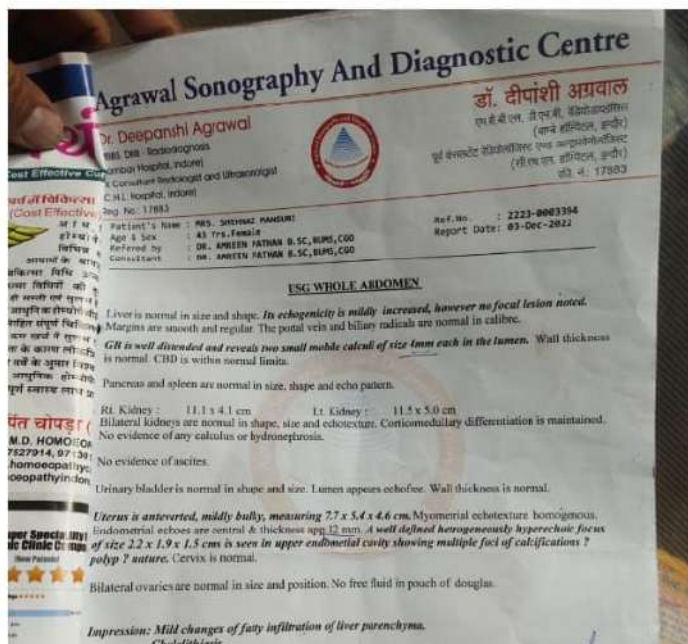
कैसर, किडनी फेलियर, अस्पताल में गंभीर रूप से भर्ती मरिजों का उपचार, कोमा, शल्य चिकित्सा योग्य रोग, ऑटो इम्यून रोग, जीवनभर दवाई लेने वाले रोगों की रोकथाम एवं 300 प्रकार के असाध्य जटिल रोगों की चिकित्सा।

आरोग्य सुपर स्पेशलिटी माईन होमियोपेथी

कम्प्लिट, परमानेन्ट, ईजी, सेफ, फास्ट एण्ड कॉस्ट इफैक्टिव

102, प्रथम मंजिल, कृष्णा टॉवर, कयोरवेल हॉस्पिटल के सामने, जंजीरवाला चौराहा, न्यू पलासिया, इन्दौर म.प्र.
 99075 27914 संपर्क : 0731-4977076, 79999 78894
 www.homoeopathycure.in. www.aarogvahomoeopathyindore.com Email : arpit Chopra23@gmail.com

Gall Bladder stone & Uterine polyp of cured by Dr Arpit Chopra Jain Modern Homoeopathy saved surgery



पुस्तिका... 1

PANCREATITIS

नाम: आशिष अजित
 पता: Setlly Junction 1276 Indore.
 मो: 9754155345

मैं अकामिश भुक्ति 10 महीने से
 आग्नाशुय (Pancreas) & liver को
 बीमारी से बड़ा जाया वैधान था।
 जहाँ Hospital हुआ परामर्श इनको
 कही नहीं माना। फिर डॉ. अजित जी
 ने मेरे से सलाह कराया 15 दिनों में
 ही आराम लगने लगा 1 month में
 90% तक से अच्छा रिफ़र हो चुका
 था। मैं डॉ. अजित सर को Thanks

FEB MAR APR MAY JUN

Bhopal Institute of Gastroenterology Pvt. Ltd
GASTRO CARE LIVER & DIGESTIVE DISEASE CENTRE
 Advanced Gastroenterology & Hepatology Centre

Dr. PANKAJ GOEL
 M.D. (GASTROENTEROLOGY)

UPLABDOMEN

EDUCATION
 Postgraduate in Gastroenterology from All India Institute of Medical Sciences, New Delhi (1997)
 Fellowship in Gastroenterology from All India Institute of Medical Sciences, New Delhi (1999)
 Fellowship in Gastroenterology from Postgraduate Institute of Medical Education and Research, Chandigarh (2001)

Dr. PANKAJ GOEL

आरोग्य सुपर स्पेशलिटी मॉडर्न होम्योपैथिक क्लिनिक

आरोग्य सुपर स्पेशलिटी मॉडर्न होम्योपैथिक क्लिनिक

आरोग्य सुपर स्पेशलिटी मॉडर्न होम्योपैथिक क्लिनिक

July 2021 Week 27
 (883-182) FRIDAY 02

आरोग्य सुपर स्पेशलिटी मॉडर्न होम्योपैथिक क्लिनिक

आरोग्य सुपर स्पेशलिटी मॉडर्न होम्योपैथिक क्लिनिक

आरोग्य सुपर स्पेशलिटी मॉडर्न होम्योपैथिक क्लिनिक

Bhopal Institute of Gastroenterology Pvt. Ltd
GASTRO CARE LIVER & DIGESTIVE DISEASE CENTRE
 Advanced Gastroenterology & Hepatology Centre

Dr. PANKAJ GOEL
 M.D. (GASTROENTEROLOGY)

UPLABDOMEN

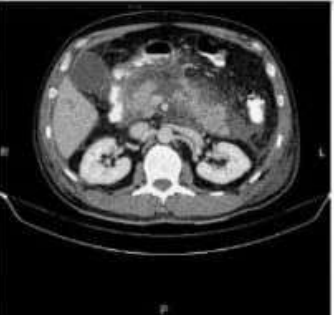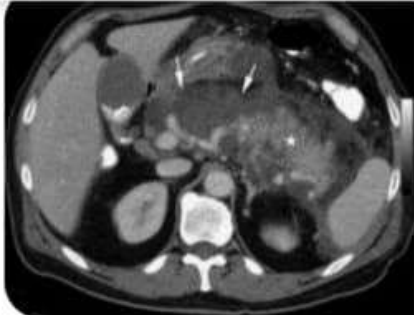EDUCATION
 Postgraduate in Gastroenterology from All India Institute of Medical Sciences, New Delhi (1997)
 Fellowship in Gastroenterology from All India Institute of Medical Sciences, New Delhi (1999)
 Fellowship in Gastroenterology from Postgraduate Institute of Medical Education and Research, Chandigarh (2001)

Dr. PANKAJ GOEL

आरोग्य सुपर स्पेशलिटी मॉडर्न होम्योपैथिक क्लिनिक

आरोग्य सुपर स्पेशलिटी मॉडर्न होम्योपैथिक क्लिनिक

आरोग्य सुपर स्पेशलिटी मॉडर्न होम्योपैथिक क्लिनिक



Necrotizing pancreatitis (NP) is a health problem in which part of your pancreas dies. This is because of inflammation or injury. If the dead tissue gets infected, it can cause serious issues. The pancreas is an organ that sits behind your

What is the survival rate for necrotizing pancreatitis?

Necrotizing pancreatitis (NP) is the most dreadful evolution associated to a poor prognosis: mortality is approximately 15% and up to 30-39% in case of infected necrosis, which is the major cause of death.

आरोग्य सुपर स्पेशलिटी मॉडर्न होम्योपैथिक क्लिनिक

आरोग्य सुपर स्पेशलिटी मॉडर्न होम्योपैथिक क्लिनिक

आरोग्य सुपर स्पेशलिटी मॉडर्न होम्योपैथिक क्लिनिक

Patient's Name : MRS. SANGEETA SARIKANI
Age & Sex : 54 Yrs, Female
Referred by : DR. HEALTH CARE SERVICES
Consultant : DR. ARPIT CHOPRA (JAIN) M.D. HOMEOPATHY

Ref. No. : 3233-0612004
Report Date : 24-Jan-2023

USG Abdomen & Pelvis

Clinical data: Irregular menses

LIVER: is normal in size (13.0 cm) & shows normal echotexture. No evidence of any diffuse or focal pathology. Intrahepatic biliary radicals are not dilated.

GALL BLADDER: is partially distended. No evidence of mass. Gall bladder wall thickness is normal.

A small soft calculus measuring 7 mm noted

PANCREAS: is normal in size and echotexture.

Portal vein & CBD are normal in diameter

SPLEEN: is normal in size (9.0 cms) & echotexture. No evidence of any focal lesion.

KIDNEYS: Right kidney - 9.0 x 3.5 cm Left kidney - 10.0 x 4.0 cm

Both kidneys are normal in size and echotexture. Corticomedullary differentiation is normal. No

evidence of focal lesion, calculus or hydronephrosis.

Urinary Bladder is adequately distended. Wall thickness is normal. No calculi or mass.

Uterus is normal in size, shape and echotexture. It measures 8.0 x 3.0 x 4.5 cms in length,

anteroposterior and transverse dimensions. Endometrial thickness is 3 mm.

Bilateral ovaries are normal in size, shape and echotexture

Right ovary measures 1.5 x 1.5 cms

Left ovary measures 1.5 x 1.5 cms

IVC, aorta are normal. No paraaortic lymphadenopathy

No evidence of any intra abdominal or pelvic mass.

No ascites. No pleural effusion

IMPRESSION:

Cholelithiasis

No significant abnormality seen in rest of abdomen & visualised bowel loops

Patient's Name : MRS. SANGEETA SARIKANI
Age & Sex : 54 Yrs, Female
Referred by : DR. ARPIT CHOPRA (JAIN) M.D. HOMEOPATHY
Consultant : DR. ARPIT CHOPRA (JAIN) M.D. HOMEOPATHY

Ref. No. : 3234-0602007
Report Date : 25-Jan-2023

USG Abdomen & Pelvis

Clinical data: Follow up case of cholelithiasis

LIVER: is enlarged in size (16 cms) & shows raised echotexture (Grade I fatty changes). No evidence of any focal pathology. Intrahepatic biliary radicals are not dilated.

GALL BLADDER: is partially distended. No evidence of calculus or mass. Gall bladder wall thickness is normal.

PANCREAS: is normal in size and echotexture.

Portal vein & CBD are normal in diameter.

SPLEEN: is normal in size (9 cms) & echotexture. No evidence of any focal lesion.

KIDNEYS: Right kidney - 9.0 x 3.5 cm Left kidney - 10.0 x 4.0 cm

Both kidneys are normal in size and echotexture. Corticomedullary differentiation is normal. No evidence of

focal lesion, calculus or hydronephrosis.

Urinary Bladder is adequately distended. Wall thickness is normal. No calculi or mass.

Uterus is normal in size, shape and echotexture. It measures 8.0 x 3.0 x 4.5 cms in length, anteroposterior

and transverse dimensions. Endometrial thickness is 3 mm.

Bilateral ovaries are showing perimenopausal atrophic changes.

Right ovary measures 1.0 x 1.0 cms Left ovary measures 1.0 x 1.0 cms

IVC, aorta are normal. No paraaortic lymphadenopathy.

No evidence of any intra abdominal or pelvic mass.

No ascites. No pleural effusion.

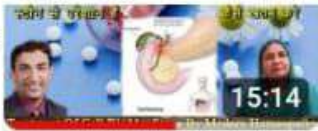IMPRESSION:

• **Hepatomegaly with fatty liver grade I**

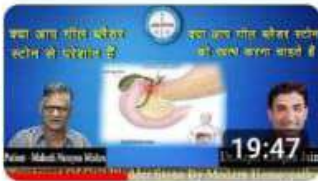• **Resolution of soft calculus which was noted in gall bladder lumen**

• **No significant abnormality seen in rest of abdomen & visualised bowel loops**

After Dr Arpit
Chopra Jain Modern
Homeopathy



सफल इलाज |Gallblade...
Dr Arpit Chopra's SuperS...
1.5K views • 2 years ago



Gallbladder Stone
Homeopathic Medici...
Dr Arpit Chopra's SuperS...
2.1K views • 2 years ago

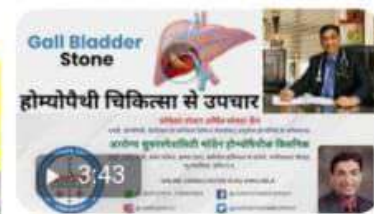
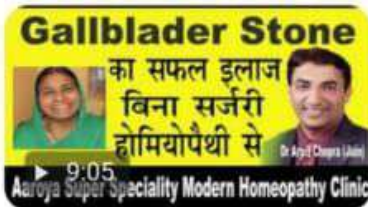
Gall bladder Stone of
7 mm in Common Bil...
Dr Arpit Chopra's SuperS...
2K views • 2 years ago

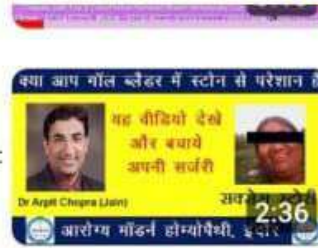

Gallbladder Stone
Aarogya Super Speciality ...
GALL BLADDER STONE (C...

Aarogya Super Speciality ...
Gall Bladder stone & Uterine ...



YouTube



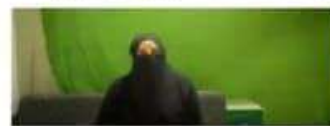Gallbladder stone |
GERD | GERD Cured S...
Dr Arpit Chopra's SuperS...
184 views • 9 months ago



Gall bladder stone
18 mm पित्ताशय या गॉल...
Dr Arpit Chopra's SuperS...
157 views • 6 months ago



Gall bladder stone
18 mm पित्ताशय या गॉल...
Dr Arpit Chopra's SuperS...
205 views • 6 months ago



Gall Bladder stone & Uterine
polyp of cured by Dr Arpit
Chopra Jain Modern
1:00

Gall Bladder sto
& Uterine polyp c
Dr Arpit Chopra's S
150 views • 5 mont

डॉ. अर्पित चौपडा (जैन)
एम. डी. होम्योपैथी
जटिल, असाध्य एवं
शल्य रोग विशेषज्ञ

आरोग्य सुपर स्पेशलिटी मॉडर्न होमियोपैथी

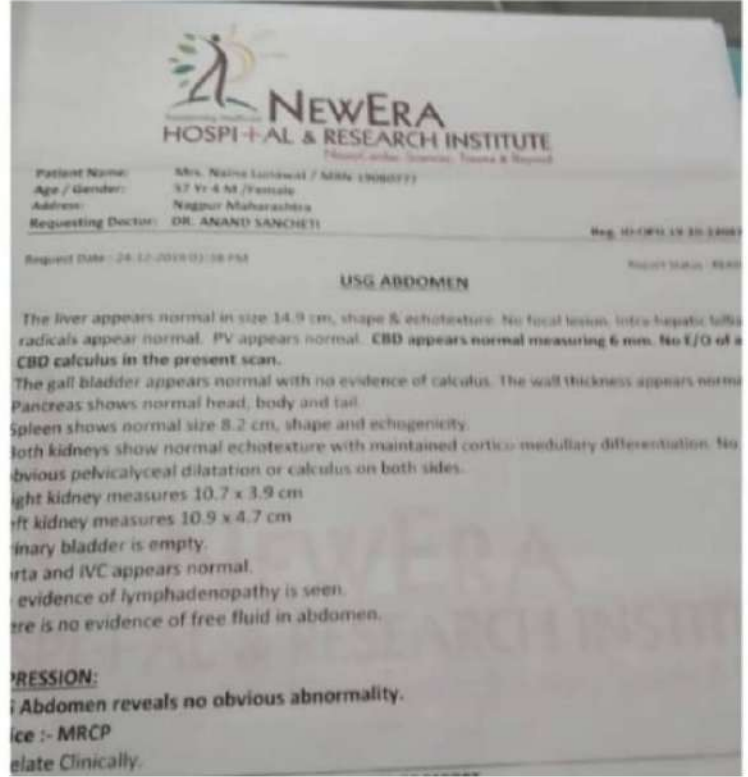
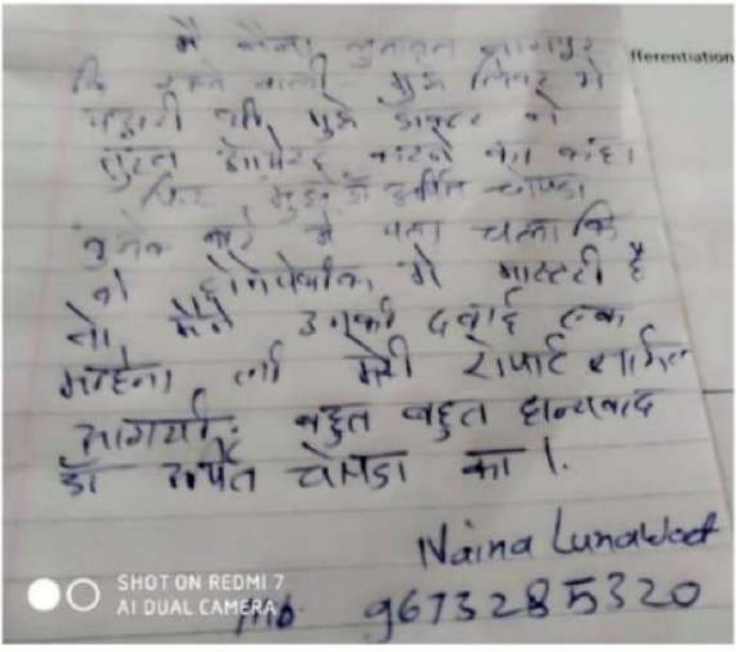
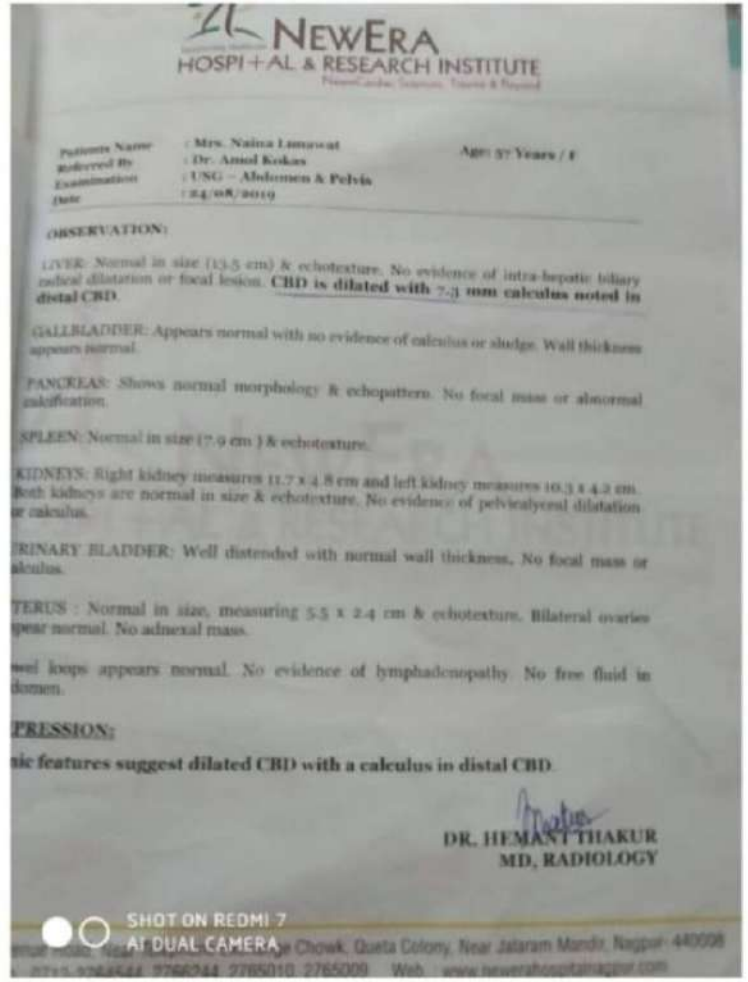
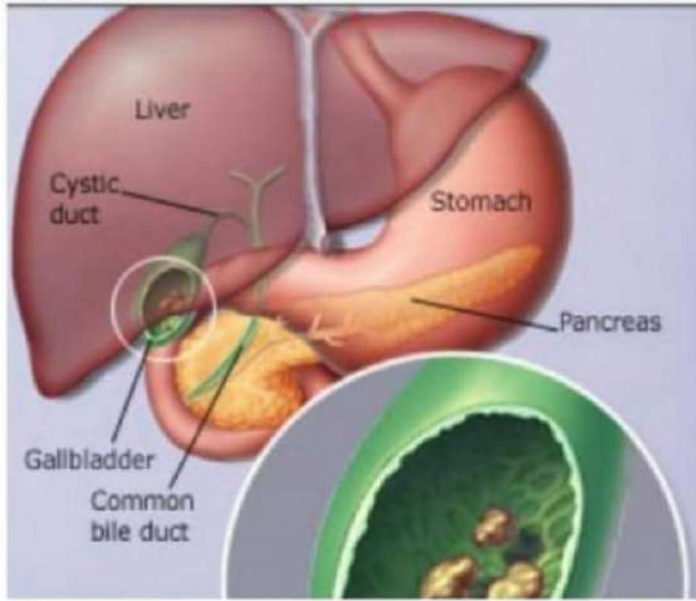
कम्पलिट, परमानेन्ट, ईजी, सेफ, फास्ट एण्ड कॉस्ट इफैक्टिव

102, प्रथम मंजिल, कृष्णा टॉवर, क्योरवेल हॉस्पिटल के सामने, जंजीरवाला चौराहा, न्यू पलासिया, इन्दौर

99075 27914 संपर्क : 0731-4977076, 79999 78894

www.homoeopathy cure.in, www.aarogvahomoeopathyindore.com Email : arpitchopra23@am

Gallstones



Dr. Arpit Chopra (Jain)
M.D. HOMOEOPATHY
 (Critical & Surgical Diseases Specialist)

AAROGYA SUPER SPECIALITY MODERN HOMOEOPATHY

Complete, Easy, Safe, Fast & Cost Effective
 Permanent Modern Homoeopathy Cure With A
 102, First Floor Krishna Tower In front of
 Jankoji Wale Church, INDORE

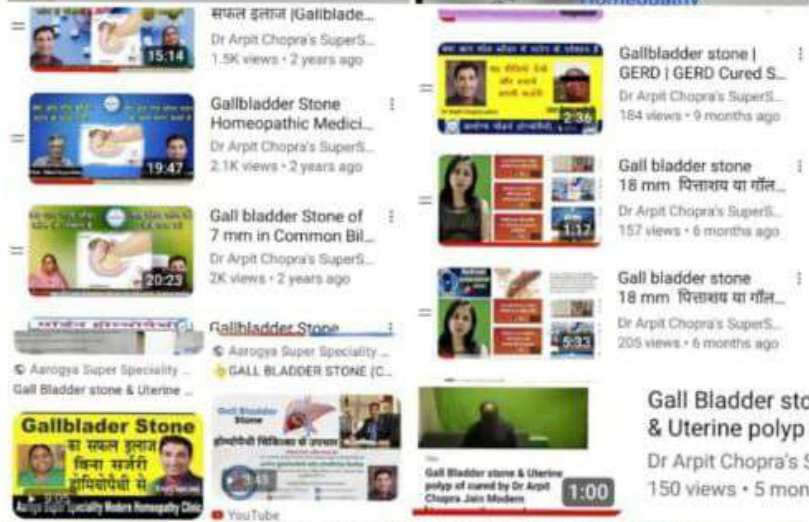
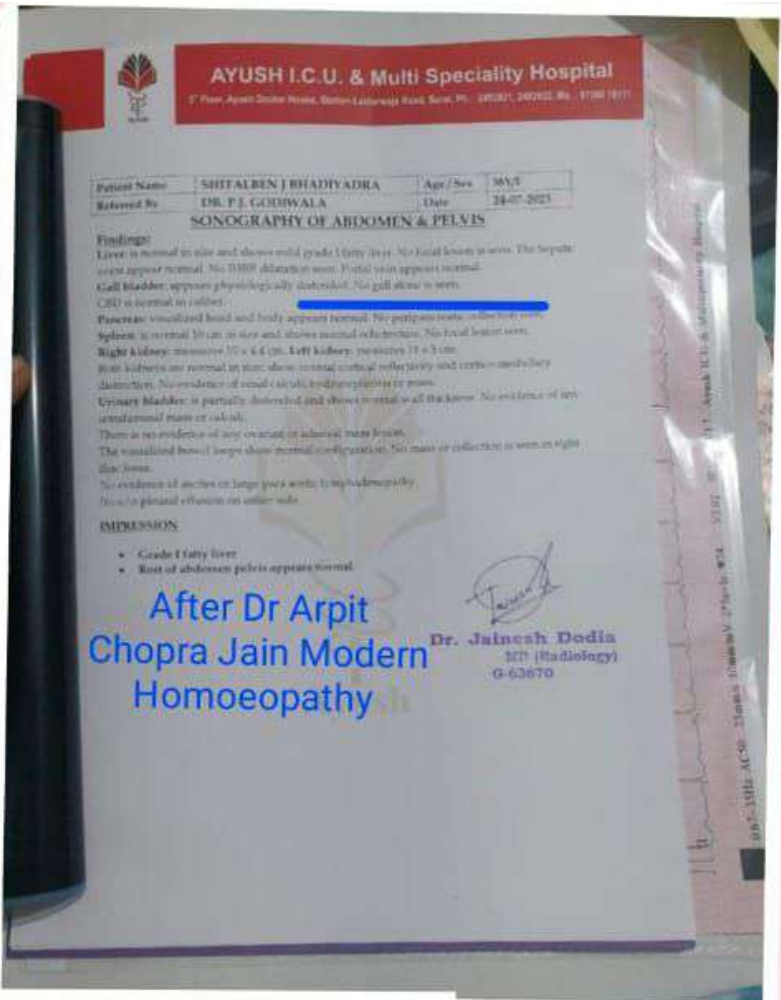
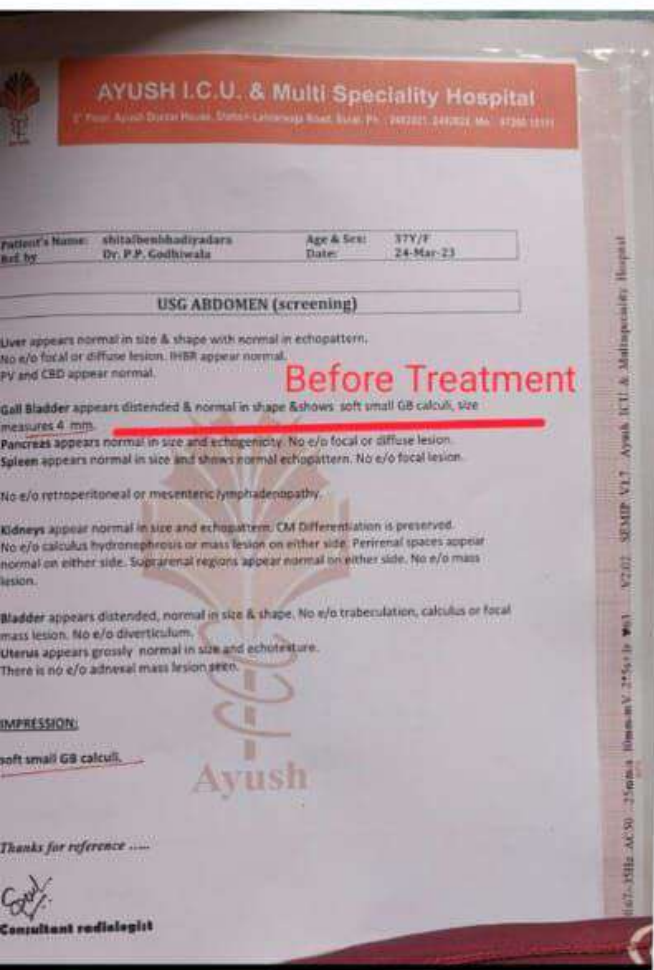
डॉ. अर्पित चौपड़ा (जैन)
 एम. डी. होमियोपैथी
 जटिल, असाध्य एवं
 खतरनाक रोग विशेषज्ञ

आरोग्य सुपर स्पेशलिटी मॉडर्न होमियोपैथी
कम्प्लिट, परमानेंट, ईजी, सेफ, फास्ट एण्ड कॉस्ट इफेक्टिव

102, प्रथम मंजिल, कृष्णा टॉवर, क्योरवेल हॉस्पिटल के सामने, जंजीरवाला चौराहा, न्यू पलासिया, इन्दौर म.प्र.

99075 27914 संपर्क : 0731-4977076, 79999 78894

www.homeopathy cure.in www.aarogyahomeopathyindore.com Email : arpitchopra23@gmail.com

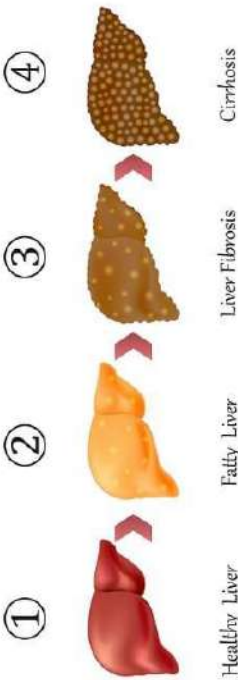


डॉ. अरपित चोपरा (मैन)
एच. डी. होमियोपैथी
फॉरिटर, अरोग्य एवं
सहज योग विशेषज्ञ

आरोग्य सुपर स्पेशलिटी मॉडर्न होमियोपेथी
कम्प्लिट, परमानेंट, ईजी, सेफ, फास्ट एण्ड कॉस्ट इफेक्टिव

102, प्रथम मंजिल, कृष्णा टॉवर, ब्योरथेल हॉस्पिटल के सामने, जंजीरवाला चौराहा, न्यू फ्लोरिसिया, इन्डोर
99075 27914 संपर्क : 0731-4977076, 79999 78894
www.homoeopathycure.in, www.aarogyaahomeopathvindore.com Email : arpitchoora23@gmail.com

Stages of Liver Damage



KRUTI DIAGNOSTIC & MRI CENTRE
 333, Jawahar Marg (Mather Market), Naraingh Bazar, Chhatisra, INDORE - 472002
 Phone: 0731-2542322, 2433500

• MRI • Whole Body Spinal CT Scan • Digital X-Ray • EEG/ECG
 • 4-D Sonography / Echocardiography / Colour Doppler • Digital DPG

Mr. Amit Mishra 40 y M
 Dr. O P Parikh 16-Feb-21

Reg No: _____

Sonography Abdomen

The liver is normal in size measuring 15.2 cms in MCL. The Margins are smooth. It is more echogenic than normal. The parenchymal echotexture is coarse & heterogeneous. The portal vein & CBD are normal. (PV 11mm)

The gall bladder is physiologically distended & non-fibrotic. The walls are normal.

The pancreas & spleen are normal.

Both kidneys are normal in position, size, contour & cortical echotexture is normal. The corticomedullary differentiation is fair. The pelvicalyceal system & ureters are not dilated.

The urinary bladder is normal. Jet of urine seen from both ureteric orifices.

The prostate is normal in size & echotexture. Prostate measures 3.8x2.7cms.

No ascites.

CONCLUSION

Mild echogenic liver with coarse echotexture suggest **Fatty changes ?? early cirrhosis (requires further evaluation)**. Normal gall bladder pancreas & spleen. Structurally normal kidneys bladder & prostate.

Dr. Rajendra Kumar Singh
 MBBS, DNB
 Consultant Radiologist
 Reg. No. 18789

HAEMOGRAM

Patient's Name: Mr. Amit Mishra
 Age / Sex: 40 Yrs / Male
 Referred By: Dr. Parikh O.P., M.D.
 Date: 16-02-21

INVESTIGATION	PATIENT'S VALUE	REFERENCE RANGE
HEMOGLOBIN	9.80 gm/dl	12-14 (M) 14-16 (F)
TOTAL LEUCOCYTE COUNT	4700 /Cu. mm.	6000-12000
DIFFERENTIAL LEUCOCYTE		
Neutrophils	49 %	55-70
Lymphocytes	35 %	20-40
Eosinophils	1 %	1-3
Monocytes	1 %	2-8
Basophils	1 %	0-2
R.S.C. COUNT		
R.C.V.	2.73 ml/l.	3.5-5.5 (M) 4.5-6.2 (F)
M.C.V.	106.23 Cu. μ	78-98
M.C.H.	30.34 Pg	27-32
M.C.H.C.	33.10 g/dl	30-35
PLATELETS	676 /Cu. mm.	1.5-4.5

Dr. K.S. Deoda
 MBBS, DCP

SODANI DIAGNOSTIC CLINIC
 (A Unit of Sodani Hospital & Diagnostic Pvt. Ltd.)
 MD, LG-4, Morya Centre, Opp. Banerji Bldg, 1st, Race Course Road, Indore (M.P.)
 Phone: 0731-4162211, 4161736

Patient's Name: Mr. Amit Mishra
 Age / Sex: 40 Yrs / Male
 Referred By: Dr. Chandra Anand Jain MD (Hons)
 Date: 16-02-2021

Investigation	Result	Unit	Reference Range
HAEMOGRAM (CBC)			
Hemoglobin	11.4	g/dl	13.0-17.0
RBC (Red Blood Cells)	3.87	10 ⁶ /mm ³	4.5-5.5
Hematocrit	32.7	%	40-50
Total Leucocyte Count	5.43	10 ⁹ /mm ³	4.0-10.0
DIFFERENTIAL COUNT			
Neutrophils	60	%	41-77
Lymphocytes	30	%	24-44
Monocytes	08	%	5-10
Eosinophils	02	%	0-4
Basophils	01	%	0-1
MCV (Mean Corpuscular Volume)	99.1	fL	83-101
MCH (Mean Cell Hb)	22.3	pg	27-32
MCHC (Mean Corpuscular HbC)	22.4	g/dl	31.5-34.9
Platelet Count	195	10 ⁹ /mm ³	150-450
RDW CV	14.7	%	11.5-14.5
Mean Platelet Volume (fL)	9.5	fL	7.8-10.4
Mean Platelet Volume (fL)	3.04	10 ⁹ /mm ³	2-7
Absolute Neutrophil Count	1.92	10 ⁹ /mm ³	1-2
Absolute Lymphocyte Count	0.51	10 ⁹ /mm ³	0.2-1.0
Absolute Monocyte Count	0.15	10 ⁹ /mm ³	0.02-0.5
Absolute Eosinophil Count	0.06	10 ⁹ /mm ³	0.02-0.1
Absolute Basophil Count	0.01	10 ⁹ /mm ³	0.00-0.1

Dr. Anand Jain
 MBBS, DNB
 Consultant Radiologist

VINAYAK PATHOLOGY LAB
 COMPLETE PATH SOLUTION
 LABORATORY TEST REPORT E.C.G. DIGITAL X-RAY
 314, Jawahar Marg, T.E.C. Chhatisra, Indore - 472002

Mr. Amit Mishra 40 Yrs / Male
 Referred By: Dr. Parikh O.P., M.D.
 Date: 16-02-2021

BLOOD EXAMINATION

INVESTIGATION	PATIENT'S VALUE	REFERENCE RANGE
HEMOGLOBIN	9.80 g/dl	0.5 - 1.4 g/dl
HEMATOCRIT	32.7 %	0.2 - 1.0 g/dl
MEAN CORPUSCULAR VOLUME (MCV)	99.1 fL	Below 0.2 g/dl
MEAN CELL HEMOGLOBIN (MCH)	22.3 pg	
MEAN CELL HEMOGLOBIN CONCENTRATION (MCHC)	22.4 g/dl	
PLATELET COUNT	195 /mm ³	0 - 40 /mm ³ of serum
RDW CV	14.7 %	0 - 40 /mm ³ of serum
PLATELET COUNT	676 /mm ³	0 - 40 /mm ³ of serum
PLATELET COUNT	676 /mm ³	0 - 40 /mm ³ of serum

Dr. K.S. Deoda
 MBBS, DCP

SODANI DIAGNOSTIC CLINIC
 (A Unit of Sodani Hospital & Diagnostic Pvt. Ltd.)
 MD, LG-4, Morya Centre, Opp. Banerji Bldg, 1st, Race Course Road, Indore (M.P.)
 Phone: 0731-4162211, 4161736

Patient's Name: Mr. Amit Mishra
 Age / Sex: 40 Yrs / Male
 Referred By: Dr. Chandra Anand Jain MD (Hons)
 Date: 16-02-2021

WHOLE ABDOMEN SONOGRAPHY

Suboptimal study due to gaseous abdomen.

Hepatic contour is smooth & span (14.8 cm) is normal. Diffusely increased echotexture. No obvious focal lesion is seen. Intrahepatic biliary radicles are undilated.

Gall bladder is normally distended. Walls are thin. No sludge & calculi seen. No peri GB collection is noted.

Portal vein (11.8 mm) & CBD (4.5 mm) are normal in caliber. Pancreas head and proximal part of body visualized normally. Rest of the pancreas is obscured.

Spleen is normal (10.7 cm). A thick walled cystic lesion measuring 5.0 x 3.3 x 3.0 cm (10.25 cm) seen at splenic hilum, displacing splenic vessels. No significant vascularity seen on color doppler. 7 pancreatic tail ? bowel pathology.

Both kidneys are normal in position & size. Right kidney is 8.0 x 4.3 cm & left is 9.3 x 5.0 cm in size. Cortical echoes are normal. Pelvicalyceal system is undilated.

Both ureters are undilated. No calculi seen at PUJ & UVJ.

Urinary bladder shows normal walls & echoes lumen. No intra luminal lesion or calculi seen.

Prostate is normal in size & measures 3.4 x 3.0 x 3.0 cm (Wt. 15.7 grams).

No significant Ascites. No pleural effusion. No significant bowel wall thickening / dilatation or lymphadenes are noted.

Impression: Gaseous abdomen - Grade 1 fatty changes in liver.
 - A thick walled cystic lesion seen at splenic hilum, displacing splenic vessels. No significant vascularity seen on color doppler - 7 pancreatic tail ? bowel pathology.
 - Normal renal echotexture with undilated collecting system.

Advise: CECT abdomen for further evaluation.

Dr. Pratik Patel
 MD (Radiology) Reg. No. MP 13154
 Centre Address: Morya Centre, 1st, Race Course Road, Indore

EARLY CIRRHOSIS OF LIVER
FATTY LIVER

WEDNESDAY
 MAR 21
 17

मरीज का अल्ट्रासाउंड रिपोर्ट है जो कि फेटी लिवर और प्रारंभिक सिरोसिस को दर्शाता है। लिवर का साइज बड़ा है और एकोटेक्चर कोर्स है। गैलब्लडर में स्लज है।

Dr. Arpit Chopta (Jain)
 M.D. HOMOEPATHY
 Critical & Surgical Diseases Specialist
 9907527914, 9713092737

SODANI DIAGNOSTIC CLINIC
 (A Unit of Sodani Hospital & Diagnostic Pvt. Ltd.)
 MD, LG-4, Morya Centre, Opp. Banerji Bldg, 1st, Race Course Road, Indore (M.P.)
 Phone: 0731-4162211, 4161736

Patient's Name: Mr. Amit Mishra
 Age / Sex: 40 Yrs / Male
 Referred By: Dr. Chandra Anand Jain MD (Hons)
 Date: 16-02-2021

BIOCHEMISTRY

Investigation	Result	Unit	Reference Range
Serum Alanine Transaminase (ALT/SGPT)	158	U/L	25-117
Serum Aspartate Aminotransferase (AST/SGOT)	0.79	mg/dl	0-1.0
Serum Bilirubin (Total)	0.47	mg/dl	0-0.25
Serum Bilirubin (Direct)	0.22	mg/dl	0-0.25
Serum Creatinine	0.77	mg/dl	0.7-1.3
S.G.O.T (AST)	37	U/ml	15-37
S.G.P.T (ALT)	19	U/ml	16-63
Total Cholesterol	1.5	g/dl	0.7-1.2
Serum Albumin	3.4	g/dl	3.2-5.0
A/S Ratio	8.83		2.3-3.5



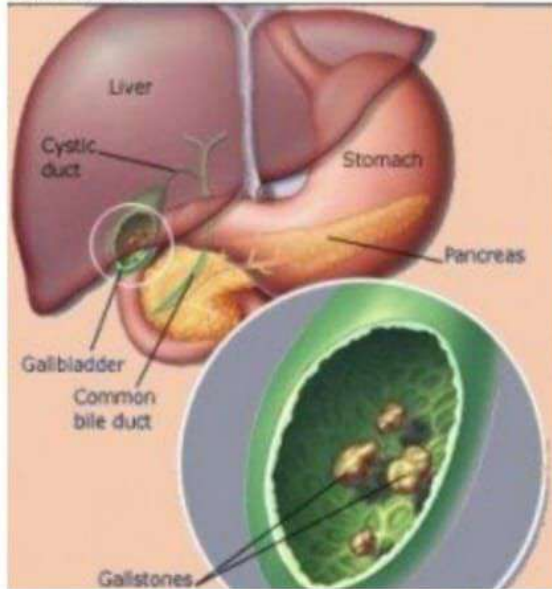
Dr. Anand Jain
 MBBS, DNB
 Consultant Radiologist

आरोग्य सुपर स्पेशलिटी
मॉडर्न होम्योपैथिक क्लिनिक
Dr. Arpit Chopta (Jain)
M.D. HOMOEPATHY
(CRITICAL & SURGICAL DISEASES SPECIALIST)
9907527914, 9713092737

विशेषताएं:

कैंसर, किडनी फैलियर, अस्पताल में गंभीर रूप से भर्ती मरीजों का उपचार, कोमा, ऑटो इम्यून रोग, शल्य चिकित्सा योग्य रोग, हायपोथायराइडिज्म, एलर्जी, बालों का झड़ना, एग्जीमा, सोरायसीस, व्यसन मुक्ति, चर्म रोग, एसीडीटी, मोटापा, ल्यूकोडर्मा, माइग्रेन, गुप्तरोग, पथरी, साइनूसाइटिस, एनिमिया, लकवा, पाईल्स, गठिया, अस्थमा एवं श्वसन संबंधी रोग, होम्योपैथिक प्रतिरोधक एवं होम्योपैथी टिटनेस, नपूंसकता, मुहांसे, वंशानुगत रोग, साइटिका, डिप्रेशन मानसिक रोग, हृदय रोग, मलेरिया मासिक रोग, ब्लड प्रेशर

Gallstones



Dr. Piyush Shrivastava's
(M.D. Radiodiagnosis)

Prakhar Diagnostic Centre, Hospital Road, Vidisha-464001 (M.P.) Phone (07592-405551)

NAME : MR MAHESH KUMAR SHARMA S/O HARCHARAN **AGE / SEX : 52 YRS / M**
REF. BY : DR. ARPIT CHOPRA (BHMS) **DATE : 01/11/2022**

USG WHOLE ABDOMEN & PELVIS

LIVER - Normal in size, smooth in contour and shows simple hepatic cyst in its right lobe with hyperechoic peripheral adhesions. Intrahepatic biliary channels are not dilated. Intra and portal venous channels are normal. Measures 48 cm and Portal Vein measures 18 mm in calibre. It is well-vascularized and shows anechoic lumen. Its wall thickness is 1.8 mm. It is normal in size, shape and echotexture. No dilatation or calcification was seen. Measures 9.4 cm in long axis, normal in size. Shows smooth contour and normal homogeneous parenchymal echotexture on both sides are normal in size, size and echotexture. Right Kidney measures 9.9 X 4.4 cm. Left Kidney measures 9.9 X 4.4 cm. No fluid in peritoneal cavity. Differentiation is well demonstrated. Polyfocal cysts are seen in both sides. No evidence of enlarged intrathoracic nodes.

REMARKS - Liver shows mild diffuse increase in parenchymal echogenicity with normal visualization of intrahepatic vessels. Suggestive of - grade - I fatty liver. A well-defined anechoic cystic lesion noted in right lobe of liver measuring 18 X 12 mm in size containing clear fluid appears as - Simple hepatic cyst. Gall bladder appears chronically contracted with multiple tiny hyperechoic shadows noted arising from gall bladder fossa may suggestive of - gall bladder microlithiasis. Common bile duct, intrahepatic biliary channels & pancreas appear normal. Both kidneys, ureters & urinary bladder appear normal. No evidence of any obvious renal, ureteric or vesical stone. Gerson and bowel loops appear apparently normal. No evidence of enlarged intrathoracic nodes. Pre void urine volume = 720 cc. Post void residual urine volume = 24 cc (Insignificant). Rest of the studied abdominal organs appear normal.

IMPRESSION - Ultrasound study of abdomen shows, Grade - I fatty liver with simple hepatic cyst 18 X 12 mm involving right lobe of liver. Gall bladder appears chronically contracted with multiple tiny hyperechoic shadows noted arising from gall bladder fossa may suggestive of - gall bladder microlithiasis. Pre void urine volume = 720 cc with post void residual urine volume = 24 cc (Insignificant).

Signature Piyush (Radiologist)

(This report is only a professional opinion and not the diagnosis. It should be clinically interpreted by the clinician)

Dr. Piyush Shrivastava's
(M.D. Radiodiagnosis)

Prakhar Diagnostic Centre, Hospital Road, Vidisha-464001 (M.P.) Phone (07592-405551)

NAME : MR MAHESH KUMAR SHARMA S/O HARCHARAN **AGE / SEX : 53 YRS / M**
REF. BY : DR. ARPIT CHOPRA (BHMS) **DATE : 20/05/2023**

USG WHOLE ABDOMEN & PELVIS

LIVER - Normal in size, smooth in contour and shows hyperechoic with simple hepatic cyst in its right lobe with hyperechoic peripheral adhesions. Intrahepatic biliary channels are not dilated. Intra and portal venous channels are normal. Measures 48 cm and Portal Vein measures 18.8 mm in calibre. It is well-vascularized and shows anechoic lumen. Its wall thickness is 1.8 mm. It is normal in size, shape and echotexture. No dilatation or calcification was seen. Measures 8.5 cm in long axis, normal in size. Shows smooth contour and normal homogeneous parenchymal echotexture on both sides are normal in size, size and echotexture. Right Kidney measures 9.7 X 4.4 cm. Left Kidney measures 9.9 X 4.4 cm. No fluid in peritoneal cavity. Differentiation is well demonstrated. Polyfocal cysts are compact on both sides. No evidence of enlarged intrathoracic nodes. Pre void urine volume = 112 cc. Post void residual urine volume = 10 cc (Insignificant). Rest of the studied abdominal organs appear normal.

REMARKS - Liver shows mild diffuse increase in parenchymal echogenicity with normal visualization of intrahepatic vessels. Suggestive of - grade - I fatty liver. A well-defined anechoic cystic lesion noted in right lobe of liver measuring 18.8 X 12.1 mm in size containing clear fluid appears as - Simple hepatic cyst. Gall bladder appears partially contracted, however shows anechoic lumen. Common bile duct, intrahepatic biliary channels & pancreas appear normal. Both kidneys, ureters & urinary bladder appear normal. No evidence of any obvious renal, ureteric or vesical stone. Gerson and bowel loops appear apparently normal. No evidence of enlarged intrathoracic nodes. Prostate weight = 18.5 grams (within normal limits) with no evidence of any obvious median lobe dominance noted. Pre void urine volume = 112 cc with post void residual urine volume = 10 cc (Insignificant). Rest of the studied abdominal organs appear normal.

IMPRESSION - Ultrasound study of abdomen shows, Grade - I fatty liver with simple hepatic cyst measured 18.8 X 12.1 mm in diameter, involving right lobe of liver. Gall bladder appears partially contracted, however shows anechoic lumen. Prostate weight = 18.5 grams (within normal limits) with no evidence of any obvious median lobe dominance noted. Pre void urine volume = 112 cc with post void residual urine volume = 10 cc (Insignificant). No evidence of any gall bladder concretions noted (mentioned in old ultrasound study) is now completely disappear.

Signature Piyush (Radiologist)

(This report is only a professional opinion and not the diagnosis. It should be clinically interpreted by the clinician)

ऑपरेशन या सर्जरी के बगैर पाए अपनी समस्याओं का इलाज

DR. ARPIT CHOPRA JAIN

5:45

आरोग्य

COMPLETELY EASY SAFE, FAST & COST EFFECTIVE

✳ कैंसर ✳ किडनी फेलियर ✳ अस्पताल में गंभीर रूप से मर्ती गरिजों का उपचार ✳ कोमा ✳ शल्य चिकित्सा योग्य रोग ✳ आटो इन्च्यून रोग ✳ जीवनभर दवाई लेने वाले रोगों की रोकथाम एवं 300 प्रकार के असाध्य जटिल रोगों की चिकित्सा

आरोग्य सुपर स्पेशलिटी मॉडर्न होम्योपैथिक क्लीनिक

कम्पलिट ✳ परमानेंट ✳ ईजी ✳ सेफ ✳ फास्ट एण्ड कॉस्ट इफेक्टिव

102, प्रथम मॉडल, कृष्णा टॉवर, नगरोवेल हॉस्पिटल के सामने, जंजीरकला चौका, न्यू पल्लासिब, इन्दौर (म.प्र.)

फोन : 0731-4977076, 97130-92737, 97130-37737, 79999-78894, 99075-27914

www.homoeopathy.cure.in, www.aarogyahomoeopathyindore.com Email: arpit Chopra23@gmail.com



डॉ. अर्पित चोपड़ा (जेन)
एम. डी. होम्योपैथी
जटिल, असहज एवं
शल्य रोग विशेषज्ञ

आरोग्य सुपर स्पेशलिटी माडर्न होम्योपैथिक क्लिनिक



कम्प्लिट * परमानेन्ट * ईजी * सेफ * फास्ट एण्ड कॉस्ट इफैक्टिव

* कैंसर * किडनी फेलियर * अस्पताल में गंभीर रूप से भर्ती मरिजों का उपचार * कोमा *
* शल्य चिकित्सा योग्य रोग * आँटो इम्यून रोग * जीवनभर दवाई लेने वाले रोगों की रोकथाम
एवं 300 प्रकार के असाध्य जटिल रोगों की चिकित्सा ।

102, 104, प्रथम मंजिल, कृष्णा टॉवर, क्योरवेल हॉस्पिटल के सामने, जंजीरवाला चौराहा, न्यू पलासिया, इन्दौर (म.प्र.)

फोन : 0731-4977076, मो. : 97130-92737, 97130-37737, 79999-78894, 99075-27914

www.homoeopathyin.in, www.aarogyahomoeopathyindore.com Email : arpitchopra23@gmail.com

Jain Diagnostic
• X-RAY • ECG • SONOGRAPHY
Opp. Govt. Hospital, Bohra Masjid Road, Guna (M.P.) 473001 Ph.: 07542-222622

Reg. No. : 183
Patient Name : Mrs. Anjali W/O- Ashish Gupta, 34 y/F
Ref. by : Self
Date : 07/05/2020.

U. S. G. WHOLE ABDOMEN.

Liver is normal in size, shape and echotexture is normal through out the liver. Veins and intrahepatic biliary radicals are not dilated. No SOL is noted.

GB is contracted and reveals multiple small calculi of size varying between 2 - 3 mm each.

CBD and portal vein are normal in course and caliber.

Pancreas is normal in size and echotexture.

Spleen is normal in size and echotexture.

Both kidneys are normal in size, shape and echotexture. Bilateral corticomedullary differentiation is maintained. Bilateral PCS not dilated.

Urinary bladder is partially distended with echofree contents. Wall thickness within normal limits.

Uterus is anteverted, mild bulky in size and echotexture is normal. Its measuring about 10.5 x 3.7 x 5.0 cm.

A small hypoechoic lesion of size about 12.3 x 10.5 mm seen in anterior wall of uterus.

Endometrial echoes is intact, measuring about 4.0 mm.

Both ovaries are normal in size, shape and echotexture. Bilateral adnexa appears normal.

No free fluid noted in cul-de-sac and peritoneal cavity.

VC and abdominal aorta are normal. No evidence of significant lymphadenitis seen.

No thick walled bowel loops seen. Bilateral iliac fosse are clear.

IMPRESSION :- Sonography of abdomen reveals :-
:- **Cholelithiasis with contracted gall bladder.**
:- **Mild bulky uterus with a small anterior wall uterine fibroid.**
Recommended clinical, lab parameters correlation and evaluate further out other possibilities.

This is my professional opinion, to the best of my knowledge and clinically efficiency and the final diagnosis. May be reviewed, discussed if doubt remains.

Advance
C.T. SCAN & DIAGNOSTIC CENTRE PVT. LTD.
विलास अस्पताल के सामने, भगतसिंह चौक, गुना - 473001 (म.प्र.) फोन : 07542-222622 मो. : 769199499

No. : 13868
Patient Name : Anjali Gupta.
35 Y/F
Ref. by : Self.
Date : 07-Nov-20 12:46 PM

USG - WHOLE ABDOMEN.

Liver is normal outline and echoes. Intrahepatic biliary tree and portal system normal. CBD and portal vein are normal in diameter at porta hepatis.

Gall bladder is partially distended and shows a tiny calculus in lumen.

Urinary bladder is normal in size, shape and echotexture. Uterus is normal in shape and echotexture.

Both kidneys are normal in size, shape, echotexture and corticomedullary differentiation. Bilateral sinus echoes are intact. Collecting system of both kidneys are normal.

Adrenal glands are normal in course, caliber and lumen. No lymph nodes seen in peritoneal cavity. No lymph nodes seen.

Urinary bladder is partially distended with normal wall thickness and anechoic content.

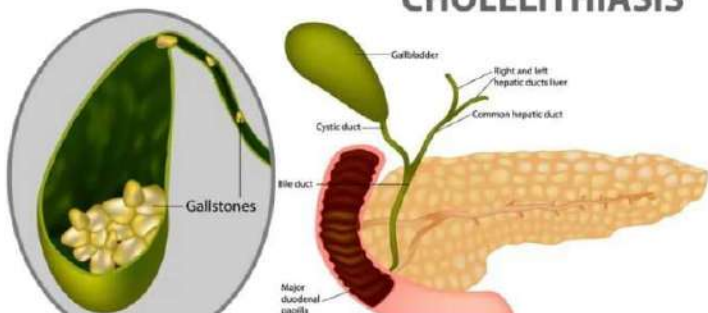
Uterus is anteverted and normal in size and shows well defined hypoechoic lesion measuring 1.3 x 1.1 cm. endometrium is intact.

Presence of cystic lesion of size 4.2 x 2.9 cm with internal echoes and septations. Ovary appears normal.

No free fluid seen in cul-de-sac.

IMPRESSION:- Anterior wall uterine fibroid.

CHOLELITHIASIS



Gallstones

Also called: cholelithiasis

OVERVIEW SYMPTOMS TREATMENTS NEW

समर्पण
Imaging & Diagnostics

12-20, Ground Floor, Yashwant Plaza,
Opp. Railway Station, Indore (M.P.)
0731-4068123, 4967633, 88899-33684
samarpanimagingolutions@gmail.com
www.samarpanimaging.com

PATIENT NAME:- SANDEEP SHARMA	Date:- 20/10/2019
REF. BY DR. :- ARPIT CHOPRA	Age/ Sex:- 33y/M

WHOLE ABDOMEN SONOGRAPHY

Hepatic contour is smooth & span (17.02 cm) is enlarged. Parenchymal echotexture is raised. No focal lesions seen. Intrahepatic biliary radicles are undilated. Gall bladder is normally distended. Walls are thin. No sludge or calculus is seen. CBD & Portal vein are normal in caliber. Visualized part of Pancreas is normal in shape & size. Parenchymal echoes are normal. Pancreatic duct is undilated. Spleen is normal 10.98 cm. No focal lesion seen. Both kidneys are normal in position & size. Renal contour is smooth. Cortical echoes are normal. Right Pelvicalyceal system is undilated. Right kidney is 9.71 x 4.97 cm and Left kidney is 9.90 x 5.72 cm in size. Mildly dilated left renal pelvis, post operative changes (history of renal stone surgery). Urinary bladder wall appear thickened. Pre-void urine = 302 ml (approx), post-void residual urine = 27 ml (approx). Prostate is normal, Weight is 12.4 grams. Seminal vesicles are normal. No significant retroperitoneal lymphadenopathy seen. No free fluid seen in peritoneal cavity. The dependent pleural recess are normal.

IMPRESSION:- HEPATOMEGALY WITH FATTY LIVER GRADE III. URINARY BLADDER WALL THICKENED.

Clinical correlation.

AMIT KUMAR TIWARI,
MD, RADIOLOGIST
REG. NO. MP-11308

ISO 9001:2008, Reg.No. RQ918738

UHD No. 143132 OPD No. 15660 Month No. @/0

Patient's Name **MR. SANDEEP SHARMA**

Age & Sex 32 Y/Male Report Date: 15

Consultant **DR. ARPIT CHOPDA (JAIN)**

Referred by Dr. Arpit Chopda (Jain) Lab No.

WHOLE ABDOMEN SONOGRAPHY:

No plural effusion is seen in costo-phrenic recesses. Liver is normal in size and contours. Hepatic parenchyma is homogenous, no focal lesion. Intra hepatic biliary radicles are undilated. Gall bladder is normal thin walled and is nonlethiasic. Bile ducts and portal vein are undilated. Pancreas and spleen are normal in size and echotexture. No ascites, no apparent abdominal lymphadenopathy. No apparent thick walled or dilated bowel loop is seen. Both kidneys are normal in size, shape and position. Renal contours are smooth, parenchymal echogenicity is normal. Right renal pelvi-calyceal systems and right ureter are undilated. Left renal pelvi-calyceal systems are mildly dilated. Left ureter is undilated. Urinary bladder is normal thin walled and is nonlethiasic. Prostate is normal in size and echotexture. No significant amount of post void residual urine is noted in U.B.

IMPRESSION :
Mild left hydronephrosis, could be residual after removing of left renal pelvis or ureteric calculus.

Dr. R. S. SENGAR, MD,
CONSULTANT RADIOLOGIST

sanjuan corporati
Primary Health

Also called: hepatic steatosis

OVERVIEW SYMPTOMS TREATMENTS

An increased build-up of fat in the liver.

Major risk factors include obesity and type 2 diabetes, though it's also associated with excessive alcohol consumption.

Very common

More than 10 million cases per year (India)

Treatment can help, but this condition can't be cured

Requires a medical diagnosis

Lab tests or imaging always required

Chronic: can last for years or be lifelong

Website: www.aarogya.com | 9907527914 | 9713092737

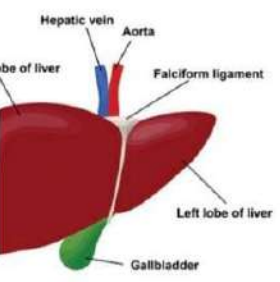
Complete, Easy, Safe, Fast & Cost-effective Cure With Homoeopathy

Dr. Arpit Chopra (Jain)

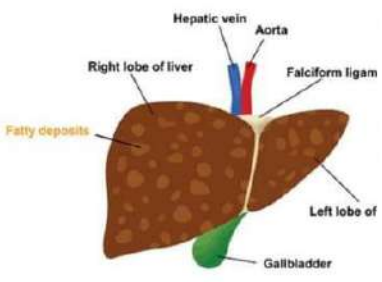
Handwritten notes: Fatty Liver, 19/10/19, Aarogya (Jain)

HEALTHY AND FATTY LIVER

NORMAL LIVER



FATTY LIVER DISEASE



9907527914, 9713092737

आरोग्य

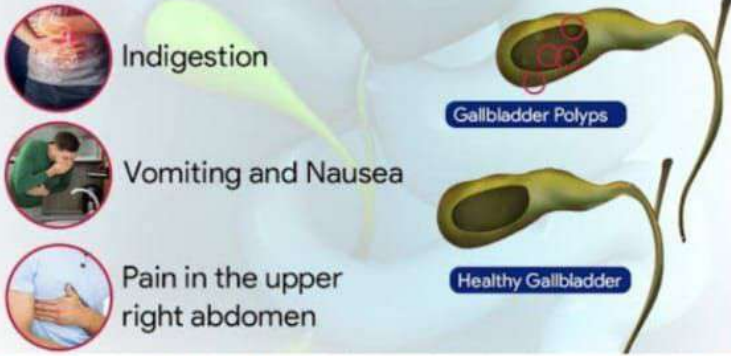
COMPLETE, EASY, SAFE, FAST & COST EFFECTIVE

Dr. Arpit Chopra (Jain)
M.D. HOMOEOPATHY
(Critical & Surgical Diseases Specialist)

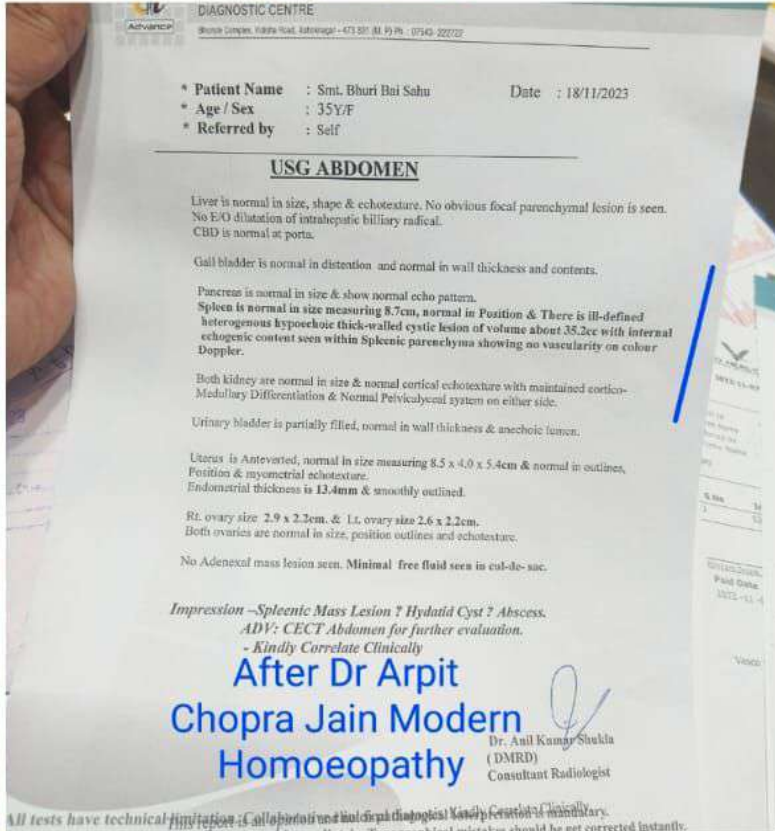
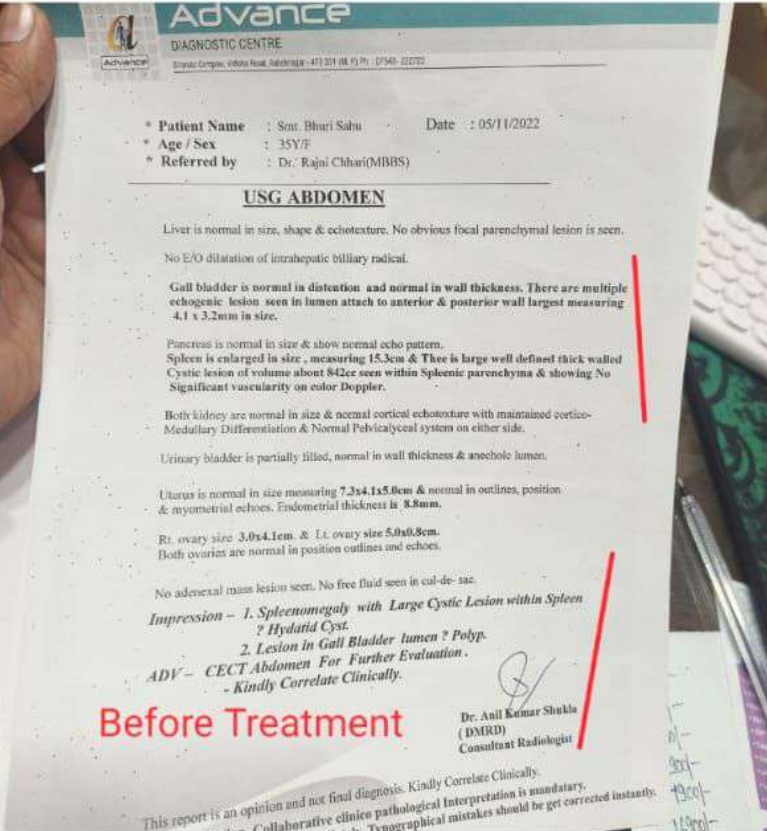
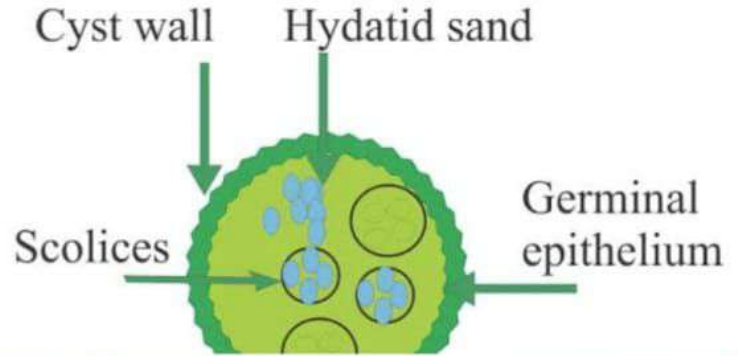
AAROGYA SUPER SPECIALITY MODERN HOMOEOPATHY

Complete, Easy, Safe, Fast & Costeffective
Permanent Modern Homoeopathy Cure With Advance Lifest
102, First Floor Krishna Tower in front of Curewell Hospi

Gallbladder Polyps



Hydatid cyst



किसी प्रकार की सर्जरी
या ऑपरेशन से बचाएगा
ये वीडियो

Splenic Hydatid Cyst



डॉ. अर्पित चौपड़ा (जेन)
एम. डी. होम्योपैथी
जटिल, असाध्य एवं
शल्य रोग विशेषज्ञ

कैंसर, किडनी फेलियर, अस्पताल में गंभीर रूप से
भर्ती मरिजों का उपचार, कोमा, शल्य चिकित्सा योग्य रोग,
ऑटो इम्यून रोग, जीवनभर दवाई लेने वाले रोगों की रोकथाम एवं
300 प्रकार के असाध्य जटिल रोगों की चिकित्सा ।



आरोग्य सुपर स्पेशलिटी माईन होमियोपैथी
कम्पलिट, परमानेन्ट, ईजी, सेफ, फास्ट एण्ड कॉस्ट इफैक्टिव

102, प्रथम मंजिल, कृष्णा टॉवर, क्योरवेल हॉस्पिटल के सामने, जंजीरवाला चौराहा, न्यू पलासिया, इन्दौर म.प्र.

99075 27914 संपर्क : 0731-4977076, 79999 78894

पित्त की पथरी का किसा आपरेसन

अब नहीं करवाना पड़ेगा ऑपरेशन का कोई सल्लाह

ऑपरेशन या सर्जरी के बिना आपनी समस्याओं का इलाज

किसी प्रकार की सर्जरी या ऑपरेशन से बचावप्राप्त हो सकिये

किसी भी प्रकार की सर्जरी से पहले से ही किसी तकलीफ से बचें

GALL BLADDER STONE CHOLELITHIASIS

5:46

5:45

5:53

5:45

कैसर, किडनी फेलियर, अस्पताल में नौबत लग ते भर्ती करिने का उपचार, कोमा, श्वस विक्रिया बाध होना, 300 प्रकार के अनाथ नरिण रोगों की चिकित्सा।

आरोग्य सुपर स्पेशलिटी मॉडर्न होमियोपैथी

कम्प्यूटर, परामर्श, ई-टी, कैम, फास एच डॉक्टर इतिहास

1102, कानन सिटी, सुभा शीटर, अयोधिया रोड/मिने के समने, नोवोसोस रोड, नू नू नोवोसोस, इन्फर म.क.

098775 2914 मोबा 011-487709, 73990 73990

www.aarogya.com, www.aarogya.com/online-consultation, Email: aarogya@aarogya.com

Gallstones

Also called cholelithiasis

Overview Symptoms Treatments

A hardened deposit within the fluid in the gallbladder, a small organ under the liver.

Gallstones are hardened deposits of digestive fluid

Very common

Gallstones are hardened deposits of digestive fluid that can form in your gallbladder. Your gallbladder is a small, pear-shaped organ on the right side of your abdomen, just beneath your liver. The gallbladder holds a digestive fluid called bile that is released into your small intestine.

Gallstones

After 1 month modern homoeopathy is free

Search gallbladder-stone - Aarogya Super Speciality... Visit

GALL BLADDER STONE 9.1 MM (CHOLELITHIASIS... Visit

Gallbladder with stones

A hardened deposit within the fluid in the gallbladder, a small organ under the liver.

Very common

More than 10 million cases per year (United)

Formed by a medical professional

Requires a medical diagnosis

Lets tests or imaging always required

Chronic can last for years or be lifelong

Gall Bladder Stones

Gall Bladder Polyp

After 1 month modern homoeopathy is free

Gallstones

After Dr Arpit Chopra Jain Modern Homoeopathy

ऑपरेशन या सर्जरी के बिना आपनी समस्याओं का इलाज

5:45

Before Treatment

After Dr Arpit Chopra Jain Modern Homoeopathy

आरोग्य सुपर स्पेशलिटी मॉडर्न होमियोपैथी

GALL BLADDER STONE Homoeopathy saved surgery

Gall bladder stone Cholilithiasis पित्ताशय की... Visit

Gall Bladder stone & Uterine polyp of cured by...

Images may be subject to copyright. Learn More

Share Save

Dr. RAI HOSPITAL RADIOLOGY DEPARTMENT

PATIENT NAME SHABANA ANAR

AGE/SEX 41 YRS/F

DATE 09/MAY/2023

WARD QPD

ULTRASOUND OF ABDOMEN AND PELVIS

Liver appears normal in size, shape and echotexture. No focal lesion is seen. No intraperitoneal fluid is seen. The portal vein and CBD appear normal.

Gall bladder is well distended with normal wall thickness (2.5 mm). There are two calculi of 25 mm and 17 mm seen in the gall bladder.

Spleen appears normal in size and echotexture. No focal lesion is seen.

Right kidney measures 9.9 x 3.5 cm. Left kidney measures 9.1 x 4.7 cm. Both kidneys appear normal in size, shape & echotexture. They show good cortico-medullary differentiation. There is hydronephrosis, hydroureter or calculus seen on either side.

The urinary bladder is minimally distended.

Visualized uterus is normal in size and echotexture. Endometrium is central and it measures 13 mm. No focal lesion is seen. Both adnexal regions are clear.

Visualized bowel loops are non-dilated and show normal peristalsis. Excessive bowel gases in the abdomen.

There is no ascites seen.

IMPRESSION:

- Cholelithiasis. No signs of cholecystitis in present scan.
- Excessive bowel gases in the abdomen.

DR. NIMISH GOYAL CONSULTANT RADIOLOGIST

Before Treatment

Dr. RAI HOSPITAL RADIOLOGY DEPARTMENT

PATIENT NAME SHABANA ANAR

AGE/SEX 40 YRS/F

DATE 03/NOV/2023

WARD QPD

ULTRASOUND OF ABDOMEN AND PELVIS

Liver appears normal in size and shows mild fatty changes. No focal lesion is seen. No intraperitoneal fluid is seen.

Gall bladder is completely devoid of bile. There is a calcified foci of size 20 mm giving very prominent acoustic shadowing in gall bladder fossa.

Distended appears normal in size and echotexture. No focal lesion is seen.

Both kidneys appear normal in size and echotexture. They show good cortico-medullary differentiation. There is no hydronephrosis, hydroureter or calculus seen on either side.

The urinary bladder is well distended. Wall thickness is normal. No mass lesion or calculus is seen.

Uterus is normal in size and echotexture. Endometrium is central and no focal lesion is seen. Both adnexal are normal. No adnexal pathology is seen.

Visualized bowel loops are non-dilated and show normal peristalsis.

There is no ascites seen.

IMPRESSION:

- Liver showing mild fatty changes.
- Cholelithiasis with chronic cholecystitis.

DR. NIMISH GOYAL CONSULTANT RADIOLOGIST

During Dr Arpit Chopra Jain Modern Homoeopathy

J.P. DIAGNOSTIC
DR. JAYPAL SINGH
SPECIALIST
SONOLOGY & COLOR DOPPLER CLINIC
ISO 9001:2015 CERTIFIED DIAGNOSTIC

Pt. Name: SMT. SUKHDIYA MEENA Age/Sex: 40 Years / Female
Ref. By: DR. ARPIT CHOPRA JAIN, M.B.B.S., M.D. Date: 25/Sept/2023

WHOLE ABDOMEN & PELVIS SONOGRAPHY REPORT

C/o Pain in epigastric region. Before Treatment

Hepatic contour is smooth & span (15.2 cm) is enlarged. Parenchymal echotexture is fine. No focal lesion is seen. Intrahepatic biliary radicles are unaltered.

Gall bladder is partially distended. Walls are thin. GB lumen shows multiple 2.4 to 3 in number 1.0 to 1.5 mm in size measuring between 4.6 mm to 6.7 mm. No post GB contraction is noted. Peral vein & CBD are normal in caliber.

Pancreas is normal in shape & size. Parenchymal echotexture is normal. Pancreatic duct is unaltered. Pancreatic surface is smooth. No peripancreatic fluid or pancreatic calcification is noted.

Spleen is normal in size measure 10.8 cm in long axis. No focal lesion seen.

Both kidneys are normal in position & size. Right kidney is 9.3 x 4.2 cm & left is 9.2 x 4.9 cm in size. Renal contour is smooth. Cortical echotexture is normal. Pelvicalyceal system is unaltered.

Both ureters are unaltered. No calculi seen at PUJ & UVI.

Urinary bladder shows normal wall & anechoic lumen. No extra luminal lesion or calculi seen.

Uterus & Ovaries are postmenopausal. Uterus measure 3.4 x 2.8 x 2.8 cm.

Bladder adjacent region clear. No cyst seen.

No free fluid seen in sub-diaphragmatic, suprapubic or pelvic region.

No significant bowel wall thickening / dilatation or lymphadenopathy noted.

IMPRESSION:-
1- Multiple 1.0 to 1.5 in number / Calculolithiasis (measuring between 4.6 mm to 6.7 mm)
2- Mild hepatomegaly with grade II fatty liver changes.

Advice:- Upper GI Endoscopy / Clinico-pathological correlation / follow-up suggested.

Signature: **Radhakrishna**

THANKS FOR REFERENCE

Report is only a professional opinion and not the diagnosis. It should be clinically interpreted by the clinician.
Bham Hospital, Bahadur Nagar, Gurgaon, Haryana, India. Phone: 9910128111, 9869673008

आरोग्य सुपर स्पेशलिटी माडर्न होमियोपैथी

आरोग्य सुपर स्पेशलिटी माडर्न होमियोपैथी
आरोग्य सुपर स्पेशलिटी माडर्न होमियोपैथी
आरोग्य सुपर स्पेशलिटी माडर्न होमियोपैथी

आरोग्य सुपर स्पेशलिटी माडर्न होमियोपैथी
आरोग्य सुपर स्पेशलिटी माडर्न होमियोपैथी
आरोग्य सुपर स्पेशलिटी माडर्न होमियोपैथी

आरोग्य सुपर स्पेशलिटी माडर्न होमियोपैथी

आरोग्य सुपर स्पेशलिटी माडर्न होमियोपैथी
आरोग्य सुपर स्पेशलिटी माडर्न होमियोपैथी
आरोग्य सुपर स्पेशलिटी माडर्न होमियोपैथी

GALL BLADDER STONE 9.1 MM (CHOLELITHIASIS...)

Visit

Search gallbladder-stone - Aarogya Super Speciality...

Visit

Gall Bladder Stone
Very common
Causes
Symptoms
Diagnosis
Treatment

GALL BLADDER STONE
Homoeopathy saved surgery

Visit

Gall bladder stone
Cholithiasis पित्ताशय की...

Visit

J.P. DIAGNOSTIC
DR. JAYPAL SINGH
SPECIALIST
SONOLOGY & COLOR DOPPLER CLINIC
ISO 9001:2015 CERTIFIED DIAGNOSTIC

Pt. Name: SMT. SUKHDIYA BAI Age/Sex: 40 Years / Female
Ref. By: DR. ARPIT CHOPRA (JAIN), M.B.B.S., M.D. Date: 30/Dec/2023

WHOLE ABDOMEN & PELVIS SONOGRAPHY REPORT

C/o Pain in epigastric region.

Hepatic contour is smooth & span (15.4 cm) is enlarged. Parenchymal echotexture is fine. No focal lesion is seen. Intrahepatic biliary radicles are unaltered.

Gall bladder is partially distended. Walls are thin. GB lumen is normal in caliber. No post GB contraction is noted. Peral vein & CBD are normal in caliber.

Pancreas is normal in shape & size. Parenchymal echotexture is normal. Pancreatic duct is unaltered. Pancreatic surface is smooth. No peripancreatic fluid or pancreatic calcification is noted.

Spleen is normal in size measure 10.8 cm in long axis. No focal lesion seen.

Both kidneys are normal in position & size. Right kidney is 8.8 x 4.9 cm & left is 8.5 x 4.4 cm in size. Renal contour is smooth. Cortical echotexture is normal. Pelvicalyceal system is unaltered.

Both ureters are unaltered. No calculi seen at PUJ & UVI.

Urinary bladder is partially filled.

Uterus & Ovaries are postmenopausal.

Bladder adjacent region clear. No cyst seen.

No free fluid seen in sub-diaphragmatic, suprapubic or pelvic region.

No significant bowel wall thickening / dilatation or lymphadenopathy noted.

IMPRESSION:-
1- Gallstones
2- Multiple 1.2 to 1.5 in number / Subcutaneous lipomas (measuring between 10.3 mm to 16.8 mm in long axis) or clinical palpable site.
3- Mild hepatomegaly with Grade II fatty liver changes.

Advice:- Upper GI Endoscopy / Clinico-pathological correlation / follow-up suggested.

Signature: **Radhakrishna**

After Dr Arpit Chopra Jain Modern Homoeopathy

Report is only a professional opinion and not the diagnosis. It should be clinically interpreted by the clinician.
Bham Hospital, Bahadur Nagar, Gurgaon, Haryana, India. Phone: 9910128111, 9869673008

Gall Bladder stone & Uterine polyp of cured by...

Visit

Images may be subject to copyright. Learn More

Share Save

Dr. RAJ HOSPITAL RADIOLOGY DEPARTMENT

EXAMINATION OF ABDOMEN (ULTRASOUND)

ULTRASOUND OF ABDOMEN (ULTRASOUND)

ULTRASOUND OF ABDOMEN (ULTRASOUND)

Dr. RAJ HOSPITAL RADIOLOGY DEPARTMENT

EXAMINATION OF ABDOMEN (ULTRASOUND)

ULTRASOUND OF ABDOMEN (ULTRASOUND)

ULTRASOUND OF ABDOMEN (ULTRASOUND)

Gall bladder stone Cholithiasis पित्ताशय की पथरी cured & responded by Dr Arpit Chopra Jain Modern Hom... Read more

किसी भी प्रकार की सर्जरी से पहले ये वीडियो जरूर देखे

5:07

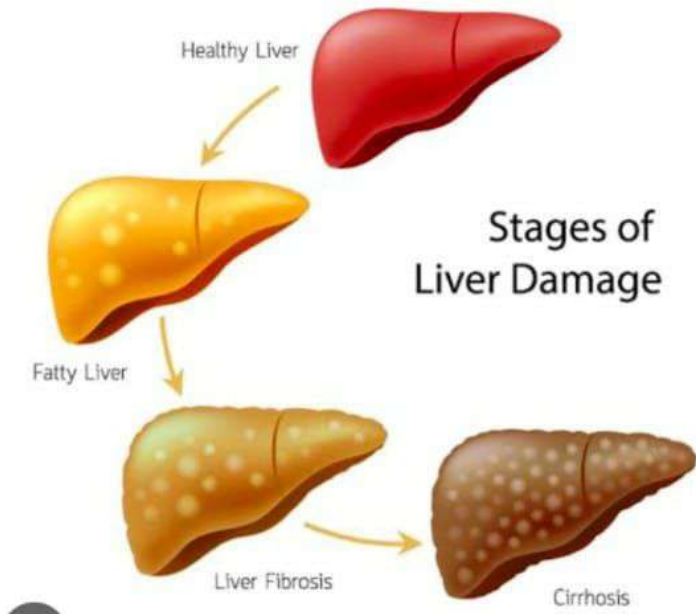
DR. ARPIT CHOPRA JAIN

कैसर, किडनी फेलियर, अस्पताल में गंभीर रूप से भर्ती मरिजों का उपचार, कोमा, शल्य चिकित्सा योग्य रोग, ऑटो इम्यून रोग, जीवनभर दवाई लेने वाले रोगों की रोकथाम एवं 300 प्रकार के असाध्य जटिल रोगों की चिकित्सा।

आरोग्य सुपर स्पेशलिटी माडर्न होमियोपैथी

कम्पलिट, परमानेंट, ईजी, सेफ, फास्ट एण्ड कॉस्ट इफैक्टिव

102, प्रथम मंजिल, कृष्णा टॉवर, क्योरवेल हॉस्पिटल के सामने, जंजीरवाला चौराहा, न्यू पलासिया, इन्दौर म.प्र.
99075 27914 संपर्क : 0731-4977076, 79999 78894
www.homoeopathcure.in, www.aarogvahomoeopathvindore.com Email : arpit Chopra23@gmail.com



About 50–75% of AIH patients are ANA-positive (with or without anti-SMA) (24). ANA can also be detected in healthy persons or patients with other liver diseases such as fatty liver disease, drug-induced liver injury (DILI) disease, or viral hepatitis. 27 Mar 2019

CHRONIC LIVER DISEASE: MAR 23

FIBRO SCAN RESULT: - 38.4% (28/10/23)

GRADE A ESOPHAGITIS.

DM II: 2 years on Rx. HbA1c = 5.7% Sept 23

On Allopathic medicines

Splenomegaly = 127mm 29/10/23

ANA (+) (31/10/23)

H/O Cholecystectomy in 2015

Although a number of autoimmune conditions may involve the liver, the three most common autoimmune liver diseases are autoimmune hepatitis, primary biliary cholangitis and primary sclerosing cholangitis.

Mr. NIRBHAY MISHRA
172987084
DR RAMESH GARG
4/3/2023 10:06:00AM
P
FPSC ROHINI SECTOR-24
Plot No- 23, Pocket-14, Sector-24, Rohini
Ph.011-27944045, 9313988296
Delhi-110085

Age : 43 Years
Gender : Male
Reported : 6/3/2023 11:31:15AM
Report Status : Final
Processed at : LPL-NATIONAL REFERENCE LAB
National Reference Laboratory, Block E,
Sector 18, Rohini, New Delhi-110085

Test Name	Results	Units	Bio. Ref. Interval
ANTI NUCLEAR ANTIBODY / FACTOR (ANA/ANF), SERUM (IA)	118.78	Units	<20.00

Interpretation

RESULT IN UNITS	REMARKS
<20	Negative
20-60	Moderate positive
>60	Strong positive

Before Treatment

Healthians

22% State-of-the-art with across India

100+ million tests reported

2000+ Specialists & pathologists

CAP Accredited

Patient Name : Ca Nirbhay
Age/Gender : 44Y 0M 0D /Male
Order Id : 9850557245
Referred By : Self
Customer Since : 06/Jan/2024
Sample Type : SERUM

Barcode : E0308000

Sample Collected On : 06/Jan/2024 07:33AM
Sample Received On : 06/Jan/2024 10:26AM
Report Generated On : 06/Jan/2024 04:19PM
Sample Temperature : Maintained
Report Status : Final Report

DEPARTMENT OF AUTOIMMUNITY

Test Name	Value	Unit	Bio. Ref Interval
ANA by IFA (Anti Nuclear Antibody) screening End point titre, Serum	NEGATIVE		Negative

ANA Hep 20-10
Method: Indirect Immunofluorescence

Interpretation of The Results

After Dr Arpit Chopra Jain Modern Homoeopathy

कैंसर, किडनी फेलियर, अस्पताल में गंभीर रूप से भर्ती मरिजों का उपचार, कोमा, शल्य चिकित्सा योग्य रोग, ऑटो इम्यून रोग, जीवनभर दवाई लेने वाले रोगों की रोकथाम एवं 300 प्रकार के असाध्य जटिल रोगों की चिकित्सा।

डॉ. अर्पित चौपड़ा (जैन)
एम. डी. होम्योपैथी
जटिल, असाध्य एवं शल्य रोग विशेषज्ञ

आरोग्य सुपर स्पेशलिटी माईन होमियोपैथी
कम्पलिट, परमानेंट, ईजी, सेफ, फास्ट एण्ड कॉस्ट इफैक्टिव

102, प्रथम मंजिल, कृष्णा टॉवर, क्योरवेल हॉस्पिटल के सामने, जंजीरवाला चौराहा, न्यू पलासिया, इन्दौर म.प्र.
99075 27914 संपर्क : 0731-4977076, 79999 78894

COMPLETE CURE. EASY. SAFE. FAST & COST-EFFECTIVE

MODERN
आरोग्य
HOMOEOPATHY



AMRITA INSTITUTE OF MEDICAL SCIENCES & RESEARCH CENTRE
PAN NO: AAATM24038, Appointment call: 01292851234
Main Address: Ambabandari Marg, Sector 28, Faridabad, Haryana 121002

MRD No: 17430 Gender: Male Age: 57Y 3M 22D
Name: Mr. BHARAT CHAURASIA Visit Type: OP Visit Code: GP001
Residence: 1, Unnao Road, White Ashiana

Before Treatment

ULTRASOUND OF ABDOMEN

Date of procedure: 02/12/2023

LIVER:
Normal in size (15.8 cm) and echotexture. No focal lesions seen. BIRB not dilated.

GB:
Distended and shows a calculus appearance. It was impinged to neck region and shows with a 9 mm stone. Its thickness is normal. No pericholecystic fluid seen.

CBD/PV:
CBD appears normal. Portal vein shows normal caliber.

SPLEEN:
Normal size, shape and echotexture. No focal lesions seen.

PANCREAS:
Pancreas obscured by bowel gas.

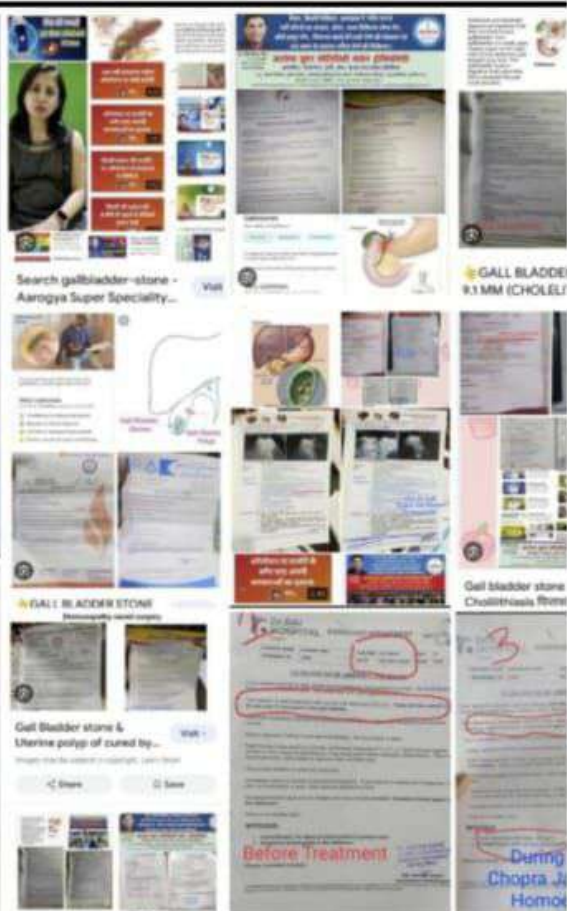
KIDNEYS:
Normal in size, shape position and echotexture. Corticomedullary differentiation is preserved. Cortical thickness is normal since calyces are normal. No hydronephrosis.

PELVIS:
Urinary bladder appears normal. Prostate is enlarged measures 25 cc.

IMPRESSION:
Cholelithiasis
GB distal
Protonormopathy

Signed By: Dr. Rahul Taneja
Senior Resident
REG NO: 18022874
Signed Date: 12-2023 12:44

AMRITA INSTITUTE OF MEDICAL SCIENCES & RESEARCH CENTRE
Main Address: Ambabandari Marg, Sector 28, Faridabad, Haryana 121002



Gall bladder stone Cholelithiasis पित्ताशय पथरी cured & responded By Dr Arpit Chopra Jain Modern Hom... Read more

After Dr Arpit Chopra Jain Modern Homoeopathy

PRAKASH DIAGNOSTICS
* Site No. 2, Sec. 3, Faridabad
Ph. 0129-2300847
Timings / 9.30 a.m. to 2.00 p.m.
PNOT Regn. / PNOT#BD02014131
* 410, Sector - 75, Faridabad
Timings / 2.00 p.m. to 8.00 p.m.
Sunday Closed
PNOT Regn. / PNOT#BD02017082
For Appointment - 9971077114

DATED: 17/01/2024

PATIENT NAME: MR. B.K. CHAURASIA AGE: 57Y/M

USG WHOLE ABDOMEN

LIVER: Shows normal in shape and size. Echogenicity is normal. Intrahepatic biliary radicals are normal. No evidence of any mass lesion seen.

GB: normal in caliber, lumen is echo free. Wall thickness is normal. CBD is normal.

SPLEEN / PANCREAS: normal in shape, size and echo texture. No evidence of any mass lesion seen.

RIGHT KIDNEY: Normal in shape, size and echo texture. Corticomedullary differentiation maintained. No hydronephrosis and calculus seen.

LEFT KIDNEY: Normal in shape, size and echo texture. Corticomedullary differentiation maintained. No hydronephrosis and calculus seen.

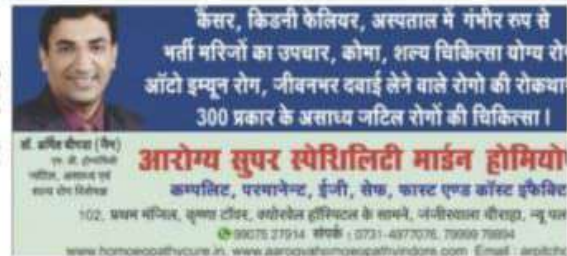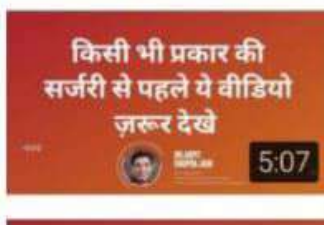URINARY BLADDER: normal in caliber. Lumen is echo free.

PROSTATE: Normal in shape, size and echotexture. Margins are well maintained. No median lobe bulge seen. No evidence of free fluid seen. No lymphadenopathy seen.

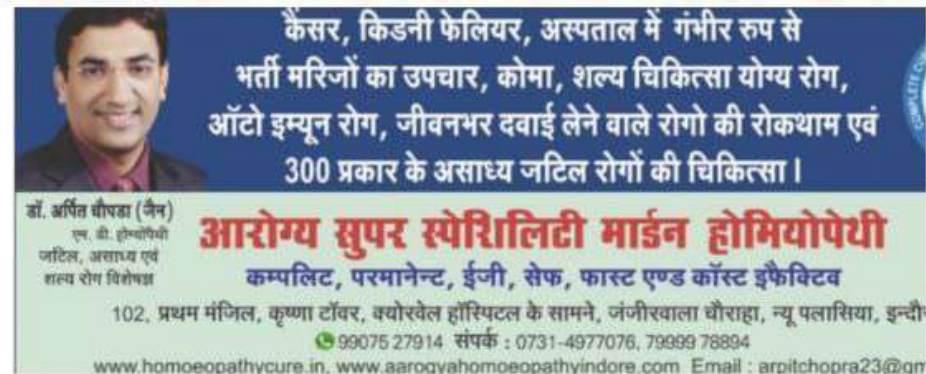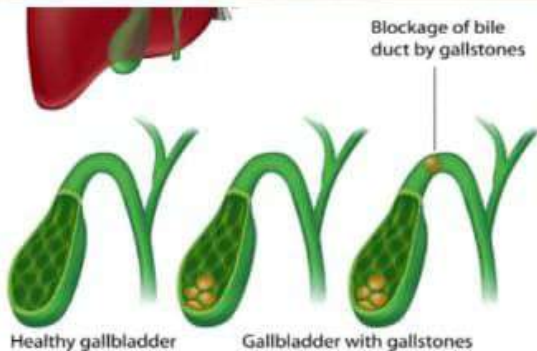
IMPRESSION: NORMAL STUDY.

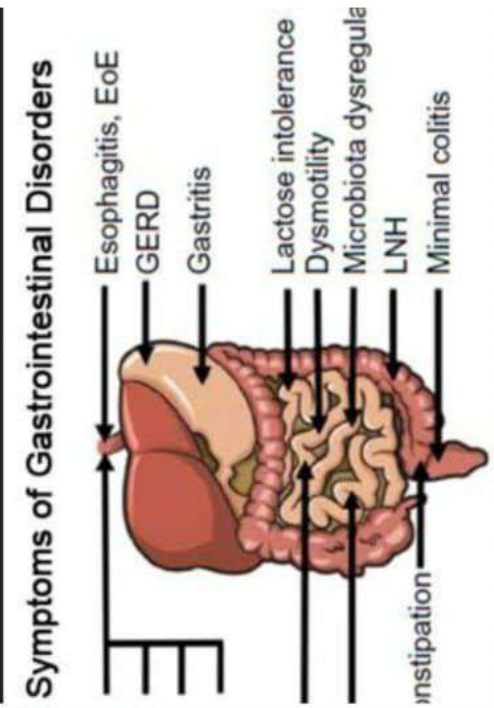
Prakash

* This is an Imaging Technique only. It should be Corroborated Clinically.
E-mail: prakashimg@prakashdiagnostics.com



Gall bladder stone Cholelithiasis पित्ताशय पथरी cured & responded By Dr Arpit Chopra Jain Modern Hom... Read more





PARK HOSPITAL
DELHI (APRIL 14, 2022) (GASTROENTEROLOGY)

Patient ID: 095-07988
Patient Name: MR. RAJESH
Age/Gender: 31Yrs, Male

Visit Date: 15/04/2022
Referred by: DR. ANSHU SAXENA
Consulted by: DR. ANSHU SAXENA

Pre-medication		
P/R	Nil	
Preparation	PEG	
Anal Canal	Hypertonia	
Rectum	Internal hemorrhoids seen	
Sigmoid Colon	Severe inflammatory changes and erosive seen.	
Descending Colon	Hypertonia	
Spleen Flexure	Normal	
Transverse Colon	Normal	
Hepatic Flexure	Normal	
Ascending Colon	Normal	
IC Valve	Normal	
Ileum		
Blampy	Not taken	
Impression	INTERNAL HEMORRHOIDS AND EROSIVE COLITIS WITH LNH	

Before Treatment

DR. ANSHU SAXENA
MRSGASTROENTEROLOGIST (MD/MS)

PARK HOSPITAL
DELHI (APRIL 14, 2022) (GASTROENTEROLOGY)

Patient ID: 095-07988
Patient Name: MR. RAJESH
Age/Gender: 31Yrs, Male

Visit Date: 15/04/2022
Referred by: DR. ANSHU SAXENA
Consulted by: DR. ANSHU SAXENA

Pre-medication		
P/R	Nil	
Preparation	PEG	
Anal Canal	Normal	
Rectum	Normal	
Sigmoid Colon	Normal	
Descending Colon	Normal	
Spleen Flexure	Normal	
Transverse Colon	Normal	
Hepatic Flexure	Normal	
Ascending Colon	Normal	
IC Valve	Normal	
Ileum		
Blampy	Not taken	
Impression	CURED	

After Dr Arpit Chopra Jain Modern Homoeopathy

DR. LALIT KUMAR DR. ANSHU SAXENA

PILES बवासीर
Piles HAEMORRHOIDS cured...
Dr Arpit Chopra's SuperS...
221 views • 2 years ago

Multiple diseases Cured होम्योपैसी से
Piles Ovarian Thyroid Diabetes
Success Story By Patient
Dr Arpit Chopra's SuperS...
188 views • 2 years ago

PILES बवासीर
Piles Haemorrhoids cured By Dr Arpit Cho...
Dr Arpit Chopra's SuperS...
76 views • 2 years ago

PILES बवासीर
Piles bleeding haemorrhoids cured ...
Dr Arpit Chopra's SuperS...
81 views • 2 years ago

PILES बवासीर
Piles | बवासीर (पाइल्स) का इलाज | Piles Succ...
Dr Arpit Chopra's SuperS...

Piles - बवासीर
Piles Anal Fissure cured of long sufferin...
Dr Arpit Chopra's SuperS...
219 views • 2 years ago

Piles - बवासीर
Piles | Anal fissure | Fistula | Patient Suc...
Dr Arpit Chopra's SuperS...
519 views • 1 year ago

Piles - बवासीर
Piles | बवासीर (पाइल्स) का इलाज | Piles Succ...
Dr Arpit Chopra's SuperS...
170 views • 1 year ago

Anal Fistula
Anal Fistula | Anal fissure cured | Anal Fi...
Dr Arpit Chopra's SuperS...
3.9K views • 1 year ago

Piles - बवासीर
Piles | बवासीर (पाइल्स) का इलाज | Piles Succ...
Dr Arpit Chopra's SuperS...

सबसेस स्टोरीस
IBS cured | IBS Recovery Patient Suc...
Dr Arpit Chopra's SuperS...
2K views • 1 year ago

ULCERATIVE COLITIS CURED PERMANENT...
Ulcerative Colitis Cured | Ulcerative Col...
Dr Arpit Chopra's SuperS...
4.1K views • 1 year ago

Colitis Abdominal pain Gastric disease cure...
Colitis Abdominal pain Gastric disease cured in 1 month by Dr...
Dr Arpit Chopra's SuperS...
156 views • 1 year ago

Gastrointestinal & Hepatic diseases पेट ...
Gastrointestinal & Hepatic diseases पेट ...
Dr Arpit Chopra's SuperS...
534 views • 1 year ago

Piles Haemorrhoids पाइल्स (बवासीर) cured ...
Piles Haemorrhoids पाइल्स (बवासीर) cured ...
Dr Arpit Chopra's SuperS...
452 views • 1 year ago

Gastrointestinal & Hepatic diseases पेट ...
Gastrointestinal & Hepatic diseases पेट ...
Dr Arpit Chopra's SuperS...
534 views • 1 year ago

Anal fissure chronic problem cured by Dr ...
Anal fissure chronic problem cured by Dr ...
Dr Arpit Chopra's SuperS...
150 views • 1 year ago

Piles Haemorrhoids| बवासीर | Dr Arpit Cho...
Piles Haemorrhoids| बवासीर | Dr Arpit Cho...
Dr Arpit Chopra's SuperS...
118 views • 11 months a...

Piles| बवासीर | Haemorrhoids | Dr A...
Piles| बवासीर | Haemorrhoids | Dr A...
Dr Arpit Chopra's SuperS...
108 views • 11 months a...

आर्योप्य सूर्य रेस्पिटरी औसिन होम्योपैथिक वर्गीकृत

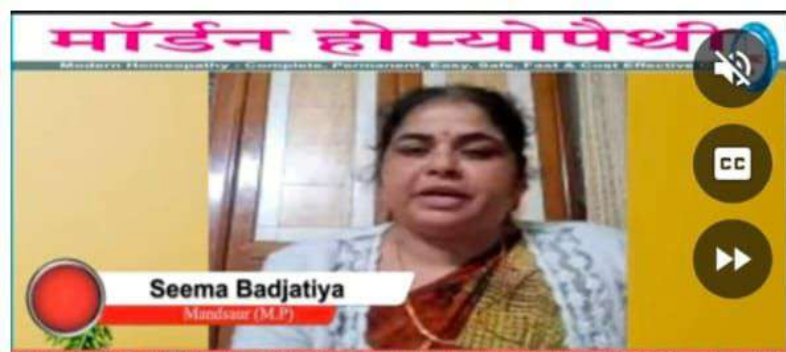102, राम वीणा, गुरु टॉवर, सोनीपत गिफ्टवॉर के समीप, सोनीपत सिटी, च. सोनीपत, पंजाब (IN)

फोन: 0731-4977076, मो. 97131-97173, 97131-97173, 79999-78884, 99072-79714

www.homeopathycentre.in, www.aaryohomeopathyhindve.com, Email: arpitchopra22@gmail.com

COMPLETE CURE FOR ALL TYPES OF COLITIS

आर्योप्य

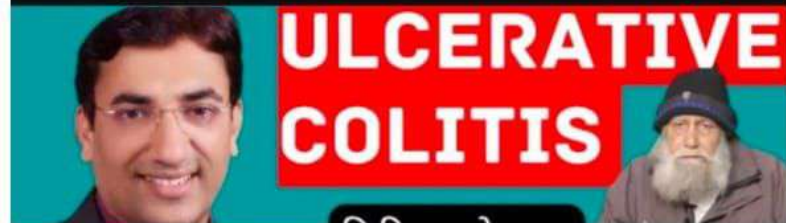

Seema Badjatiya

Mandsaur (M.P)

Dr.Arpit Chopra (Jain) AAROGYA SUPERSPECIALTY MODERN HOMEOPATHY CLINIC
 Complete, Safe, Fast & Cost-Effective Modern Homeopathy Cured With Advanced Lifestyle
 CRITICAL & SURGICAL DISEASES SPECIALIST
 Mentor of Super Speciality Modern Homeopathy
 Phone : 0731-4977076, Mobile : 97130-92737, 97130-37737, 79999-78894, For WhatsApp
10:20
 N, THYROID DISORDER, INFERTILITY, IMPOTENCY

ULCERATIVE COLITIS CURED PERMANENT BY DR ARPIT CHOPRA J...
 Dr Arpit Chopra's SuperSpecialty
 ModernHomoeopathic · 2.9K views · 2 years ago



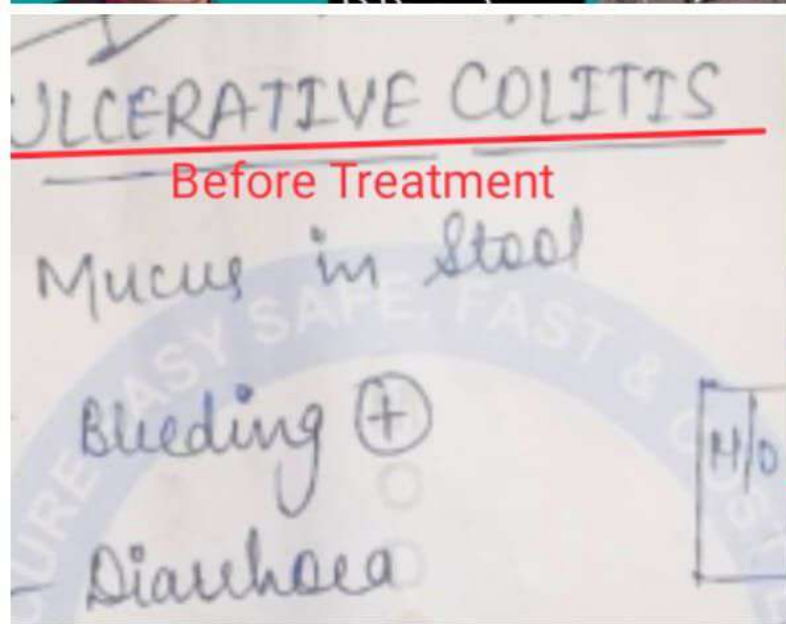
Indore Institute of Gastroenterology
 ADVANCED ENDOSCOPY CENTER
 GASTRO AND LIVER CLINIC
 312, Professor Colony, Near Agrawal Sweet, Opp.Matlani Garden,
 Tower Choraha, Indore, Phone No. (0731) 4298999, Mob - 8447612109

Patient ID : 02680 Visit Date : 21/Mar/24
 Patient Name : Miss.Arvati Patwa Referred by : Dr.Sunny Bherwani MD.DM. (Gastro)
 Age/Gender : 25Yrs, Female Consulted by : Dr.Sunny Bherwani MD.DM. (Gastro)

SIGMOIDOSCOPY REPORT

MENT : PENTAX i7010
 ATION : Pain in Lower Abdomen.
 CANAL : Small Internal Hemorrhoids present @ 3,7, and 11 o clock position with Red color sign present.
 IM : Mucosa Normal Upto Rectum to Transversal Colon . No Ulcer Seen.
 D COLON : Normal
 NDING COLON : Normal
 IC FLEXURE : Normal
 SVERSE COLON : Normal
 Y : Not taken
 ESSION : Small Internal Hemorrhoids present @ 3,7, and 11 o clock position with Red color sign present.
 Mucosa Normal Upto Rectum to Transversal Colon , No Ulcer Seen.

After Dr Arpit Chopra Jain Modern Homoeopathy




ULCERATIVE COLITIS

क्रिटिकल केस का सफल ईलाज श्रीमती शान्ती पोरवाल

सक्सेस स्टोरी
 मॉडर्न होमियोपैथी बे. 18:40

Dr. Arpit Chopra Jain
 (MD Homoeopathy
 Critical & Surgical
 Case Specialist)

Ulcerative Colitis Cured | Ulcerative Colitis Cure Stories|Dr. Arpit Chopra J...
 Dr Arpit Chopra's SuperSpecialty



* कैंसर * किडनी फेलियर * अस्पताल में गंभीर रूप से मर्ती गरिजों का उपचार * कोमा * शल्य चिकित्सा योग्य रोग * आटो इन्स्युलिन रोग * जीवनभर दवाई लेने वाले रोगों की रोकथाम एवं 300 प्रकार के असाध्य जटिल रोगों की चिकित्सा

आरोग्य सुपर स्पेशलिटी मॉडर्न होमियोपैथिक क्लीनिक
 कम्प्लिट * परमानेंट * ईजी * सेफ * फास्ट एण्ड कॉस्ट इफेक्टिव
 102, प्रथम मंजिल, कृष्ण टॉवर, क्वोरवेल हॉस्पिटल के सामने, बंजीरवाला चौराहा, न्यू पतारिया, इन्दौर (म.प्र.)
 फोन : 0731-4977076, मो. : 97130-92737, 97130-37737, 79999-78894, 99075-27914
 www.homeopathycure.in, www.aarogyahomeopathyindore.com Email: arpit Chopra23@gmail.com

आरोग्य
 COMPLETE CURE FAST SAFE, FAST & COST EFFECTIVE
 MODERN HOMEOPATHY
 + EN +
 HOMOEOPATHY

कैंसर, किडनी फेलियर, अस्पताल में गंभीर रूप से
 भर्ती मरिजों का उपचार, कोमा, शल्य चिकित्सा योग्य रोग,
 ऑटो इम्यून रोग, जीवनभर दवाई लेने वाले रोगो की रोकथाम एवं
 300 प्रकार के असाध्य जटिल रोगों की चिकित्सा ।



डॉ. अर्पित चौपडा (जैन)
 एम. डी. होम्योपैथी
 जटिल, असाध्य एवं
 शल्य रोग विशेषज्ञ

आरोग्य सुपर स्पेशलिटी मॉडर्न होमियोपैथी

कम्पलिट, परमानेन्ट, ईजी, सेफ, फास्ट एण्ड कॉस्ट इफैक्टिव

102, प्रथम मंजिल, कृष्णा टॉवर, क्योरवेल हॉस्पिटल के सामने, जंजीरवाला चौराहा, न्यू पलासिया, इन्दौर म.प्र.

99075 27914 संपर्क : 0731-4977076, 79999 78894

www.homoeopathy cure.in. www.aarogyahomoeopathyindore.com Email : arpitchopra23@gmail.com

X-Ray & Sonography Centre
 12, Main Street, Near Pragna National Park, Indore (M.P.) 462 011
 Phone : 0731-273231 Dr. Ravi 274931
 Email : aarogyaarogya@gmail.com
 04241011978@gmail.com
 Regn. No. : 2013/004 PG-PNDT Act II, 145-11, Ministry of Health, Govt. of Madhya Pradesh, Indore

MR. BHUSHAN MAHADEO RAO 46 YRS / MALE 16.04.15
 DR. C. S. PANDIT MBBS

ABDOMINAL ULTRASONOGRAPHY
Before Treatment

INDICATION : Pain abdmn
 ETY. MIDDM
 Liver is of normal size and shape, has smooth and regular margins and reveals homogenous hyperechoic parenchymal echotexture (fatty infiltration). No focal lesion.
 Gall bladder is of normal size and shape. It has thin walls and reveals a 18mm sized and few stones.
 Intra and extrahepatic biliary radicles are undilated. Portal vein is normal in calibre and excursion.
 Pancreas is of normal size, contours and echostructure.
 Spleen is of normal size and reveals homogenous parenchymal echotexture.
 Both the kidneys are of normal in size and shape. The renal contours are smooth and regular. Corticomedullary differentiation is normal on either sides.
 No polycalycal dilatation noted on either sides. Small calculus (06mm) noted in right lower calycal region.
 Ureters are undilated. No calculus.
 Urinary bladder is normal in size, shape has thin walls (prevoid volume 200 ml). Prostate is of normal size and reveals homogenous echostructure. No significant post void residue noted (approx. 20 ml).
 IVC and abdominal aorta are normal. No obvious nodes.
 No ascites.
 No pleural effusion noted on either sides.
 On examination with high frequency probe there is a fascial defect (about 06mm) noted in umbilical region with oval herniation of omentum no raised intraabdominal pressure.

IMPRESSION:
 Cholelithiasis.
 Small (06mm) Right lower calycal calculus.
 Umbilical hernia.

Further clinicopathological correlation however is requested.

CHOUHAN DIAGNOSTIC CENTRE
 Dr. Ravindra Singh Chouhan
 MBBS, DMRD
 Radiologist & Sonologist
 Reg. No. : MP-6398

51, प्लाज्डन रोड, बिल्डर मेमोरियल चर्च के सामने एण्ड रेडक्रॉस हॉस्पिटल के पास, न्यू पलासिया, इन्दौर म.प्र. 462015
 मो. : 7089097337

NAME : Mr. Bhushan Mahadeo RAO
 REF BY : DR. M. K. TIWARI MBBS MS
 DATE : 19-Mar-24

After Dr Arpit Chopra Jain Modern Homoeopathy

Ultrasound examination of Whole Abdomen

Liver is normal in size, and parenchymal echotexture of liver is raised

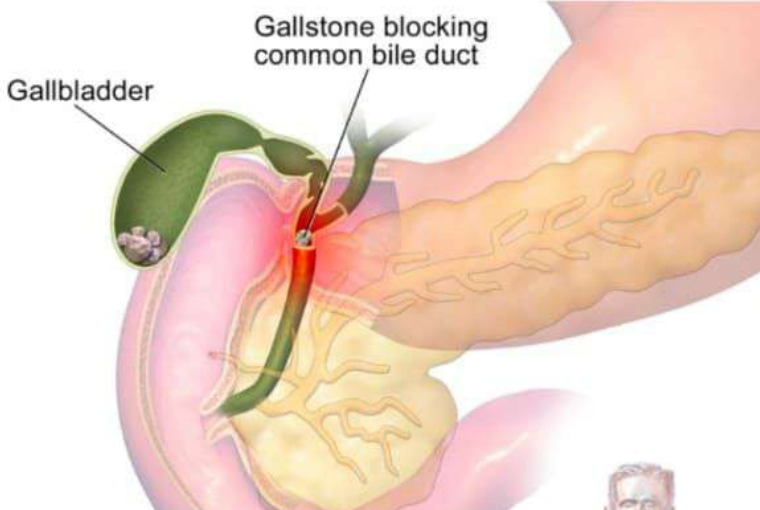
The intra hepatic biliary radicles look normal. No focal lesion seen. Portal vein is normal in caliber.
 The gall bladder is well distended with smooth outline. No obvious calculus detected. The CBD is normal.
 Spleen is normal in size (8.6 cm) and pancreas is normal.
 Right kidney : - 9.5 x 4.5 cms Left kidney : - 10.0 x 4.5 cms
 Both kidneys appear normal in size, shape and echogenicity. No hydronephrosis, or perinephric pathology seen.
 Right kidney shows a calculus of size about 3-4 mm in the upper pole calyx, and a calculus of size about 4-5 mm in the mid pole calyx.
 Left kidney shows a small calculus of size about 3-4 mm in the mid pole calyx, and a calculus of size about 4-5 mm in the lower pole calyx.
 Urinary bladder is partially filled at the time of examination. Prevoid :- 100 ml, postvoid :- 30 ml (Significant).
 Prostate borderline enlarged in size (3.6 x 2.9 x 4.4 cm WT :- 25-26 gms).
 No free fluid seen in the peritoneal cavity.
 Umbilical hernia noted, the gap is about 13-14 mm, the content of hernia is fat / omentum.

IMPRESSION :- Umbilical hernia.
 :- Borderline prostatomegaly.
 :- Bilateral renal calculi.
 :- Significant postvoid residual urine.
 :- Fatty infiltration of liver (Grade 4-II).

Please correlate clinically

Dr. Ravindra Singh Chouhan
 MBBS, DMRD
 Radiologist & Sonologist
 Reg. No. : MP-6398

All Sonography Test have Technical & Biological limitations.
 Please Correlate Clinically as with other investigative.
 All view should be requested in case of any disparity.
 This report is not valid for medico legal purpose.



अब नहीं करवाना पड़ेगा
 ऑपरेशन या कोई सर्जरी
 4:26

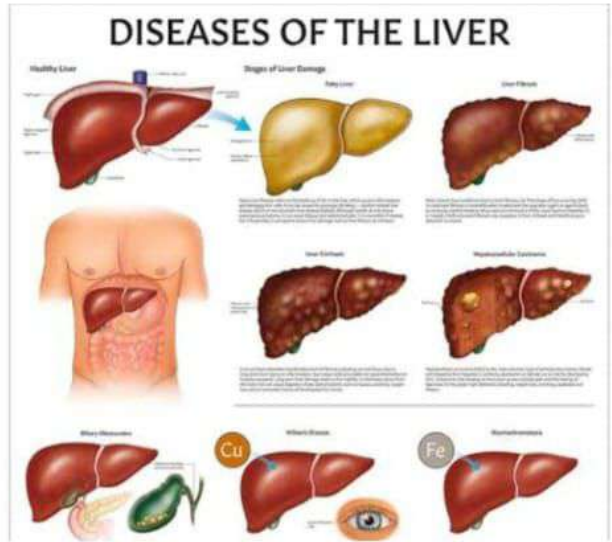
ऑपरेशन या सर्जरी के
 बगैर पाए अपनी
 समस्याओं का इलाज
 5:45

किसी प्रकार की सर्जरी
 या ऑपरेशन से बचाएगा
 ये वीडियो
 5:53

किसी भी प्रकार की
 सर्जरी से पहले ये वीडियो
 जरूर देखें
 5:57

0:42
 15:14
 19:47
 20:23

“Grade 2 fatty liver disease” is the term for moderate fatty liver disease and its symptoms. To treat grade 2 fatty liver disease, a doctor may suggest that a person lose weight. This can help reduce liver inflammation and the amount of fat in the liver. 5 Sept 2023



SHIVANI
DIAGNOSTIC CENTRE

9-B, Bhawanipur Colony,
Annapurna Main Road, Indore
0731-4063074, 3594028
9109109182
shivani@diagnostic39@gmail.com
www.shivandiagnostic.com

REPORT

Pathology Sonography Digital X-Ray Colour Doppler ECG Echocardiography TMT

Patient ID - 010723224 Registration on 01/07/2023

Patient Name Mrs. SUSHILA SHAKYA Report on 01/07/2023

Age / Gender 50Yrs / Female

Ref. By DR. ARPIT CHOPRA JAIN

WHOLE ABDOMEN SONOGRAPHY

Hepatic contour is smooth & span (15.3 cm) is mild enlarged. Parenchymal echotexture is raised.
Portal vein is normal in caliber. No focal lesion is seen. Intrahepatic biliary radicles & hepatic veins are undilated.
Gall bladder is not visualized (H/o Surgery). CBD undilated.
Pancreas is normal in shape & size. Parenchymal echoes are normal. Pancreatic duct is undilated. Spleen is normal (8.5 cm). No focal lesion seen.
Right kidney is (10.4 x 3.8 cm) in size and normal in position, contour, echotexture and pcs undilated.
Left kidney is (10.0 x 5.0 cm) in size and normal in position, contour, echotexture and pcs undilated. CM differentiation is maintained. Both ureters are undilated and VUJ clear.
Urinary bladder shows normal wall & echo free lumen.
Uterus is normal for age & show senile atrophic changes. Long axis measures is 6.5 cm. ET. 2.9 mm. Both adnexa are unremarkable. Both ovaries are small in size.
No significant retroperitoneal lymphadenopathy seen.
No free fluid seen in peritoneal cavity.

IMPRESSION : MILD HEPATOMEGALY WITH FATTY LIVER (GRADE II).

SUGGEST CLINICAL CORRELATIONS & FOLLOW-UP.

DR. KAPIL KUMAR UIKEY
M.B.B.S., D.M.R.D. (Reg. No. MP-13466)

Before Treatment

REF. BY: DR ARPIT CHOPRA MD

DATE: 26 MAR.2024

USG - WHOLE ABDOMEN

Clinical history- Burning sensation in epigastrum.	Limitation-None.
Patient Cooperation-Optimum.	Comparison- None.

Liver measures 15.1 cm and shows diffusely increased hepatic echogenicity but periportal and diaphragmatic echogenicity is still appreciable. The status of hepatic vein and IVC appears normal. Portal (0.8 cm) and hepatic veins appear normal. No focal lesion is seen. No IHBR dilatation seen.

Gall bladder is not visualized- history of Cholecystectomy in past. The CBD appears normal.

Pancreas appears normal. Spleen (8.1 x 2.5 cm) is normal in size & echotexture.

Kidneys: RK (10.5 x 3.8 cm) & LK (10.9 x 4.4 cm).

Both kidneys are normal in size, shape, position and echogenicity. Central pelvicalyceal sinus and corticomedullary ratio appears normal.

No significant intra-abdominal lymphadenopathy. No evidence of ascites.

Urinary bladder appears normal with normal caliber walls and anechoic contents. Post void residual volume is insignificant.

Antverted retroflexed postmenopausal normal sized uterus for age, measuring 5.9 x 2.7 x 4.2 cm with centrally placed endometrium (Endometrial thickness measuring approx. 0.45 cm).

Both ovaries are not clearly delineated. No significant free fluid seen in cul-de-sac.

Subtle wall edema along wall of pylorus and visualized segment of duodenum. No significant wall thickening. No perifocal stranding is seen.

After Dr Arpit Chopra Jain Modern Homoeopathy

Impression:
Features of fatty liver (Steatosis Grade -I).
Subtle wall edema along wall of pylorus and visualized segment of duodenum with no significant wall thickening or perifocal stranding. Likely suggestive of enteropyloric gastritis with mild duodenitis.

DR. RAJESH KUMAR GUPTA
DNE, DMR, F.M.S. (S), F.M.S. (G)
Sr. Consultant, Consultant in
Radiology (CT & MRI) and Interventional
Fluoroscopic services in Hospital in case of all phases contrast for
all cases. Contact for Dr. Arpit Chopra

DR. RAJESH KUMAR GUPTA
DNE, DMR, F.M.S. (S), F.M.S. (G)
Sr. Consultant, Consultant in
Radiology (CT & MRI) and Interventional
Fluoroscopic services in Hospital in case of all phases contrast for
all cases. Contact for Dr. Arpit Chopra

ModernHomoeopathic · 175 views · 11 months ...

6:16

Chronic Liver disease Cirrhosis responded by Dr ArpitChopra Modern ...

Dr Arpit Chopra's SuperSpecialty
ModernHomoeopathic · 193 views · 11 months ...

* कैंसर * किडनी फेलियर * अस्पताल में गंभीर रूप से मर्ती मरिजों का उपचार * कोमा * शल्य चिकित्सा योग्य रोग * आंठो इन्फ्यूजन रोग * जीवनमर दवाई लेने वाले रोगों की रोकथाम एवं 300 प्रकार के असाध्य जटिल रोगों की चिकित्सा

आरोग्य सुपर स्पेशलिटी मॉडर्न होम्योपैथिक क्लीनिक

कम्पलिट * परमानेंट * ईजी * सेफ * फास्ट एण्ड कॉस्ट इफैक्टिव

102, प्रथम मंजिल, कृष्णा टॉवर, क्योवेल हॉस्पिटल के सामने, जंजीरवाला चौराहा, न्यू पलासिया, इन्दौर (म.प्र.)
फोन : 0731-4977076, मो. 97130-92737, 97130-37737, 79999-78894, 99075-27914

www.homoeopathycure.in, www.aarogyahomoeopathyindore.com Email: arpit Chopra23@gmail.com



ASHIRWAD IMAGING CENTRE
 16 Slice MDCT Scan, Live 3D-4D Sonography, High Resolution Sonography,
 Whole Body Color Doppler, Digital Mammography, Digital X-Ray.

ULTRASOUND REPORT

Pt. Name : Ramila Bharatsing Mohaniya Age : 25 Yrs.
 USG ID : E72798 19070421 Date : 04/07/2019

USG ABDOMEN

Liver is normal in size and shows normal echotexture. No focal lesion seen. I.H.B.R. not dilated. Portal vein is normal in size.

Gall bladder is distended and shows presence of multiple small gall stones of 5 to 8 mm size. CBD measures 12 mm at porta. There is presence of 9 x 6 mm size stone in lower CBD.

Pancreas is normal in size and echogenicity

Spleen is normal in size and echogenicity. No evidence of focal lesion. Splenic vein is normal in size. No evidence of varices at splenic hilum

Right kidney measures : 10.7 x 4.0 cm.
 Left kidney measures : 9.9 x 4.1 cm.
 Both kidneys are normal in size, shape and position. No evidence of renal stone. No evidence of dilatation of pelvi-calyceal system. Cortical thickness and echo are normal.

Urinary bladder is normally distended. No evidence of stone or S.O.L.

Uterus measures 9.8 x 5.1 x 3.6 cm. No evidence of focal lesion. Uterine cavity is empty. Myometrial echo is normal. Endometrial echo thickness is normal.

Both ovaries are normal in size and echotexture.

No evidence of free fluid in peritoneal cavity.

COMMENTS:

- MULTIPLE GALL STONES.
- STONE IN LOWER CBD WITH MILD DILATATION OF CBD. IHBR ARE NOT DILATED.

Dr. Bhavin Patel
 Radiologist

Ashirwad Hospital Campus, Govind Nagar, Dahod - 389151, Gujarat. Phone : (02673) 247888

SHIVANI DIAGNOSTIC CENTRE
 ISO 9001 : 2015 NABL MC-2597

Pathology • Sonography • Digital X-Ray • Colour Doppler • ECG • Echocardiography • TMT

Pt. Name: MRS. RAMILA MOHANIYA Age/Sex: 26 Years /Female
 Ref. By: DR. ARPIT CHOPRA Date: 31/Aug/2019

WHOLE ABDOMEN SONOGRAPHY

Hepatic contour is smooth & span (13.4 cm) is normal. Parenchymal echotexture is normal. CBD (3.5 mm) & Portal vein are normal in caliber. No focal lesion is seen. Intrahepatic biliary radicles & hepatic veins are undilated.

Gall bladder is distended. Multiple (> 10) calculi of varying sizes (3-5 mm) seen within its lumen. Walls are thin (2.6 mm)

Pancreas is normal in shape & size. Parenchymal echoes are normal. Pancreatic duct is undilated

Spleen is normal (11.0 cm). No focal lesion seen

Right kidney is (9.9 x 4.3 cm) in size and normal in position, contour, echotexture and pcs undilated. Left kidney is (10.1 x 3.7 cm) in size and normal in position, contour, echotexture and pcs undilated. CM differentiation is maintained. Both ureters are undilated and VUU clear

Urinary bladder shows normal wall & echo free lumen.

Uterus is Anteverted & normal in size. It measures (9.5 L X 3.3 AP X 4.2 T cm). Uterine contours are smooth, myometrium is homogenous. No focal myometrial lesion seen. Endometrium is measuring 8.5 mm

Right ovary measures is 3.2 x 1.6 x 2.1 cm (Vol. 5.3 ml) & Left ovary measures is 3.1 x 1.5 x 1.9 cm (Vol. 4.1 ml) in size. Both adnexa are unremarkable & ovaries are normal in size.

No significant retroperitoneal lymphadenopathy seen.

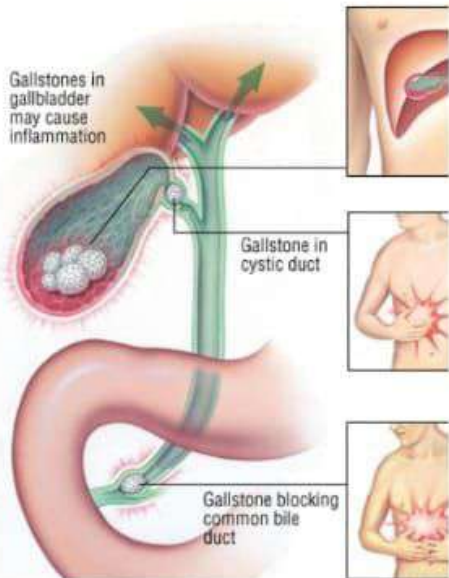
No free fluid seen in peritoneal cavity

IMPRESSION : CHOLELITHIASIS.

SUGGESTED CLINICAL CORRELATION & FOLLOW-UP.

DR. KAPIL KUMAR UIKEY
 M.B.B.S, D.M.R.D. (Reg. No. MP-12466)

FOR HOME SAMPLE
 Call : 9109109190, 9109109192
 9/2, Bhawanipur Colony, Annapurna Main Road, Indore • Ph. : 0731-2482243, 4053074



31 CHOLELITHIASIS पित्त के पथ में
 GALL BLADDER STONE

Multiple stones in gall bladder
 size 3 to 5 mm
 wall of gall bladder is thickened
 size 12 mm
 stone in lower CBD
 size 9 x 6 mm

Dr. Arpit Chopra (HOD)
 RADIOLOGY SUPER SPECIALIST
 91 7947 8700



shupatinath Diagnostic Center

SRLN 1176 Date: 14/03/2019
 Patient's Name: MRS. AASHA JI Age: 45 yrs Sex: Female
 Ref. By: Dr. K. L. PAWAR, SIR

SONOGRAPHY OF ABDOMEN AND PELVIS

LIVER: The liver normal in size (13.1 cm) shape and has smooth margins. The hep parenchyma is homogeneous. No IHBRD/IHPRD. No solid or cystic SOL/calcification.

GALL BLADDER: is slightly over-distended with wall thickening of ~4 mm. A lo echogenic focus measuring ~20 mm noted impacted at GB neck. Also noted is organ sludge in GB fundus measuring ~28 x 14 mm. Few tiny GB calculi noted measuring ~3m. No pericholecystic collection is evident. PV & CBD appears normal.

PANCREAS: The pancreas is normal in size, shape, contours and echo texture. No evidence of solid or cystic mass lesion is noted.

KIDNEYS: Both kidneys are normal in size and have smooth renal margins. CMD maintained. No evidence of any mass lesions. No calculus / hydronephrosis is noted on either sides. RK: 9.9 x 3.8 cm, LK: 9.6 x 4.7 cm.

SPLEEN: The spleen is normal in size (9.9 cm) and shape. Its echotexture is homogeneous. No evidence of focal lesion is noted.

RETROPERITONEUM: The retroperitoneum is not well seen due to bowel gases. Gr vessels appear grossly normal. There is no ascites.

ILIAC FOSSA AND BOWELS: The iliac fossa, the visualized small and large bowels appear unremarkable.

URINARY BLADDER: The urinary bladder is distended. It appears grossly normal. No evidence of calculus is seen. No evidence of mass or diverticulum is noted.

PELVIS: The uterus is anteverted, bulky in size with heterogenous myometrium. It measures 9.8 x 4.9 x 5.9 cm. ET-10 mm. Both adnexae and ovaries are normal in size. Size of right ovary 2.5 x 1.3 cm. Size of left ovary 2.5 x 1.4 cm. No free fluid/mass is noted in the pelvis.

IMPRESSION:
 Chronic calculous cholecystitis with tumefactive sludge
 Bulky uterus with features of adenomyosis

DR. MANISHA (BHAWARE) ASWANI
 CONSULTANT RADIOLOGIST

Behind Maharanj Laxmibai School
 Near Old & New Book Depo, Balaganj
 Gandhi Chauraha, MANDSAUR (M.P.) 07422-495503

Agrawal Ultrasound Clinic

Pt. Name: AASHA JI Age: 45/F
 Ref. by: ON REQUEST Date: 27/06/19

USG ABDOMEN & PELVIS REPORT.

Real time USG done with 3.7 MHz convex probe.

LIVER - Normal in size & shape. Echogenicity is normal. Echotexture is smooth. No focal lesions seen. Portal vein Diameter is within normal limit.

SPLEEN - Normal in size & shape. Echogenicity is normal & shows smooth Echotexture. No focal lesions seen.

GALL BLADDER - Well distended; Evidence of Single Echogenic focus in GB Neck with Sharp Distal acoustic shadowing suggestive of Gall stone measuring 19 mm. Wall thickness is normal, Intra & extrahepatic biliary system not dilated. No peri-cholecystic collection noted. CBD is normal.

PANCREAS - Normal Echogenicity; no focal or diffuse enlargement. No Retroperitoneal Lymphadenopathy. PD not Dilated.

BOTH KIDNEYS - Normal in size, shape and shows good Cortico-Medullary differentiation. Echotexture normal. No Hydronephrosis or calculus seen.

Right kidney-measures 9.9 x 3.8 cm.
 Left kidney-measures 10.7 x 4.1 cm.

URINARY BLADDER - well distended; no calculi or mass seen. Mucosa Smooth and thickness within normal limit. Lumen is Anechoic. Postvoid Residue is Insignificant.

UTERUS - is Anteverted; Enlarge in size Measures 11.4 x 5.2 x 7.0 cm (Vol - 222 cc) and Heterogenous Echotexture. Evidence of 2.7 x 1.7 cm size Welldefined, Hypoechoic solid lesion with whorled pattern seen in Posterior Subserosa Fundal region, Suggestive of Subserosal Fibroid. Endometrial echo-complex is not Displaced, Endometrial Thickness within normal limit.

BOTH ADNEXA - Both Ovaries are Normal in size and echoarchitecture. No T.O. Mass or focal lesions seen.

Visualised bowel loops appears normal in caliber & showing normal peristaltic movement. No ascites. No lymphadenopathy.

IMPRESSION - USG Abdomen & Pelvis shows Gall Bladder Neck Calculus.
 Bulky Uterus with Posterior Subserosal Uterine Fibroid.
 Kindly Correlate Clinically.

THANKS FOR THE REFERRAL
 Important: owing to technical & biological limitations in case of any error in any study, the doctor cannot be held responsible for claims of damages of any nature and this report is Not valid for any medical/legal purpose.

Dr. Deepak M.B.B. Radiologist

Dr. Majhar Hussain, Behind Dashpur Kunj, Mandasaur (M.P.) Ph. 07422-495503

CHOLELITHIASIS (GB Stone)
GALL BLADDER STONE 27

In a GALL BLADDER there is 20mm stone & 28x14mm stone. Taken Homeopathy medicine after 3 (three) month gallstone is fully dissolved & 20mm stone is decreased to 18mm in size with it is on a PACS of a GALL BLADDER. I hope it will dissolved with soon, please Homeopathy & DR. PAREET CHOPRA Ji.

NAME - HARIOM PATIL
 Patient Name - ASHA Patil
 no. - 8193201862

Respected

Sunday 28

Dr. Anshu Chopra (Jain)
 M.D. (HOMOEOPATHY)
 M.P. (HOMOEOPATHY)
 M.P. (HOMOEOPATHY)

AMRITA SUPER SPECIALITY HOMOEPATHIC CLINIC
 Mandasaur, Dist. Mandasaur, M.P. 468001
 Phone: 07422-495503

Gallbladder with stones



A hardened deposit within the fluid in the gallbladder, a small organ under the liver.

Gallstones are hardened deposits of digestive fluid.

Very common
 More than 10 million cases per year (India)

- Treatable by a medical professional
- Requires a medical diagnosis
- Lab tests or imaging always required

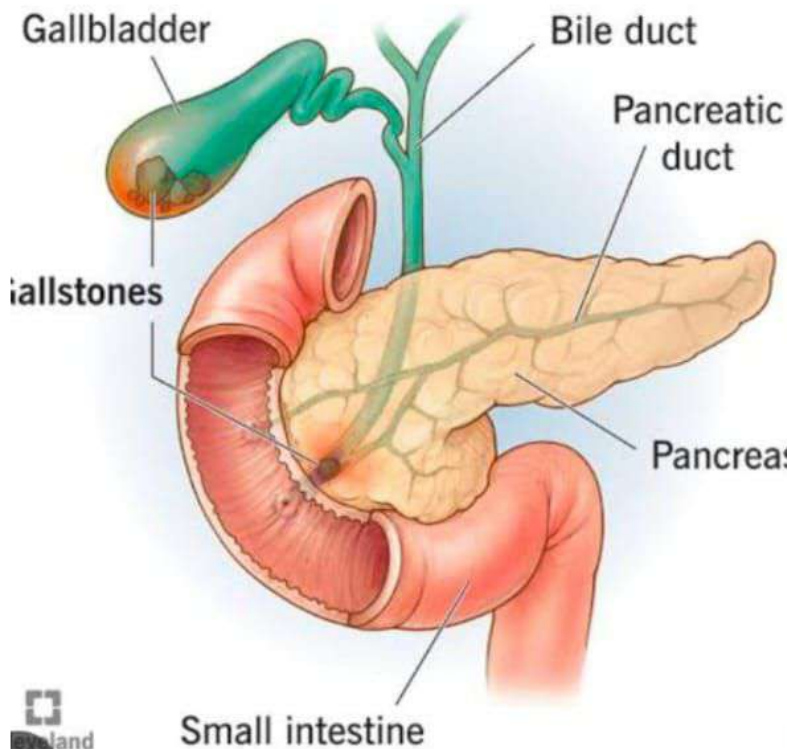
Biliary sludge

Biliary sludge refers to a viscous mixture of small particles.

HEALTH CONDITIONS RELATED TO THIS SEARCH

- Cholecystitis**
 Inflammation of the gallbladder, a small digestive organ beneath the liver.
- Pancreatitis**
 An inflammation lying behind the stomach.

Gallstones



SODANI DIAGNOSTIC CLINIC
(Sodani Hospitals & Diagnostics Pvt. Ltd.)

MEDICAL REPORT

Patient Name	Mrs. JYOTI VACHMANI	Sample ID	502942415809	View Report
DOB/Age/Sex	62 years/Female	Registered	Apr 27, 2024, 11:43 a.m.	QR Code
Mobile	9000453564	Collected On	Apr 27, 2024, 01:20 p.m.	
Referred By	Dr. Arpit Chopra Jain (MD Homeo)	Approved On	Apr 27, 2024, 01:28 p.m.	
Organization	Sodani Diagnostic (Tower Square)			

WHOLE ABDOMEN SONOGRAPHY

Liver is mildly enlarged (Span 16.6 cm). Parenchymal echotexture is normal. No focal lesion is seen. Intrahepatic biliary radicals are undilated.

Gall bladder is normally distended. Walls are thin. Multiple calculi (4-5) are seen in GB lumen, largest measuring 28 mm. No per GB collection is noted.

Portal vein & CBD are normal in caliber.

Pancreas is normal in shape & size. Parenchymal echoes are normal. Duct is undilated. Spleen is normal (10.1 cm). No focal lesion seen.

Both kidneys are normal in position & size. Right kidney is 10.3 x 4.2 cm & left is 10.7 x 6.0 cm in size. Cortical echoes are normal. Right kidney shows a 13 x 16 mm size cortical cyst at upper pole. Pelvicocystic system is undilated. Both ureters are undilated. No calculi seen at UJ & UVJ.

Urinary bladder shows normal walls & echofree lumen. No intra luminal lesion or calculi seen.

Uterus is anteverted. It measures 7.0 x 4.4 x 4.2 cm. No focal myometrial lesion seen. Cervix is bulky (3.2 cm). Few nabothian cysts are seen in cervix, largest measuring 14 x 7 mm. Endometrium is thickened measuring 2.6 cm showing cystic changes within.

Both ovaries are postmenopausal, atrophic.

No free fluid seen in cul-de-sac. No significant Ascites. No pleural effusion. No significant bowel wall thickening / dilatation or lymphnodes are noted.

Impression:
Mild hepatomegaly.
Cholelithiasis.
Thickened endometrium with cystic changes.

Advice: Endometrial biopsy for further evaluation.

Before Treatment Gall bladder stone 28 mm

Dr. Akshita Chouhan
MD (HOMEO) (SODANI)
Reg. No. MP 2895

Responded After Dr. Arpit Chopra Jain Modern Homeopathy
Dr. Q.C. Labs
Accurate Imaging & Advance Pathology

D/4D USG | Echocardiography | Digital X-Ray | Procedures | Advance Pathology | Histopathology | Cytology

Patient's Name : MRS. JYOTI VACHMANI
Age & Sex : 61 Yrs. Female
Referred by : DR. ARPIT CHOPRA (JAIN) M.D. HOMEOPATHY
Consultant : DR. ARPIT CHOPRA (JAIN) M.D. HOMEOPATHY
Ref. No. : 2425-0004113
Report Date: 08-Jun-2024

USG Abdomen & Pelvis

Clinical data: Pain abdomen

LIVER: is enlarged in size (15.5 cm) & shows raised echotexture (Grade-I fatty changes). No evidence of any focal pathology. Intrahepatic biliary radicals are not dilated.

GALL BLADDER: is overtly distended (measuring 10.8 x 3.9 cms) & shows (atleast 2-3 in number) 2.1 cm, 2.4 cm & 5.5 mm size calculi within. Gall bladder wall is mildly thickened. Dependent echogenic sludge is also noted within.

PANCREAS: is normal in size and echotexture. Portal vein & CBD are normal in diameter.

SPLEEN: is normal in size (9.8 cms) & echotexture. No evidence of any focal lesion.

KIDNEYS: Right kidney - 10.9 cm Left kidney - 11.0 cm

Simple cortical cyst measuring 1.2 cm is seen in interpolar region of right kidney.

Both kidneys are normal in size and echotexture. Corticomedullary differentiation is normal. No evidence of focal lesion, calculus or hydronephrosis.

Urinary Bladder is adequately distended. Wall thickness is normal. No calculi or mass.

Uterus is anteverted bulky in size. It measures 8.4 x 4.4 x 5.5 cms (Volume 100cc) in length, anteroposterior and transverse dimensions. Endometrium is thickened measuring upto 2.6 cm with multiple cystic areas within.

Bilateral ovaries are unremarkable.

IVC, aorta are normal. No paraaortic lymphadenopathy.

No ascites. No pleural effusion.

IMPRESSION:
• Hepatomegaly with Grade-I fatty liver
• Over distended gall bladder with gall stones and thickened GB wall; Suggest CBC and LFT correlation
• Right renal simple cortical cyst
• Bulky uterus with cystic endometrium hyperplasia
• Mild dilatation of colitis

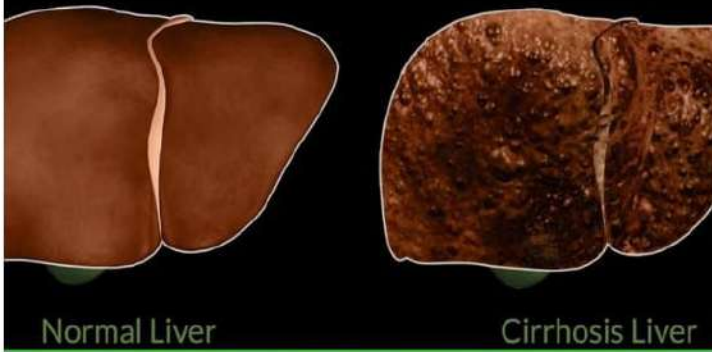
कैंसर, किडनी फेलियर, अस्पताल में गंभीर रूप से भर्ती मरिजों का उपचार, कोमा, शल्य चिकित्सा योग्य रोग, ऑटो इम्यून रोग, जीवनभर दवाई लेने वाले रोगों की रोकथाम एवं 300 प्रकार के असाध्य जटिल रोगों की चिकित्सा।

आरोग्य सुपर स्पेशलिटी मॉडर्न होमियोपेथी
कम्प्लिट, परमानेंट, ईजी, सेफ, फास्ट एण्ड कॉस्ट इफेक्टिव

102, प्रथम मंजिल, कृष्णा टॉवर, रघोस्यल हॉस्पिटल के सामने, जंजीरवाला वीरवाहा, न्यू प्लासिवा, इन्दौर म.प्र.
☎ 99075 27914 संपर्क : 0731-4977076, 79999 78894
www.homeopathycure.in. www.aarogyaahomeopathyindore.com. Email : arpitchopra23@gmail.com

किसी भी प्रकार की सर्जरी से पहले ये वीडियो जरूर देखे

Cirrhosis Of Liver

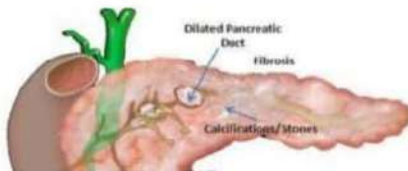


Normal Liver

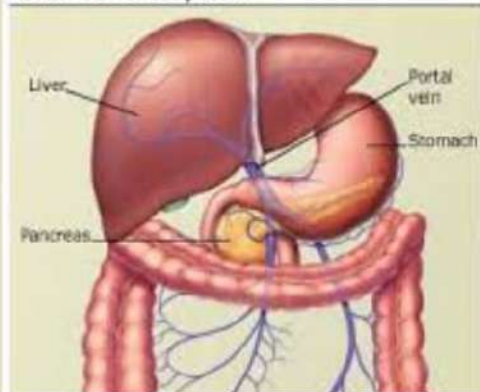
Cirrhosis Liver

CHRONIC PANCREATITIS

- ▶ Chronic pancreatitis is a continuous, prolonged, inflammatory and fibrosing process of the pancreas.
- ▶ Progressively destroyed as it is replaced with fibrotic tissue.
- ▶ Strictures and calcification may also occur in pancreas



Portal Venous System



Portal hypertension is an increase the blood pressure within a system veins called the **portal** venous system. Veins coming from the stomach, intestine, spleen, and pancreas merge into the **portal** vein, which then branches into smaller vessels and travels through the liver. Dec 21, 2018

Pt Name:- Ashwin.
Date: - 09/02/2019.
Ref. By Dr: - R.Kale, MD DM.
Ultrasonography of: - WHOLE ABDOMEN, SCREENING.
Both pleural cavities are clear
Liver- Is smaller in size with firm looking texture and slightly irregular outlines
Rt lobe liver measures 13.5 cms CC in MCL
Biliary tree undilated
No focal lesion seen
Lt portal vein normal
Rt portal vein replaced by venous collaterals
Gallbladder- Is thick walled with clear bile with venous collaterals around it
Pancreas- Is smaller in size and deformed with heterogeneous texture
No cystic area seen. CBD is 5 mms
Portal cavernoma seen at porta hepatis
Spleen- Is slightly enlarged with homogenous texture
It measures 12.7 cms in size
Kidneys- Both are normal in size, shape and texture with smooth outlines and normal calyces. Cortical thickness is normal.
Cortico-medullary differentiation is adequate
Ureters- Are normal in upper and lower third.
Bladder- Is normal, with smooth walls and nonlithiatic
Prostate- Is normal, with smooth homogenous texture
Mild clear fluid ascitis seen
Slight gastric wall oedema seen
Bowel loops are normal

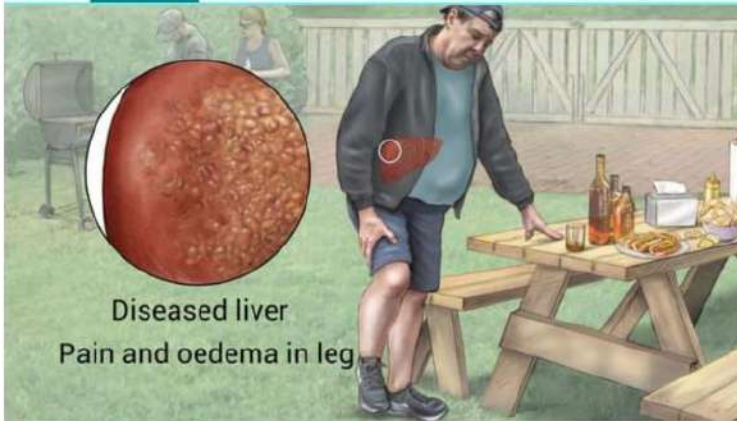Pt Name:- Mr. Ashwin Bairagi
Date: - 07/03/2019.
Ref. By Dr: - Arpit Chopra.
Ultrasonography of: - WHOLE ABDOMEN, SCREENING.
Both pleural cavities are clear.
Liver- Is smaller in size with firm looking texture.
Biliary tree and vasculature are normal.
Right lobe measures 12.6 cms cc in MCL
Right portal veins replaced by collaterals.
Gallbladder- Is normal in size, shape with smooth walls and nonlithiatic.
Pancreas- Is small and atrophied with heterogeneous texture.
No focal cyst seen
Portal cavernoma seen.
Spleen- Slightly enlarged with homogenous texture
It measures 12.5 cm in size.
Kidneys- Both are normal in size, shape and texture with smooth outlines and normal calyces. Cortical thickness is normal.
Ureters- Both are normal in upper and lower third.
Bladder- Is normal, with smooth walls and nonlithiatic
Prostate- Is normal with smooth homogenous texture.
Minimal clear fluid ascitis seen.
Bowel loops normal
RIF clear
No mass or adenopathy seen.
IMPRESSION- Chronic pancreatitis with cirrhosis liver.

Pt Name:- Mr. Ashwin.
Date: - 06/05/2019.
Ref. By Dr: - Arpit Chopra.
Ultrasonography of: - WHOLE ABDOMEN, SCREENING.
Follow up case of chronic pancreatitis
Both pleural cavities are clear
Liver- Is smaller in size with normal texture
Rt lobe liver measures 12.5 cms CC in MCL
Biliary tree is undilated
No focal lesion seen
Gallbladder- Is contracted and empty
Pancreas- Is small and atrophied with heterogeneous texture. CBD is 5 mms
Portal Cavernoma seen
Spleen- Is slightly enlarged with homogenous texture
It measures 12.1 cms in size
Kidneys- Both are normal in size, shape and texture with smooth outlines and normal calyces. Cortical thickness is normal.
Cortico-medullary differentiation is adequate
Ureters- Are normal in upper and lower third.
Bladder- Is normal, with smooth walls and nonlithiatic
Prostate- Is normal, with smooth homogenous texture
Trace of fluid in peritoneal cavity
Bowel loops are normal
RIF is clear.
No mass or adenopathy seen.
IMPRESSION- Chronic pancreatitis

Cirrhosis of the liver

Also called: hepatic cirrhosis

OVERVIEW SYMPTOMS TREATMENTS



Chronic liver damage from a variety of causes leading to scarring and liver failure.

Common

More than 1 million cases per year (India)

Treatment can help, but this condition can't be cured

Arpit Chopra (Jain)
MOEOPATHY
CAL CASE SPECIALIST
14367

102, First Floor, Krishna Tower
In front of Curewell Hospital
Janjeer Wala Square, INDORE (M.P.)

Time : Morning 10 am To 3 pm, 5 pm to 10 pm
Sunday : 11 am to 2 pm

0731-4977076, 2532737
97130 92737, 97130-37737
79999-78894, 99075 27914
www.homoeopathy.cure.com

Name: Sunil Shrivastava Age: 30 Sex: M Date: 27/04/18
Address: Agri. Mob: Ref No: 27015

History & Present Illness: Cancer of breast, followed by RT. 2016
Chronic liver cirrhosis, partial hypertension.
Splenomegaly. Oesophageal varices with P.P.P.
HTN. 120/80.
prolonged Acids.
Hypochromic + platelets

synergyplus HOSPITAL
SYNERGY DIAGNOSTICS
U.S.G. WHOLE ABDOMEN

PT. NAME: SUNIL SHRIVASTAVA
REF BY : DR. DINESH GAIR

LIVER is contracted, nodular in outline and coarse in echotexture. No evidence of focal SOL is noted. Intrahepatic biliary radicles are not dilated. Portal vein measures 16.5 mm.

GALL-BLADDER is distended. Wall thickness is mildly increased circumferentially. No evidence of calculus is noted. CBD is not dilated.

SPLEEN is mildly enlarged in size (13 cm in span) and heterogeneous in echotexture. No evidence of focal parenchymal lesion is seen.

PANCREAS is normal in size and echotexture. Main pancreatic duct is not dilated.

BOTH KIDNEYS are normal in size, shape, position & echogenicity. Cortico-medullary differentiation is well maintained. No evidence of calculus or hydronephrosis is noted.

URINARY BLADDER is empty.

Paraortic region could not be evaluated.

There is mild to moderate clear ascites.

The stomach, duodenum & jejunal loops are distended with echogenic fluid and dilated. The jejunal loops measure upto 6 cms in diameter. The distal small bowel loops are collapsed.

IMPRESSION:-
ULTRASOUND FINDINGS REVEAL CHRONIC LIVER PARENCHYMAL DISEASE WITH PORTAL HYPERTENSION

Asopa Hospital & Research Centre
Gallana Road, Off Bypass, Agra - 202 007 UP India
Ph: +91-562-2600034, 2600469, 2603339 Fax: +91-562-2623386
Cell: +91-75002 99999 e-mail: info@asopahospital.in Website: asopahospital.in

Patients Name: Mr. Sunil Kumar Singh Age: 30 Years Sex: M Date: 11/04/2018
Referred By: Self Reason for Referral: Ultrasound Report

Liver *Cirrhotic changes are seen in liver. The IHBC are normal. The extrahepatic PV diameter is 13 mm.

Gall Bladder *appears normal in size and wall thickness. No calculus is seen in the lumen.

CBD *is normal in diameter. No CBD calculus is seen.

Spleen *is 14.5 cm. in length. Splenomegaly +. The Splenic vein diameter is 6 - 8 mm.

Pancreas *appears normal in size & echotexture with regular contour in its whole length. No calcification is seen. The pancreatic duct is normal in calibre. No surrounding fluid collection is seen.

Right Kidney *is normal in site and size. No renal calculus is seen. No hydronephrosis is seen.

Left Kidney *is normal in site and size. No renal calculus is seen. No hydronephrosis is seen.

Urinary Bladder *is normal in outline and capacity. The wall thickness of U.B. is normal.

*Free fluid is seen in peritoneal cavity. Ascites ++.

*No lymph node mass seen.

IMPRESSION:
1. CIRRHOTIC CHANGES IN LIVER
2. ASCITES ++.
3. MILD SPLEENOMEGALY +.

DR P K TEWARI MBBS, DMRE
CERTIFICATE IN DIAGNOSTIC ULTRASONOGRAPHY, VIENNA, AUSTRIA
CONSULTANT RADIOLOGIST & ULTRASONOLOGIST
REGISTRATION # 17753 (UPMCA)

SAVE THE GIRL CHILD

synergyplus HOSPITAL
SYNERGY DIAGNOSTICS
STOMACH IS WELL DISTENDED WITH CONTRAST AND APPEARS NORMAL IN SIZE AND WALL THICKNESS. REST OF THE BOWEL LOOPS ARE DISTENDED WITH CONTRAST AND APPEAR NORMAL. NO SIGNIFICANT MESENTERIC LYMPHADENOPATHY IS NOTED.

URINARY BLADDER IS PARTIALLY DISTENDED. WALL THICKNESS IS NORMAL. NO CALCULUS IS NOTED. PROSTATE IS NORMAL IN SIZE, SHAPE AND ATTENUATION.

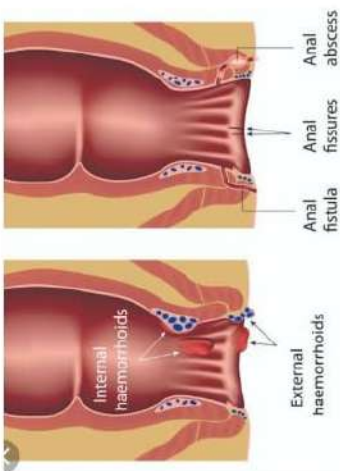
REST OF THE ABDOMINAL WALL MUSCULATURE AND FAT PLANES APPEAR NORMAL. PELVIC MUSCULATURE AND VASCULATURE APPEAR NORMAL. THERE IS NO PELVIC LYMPHADENOPATHY.

VISUALISED SPINE REVEALS DEGENERATIVE CHANGES.
VISUALISED BASAL LUNGS DO NOT REVEAL ANY FOCAL PARENCHYMAL LESION.

IMPRESSION:-
CT SCAN FINDINGS REVEAL CHRONIC LIVER PARENCHYMAL DISEASE WITH PORTAL HYPERTENSION AND ASSOCIATED KOCH'S ABDOMEN.

ADV: CLINICO-PATHOLOGICAL CORRELATION & ASCITIC FLUID EXAMINATION.

DR. A.K. ARORA (MD)



Anal fistula

OVERVIEW SYMPTOMS TREATMENTS

Large intestine

Infected tunnel (anal fistula)

An infected tunnel between the skin and the anus

Rare
Fewer than 1 million cases per year (India)

Treatable by a medical professional

Hemorrhoids

Also called piles

OVERVIEW SYMPTOMS TREATMENTS

Swollen and inflamed veins

Swollen and inflamed veins in the rectum and anus that cause discomfort and bleeding.

Anal fissure

Also called anal ulcer

OVERVIEW SYMPTOMS TREATMENTS

Small tear in the lining of the anus

Constipation, bleeding, pain

A small tear in the lining of the anus.

Very common

More than 10 million cases per year (India)

Treatable by a medical professional

Common

More than 1 million cases per year (India)

Treatable by a medical professional

09 (Piles) Tuesday

मेरे दोस्त रमेश ने मुझे बताया कि उनके पास एक बहुत बड़ा और दर्दनाक समस्या है। उन्होंने कहा कि वे बहुत लंबे समय से डॉक्टरों से मिल रहे हैं, लेकिन कुछ भी काम नहीं आया है। मैंने उन्हें बताया कि मैंने एक विशेष चिकित्सा विधि सीखी है, जो बहुत ही प्रभावी है। मैंने उन्हें बताया कि मैंने एक विशेष चिकित्सा विधि सीखी है, जो बहुत ही प्रभावी है। मैंने उन्हें बताया कि मैंने एक विशेष चिकित्सा विधि सीखी है, जो बहुत ही प्रभावी है।

Dr. Arpit Chopra (Jain)

16 Piles

मेरे दोस्त रमेश ने मुझे बताया कि उनके पास एक बहुत बड़ा और दर्दनाक समस्या है। उन्होंने कहा कि वे बहुत लंबे समय से डॉक्टरों से मिल रहे हैं, लेकिन कुछ भी काम नहीं आया है। मैंने उन्हें बताया कि मैंने एक विशेष चिकित्सा विधि सीखी है, जो बहुत ही प्रभावी है। मैंने उन्हें बताया कि मैंने एक विशेष चिकित्सा विधि सीखी है, जो बहुत ही प्रभावी है। मैंने उन्हें बताया कि मैंने एक विशेष चिकित्सा विधि सीखी है, जो बहुत ही प्रभावी है।

Dr. Arpit Chopra (Jain)

25 PILES, आजीवन

मेरे दोस्त रमेश ने मुझे बताया कि उनके पास एक बहुत बड़ा और दर्दनाक समस्या है। उन्होंने कहा कि वे बहुत लंबे समय से डॉक्टरों से मिल रहे हैं, लेकिन कुछ भी काम नहीं आया है। मैंने उन्हें बताया कि मैंने एक विशेष चिकित्सा विधि सीखी है, जो बहुत ही प्रभावी है। मैंने उन्हें बताया कि मैंने एक विशेष चिकित्सा विधि सीखी है, जो बहुत ही प्रभावी है। मैंने उन्हें बताया कि मैंने एक विशेष चिकित्सा विधि सीखी है, जो बहुत ही प्रभावी है।

Dr. Arpit Chopra (Jain)

11 (Anal Fissure)

मेरे दोस्त रमेश ने मुझे बताया कि उनके पास एक बहुत बड़ा और दर्दनाक समस्या है। उन्होंने कहा कि वे बहुत लंबे समय से डॉक्टरों से मिल रहे हैं, लेकिन कुछ भी काम नहीं आया है। मैंने उन्हें बताया कि मैंने एक विशेष चिकित्सा विधि सीखी है, जो बहुत ही प्रभावी है। मैंने उन्हें बताया कि मैंने एक विशेष चिकित्सा विधि सीखी है, जो बहुत ही प्रभावी है। मैंने उन्हें बताया कि मैंने एक विशेष चिकित्सा विधि सीखी है, जो बहुत ही प्रभावी है।

Dr. Arpit Chopra (Jain)

Bleeding Piles परामर्श

01

मेरे दोस्त रमेश ने मुझे बताया कि उनके पास एक बहुत बड़ा और दर्दनाक समस्या है। उन्होंने कहा कि वे बहुत लंबे समय से डॉक्टरों से मिल रहे हैं, लेकिन कुछ भी काम नहीं आया है। मैंने उन्हें बताया कि मैंने एक विशेष चिकित्सा विधि सीखी है, जो बहुत ही प्रभावी है। मैंने उन्हें बताया कि मैंने एक विशेष चिकित्सा विधि सीखी है, जो बहुत ही प्रभावी है। मैंने उन्हें बताया कि मैंने एक विशेष चिकित्सा विधि सीखी है, जो बहुत ही प्रभावी है।

Dr. Arpit Chopra (Jain)

A PILES February 2016 Wednesday

Name: Gaurav Sharma
Mob. No. 9819030322

17

I am Gaurav Sharma suffering from anal bleeding during stool movement. I had consulted Dr. Arpit Chopra, M.D. Modern Homoeopathy from Dr. Arpit Chopra, M.D. Modern Homoeopathy. After a week of treatment, I feel completely alright. Thank you to Dr. Arpit Chopra for the Modern Homoeopathy treatment from Dr. Arpit Chopra.

Dr. Arpit Chopra (Jain)

Contact Record PILES

Company: [Blank] Office: [Blank]

Address: [Blank] Pin: [Blank]

Name: [Blank] Home: [Blank]

Designation: [Blank] Mobile: [Blank]

Date: [Blank] Topic: [Blank] Response: [Blank]

I have Piles problem and after Piles Piles it is not so common it is hell for me now it is good & the Piles is also solved.

Anal Fissure February 2016 Monday

15

मेरे दोस्त रमेश ने मुझे बताया कि उनके पास एक बहुत बड़ा और दर्दनाक समस्या है। उन्होंने कहा कि वे बहुत लंबे समय से डॉक्टरों से मिल रहे हैं, लेकिन कुछ भी काम नहीं आया है। मैंने उन्हें बताया कि मैंने एक विशेष चिकित्सा विधि सीखी है, जो बहुत ही प्रभावी है। मैंने उन्हें बताया कि मैंने एक विशेष चिकित्सा विधि सीखी है, जो बहुत ही प्रभावी है। मैंने उन्हें बताया कि मैंने एक विशेष चिकित्सा विधि सीखी है, जो बहुत ही प्रभावी है।

Dr. Arpit Chopra (Jain)

PILES January 2016 Wednesday

Name: Beant Singh
Mob. No. 9819030322

22

I was suffering from piles problem since it is a half year, but after taking treatment from here, it was totally finished within 2 months only. I am glad that I found a good clinic. Now I can eat any type of food without any problem just because of Dr. Arpit.

Thank a lot sir

Dr. Arpit Chopra (Jain)

Piles (Hemorrhoid) Saturday

14

मेरे दोस्त रमेश ने मुझे बताया कि उनके पास एक बहुत बड़ा और दर्दनाक समस्या है। उन्होंने कहा कि वे बहुत लंबे समय से डॉक्टरों से मिल रहे हैं, लेकिन कुछ भी काम नहीं आया है। मैंने उन्हें बताया कि मैंने एक विशेष चिकित्सा विधि सीखी है, जो बहुत ही प्रभावी है। मैंने उन्हें बताया कि मैंने एक विशेष चिकित्सा विधि सीखी है, जो बहुत ही प्रभावी है। मैंने उन्हें बताया कि मैंने एक विशेष चिकित्सा विधि सीखी है, जो बहुत ही प्रभावी है।

Dr. Arpit Chopra (Jain)

PILES Complaints

14

मेरे दोस्त रमेश ने मुझे बताया कि उनके पास एक बहुत बड़ा और दर्दनाक समस्या है। उन्होंने कहा कि वे बहुत लंबे समय से डॉक्टरों से मिल रहे हैं, लेकिन कुछ भी काम नहीं आया है। मैंने उन्हें बताया कि मैंने एक विशेष चिकित्सा विधि सीखी है, जो बहुत ही प्रभावी है। मैंने उन्हें बताया कि मैंने एक विशेष चिकित्सा विधि सीखी है, जो बहुत ही प्रभावी है। मैंने उन्हें बताया कि मैंने एक विशेष चिकित्सा विधि सीखी है, जो बहुत ही प्रभावी है।

Dr. Arpit Chopra (Jain)

PILES February 2016 Friday

05

मेरे दोस्त रमेश ने मुझे बताया कि उनके पास एक बहुत बड़ा और दर्दनाक समस्या है। उन्होंने कहा कि वे बहुत लंबे समय से डॉक्टरों से मिल रहे हैं, लेकिन कुछ भी काम नहीं आया है। मैंने उन्हें बताया कि मैंने एक विशेष चिकित्सा विधि सीखी है, जो बहुत ही प्रभावी है। मैंने उन्हें बताया कि मैंने एक विशेष चिकित्सा विधि सीखी है, जो बहुत ही प्रभावी है। मैंने उन्हें बताया कि मैंने एक विशेष चिकित्सा विधि सीखी है, जो बहुत ही प्रभावी है।

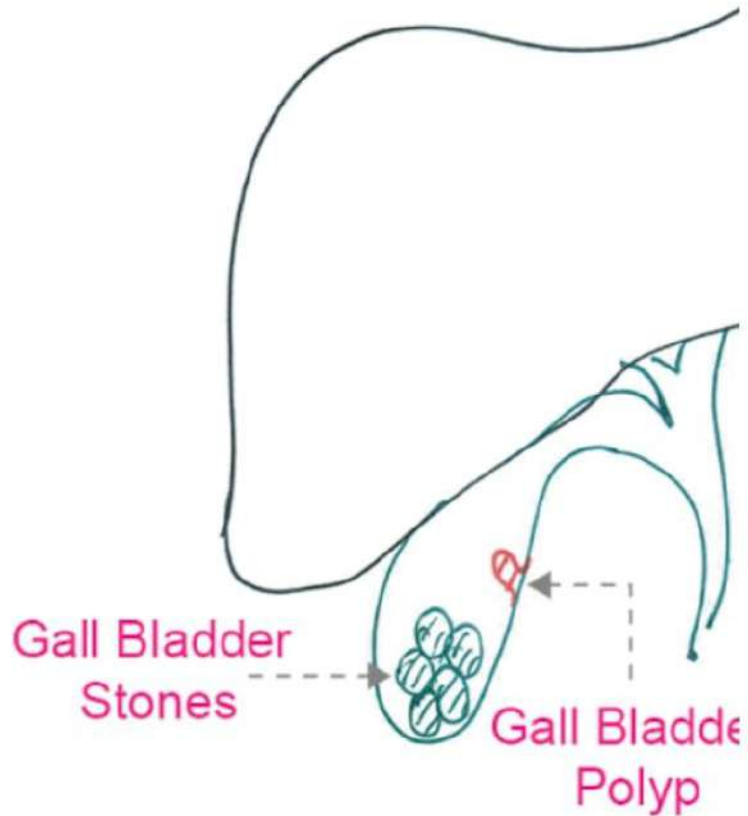
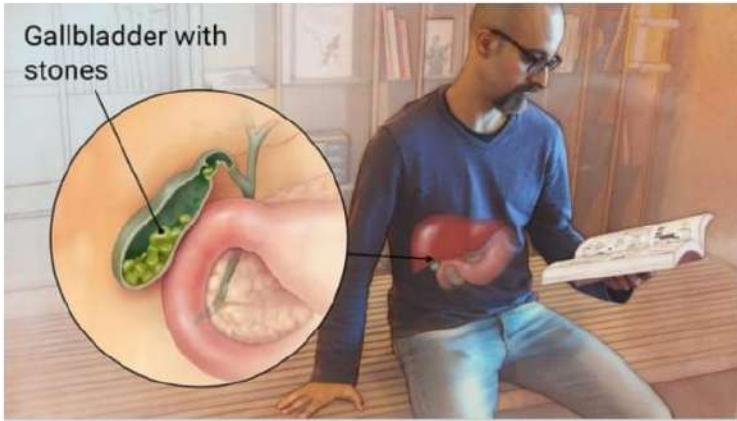
Dr. Arpit Chopra (Jain)

PILES/Hemorrhoid (आजीवन) Monday

29

मेरे दोस्त रमेश ने मुझे बताया कि उनके पास एक बहुत बड़ा और दर्दनाक समस्या है। उन्होंने कहा कि वे बहुत लंबे समय से डॉक्टरों से मिल रहे हैं, लेकिन कुछ भी काम नहीं आया है। मैंने उन्हें बताया कि मैंने एक विशेष चिकित्सा विधि सीखी है, जो बहुत ही प्रभावी है। मैंने उन्हें बताया कि मैंने एक विशेष चिकित्सा विधि सीखी है, जो बहुत ही प्रभावी है। मैंने उन्हें बताया कि मैंने एक विशेष चिकित्सा विधि सीखी है, जो बहुत ही प्रभावी है।

Dr. Arpit Chopra (Jain)



A hardened deposit within the fluid in the gallbladder, a small organ under the liver.

Very common

More than 10 million cases per year (India)

- Treatable by a medical professional
- Requires a medical diagnosis
- Lab tests or imaging always required
- Chronic: can last for years or be lifelong

Aman Diagnostic's

ISO 9001:2015 Certified Laboratory

Pt. Name: **MRS. NEHA SHAIKH** Age/Sex: **26 Years /Female**
 Ref. By: **DR. ARVIND PATIDAR** Date: **31/May/2018**

USG WHOLE ABDOMEN
 Liver is normal in size (11.6 cm) and shape. Its echogenicity is normal. Margins are smooth and regular. The portal vein and biliary radicals are normal in calibre.

GB shows small 4.1 mm hypochoic lesion in its lumen ? Small calculus ? Polyp. Wall thickness is normal. CBD is within normal limits.
 Pancreas is normal in size, shape and echo pattern.
 Spleen is normal in size (10.1cm) and echo pattern.

Rt. Kidney: 9.2 x 3.7 cm Lt. Kidney: 9.1 x 3.6 cm
 Bilateral kidneys are normal in shape, size and echo texture. CM differentiation is maintained.

Urinary bladder is normally distended with normal wall thickness.

Uterus is anteverted normal size (8.4x 2.3 x 4.8 cm). Shape & contour maintained. Myometrial echo texture is normal. Endometrium is 8.4 mm in thickness. **Small amount of fluid seen in Pouch of Douglas.**

Both ovaries are normal in shape, size and echo texture.

No evidence of ascites / significant lymphadenopathy.

**Impression: 1. ? Small GB calculus ? Polyp.
 2. Small amount of fluid seen in POD.**

Adv: clinicopathological correlation & follow-up scan after 1-2 mths

Important: using technical & biological limitations in case of any error in any study. The doctor cannot be held responsible for claim of damages of any nature and this report is not valid for any medico-legal aspect.

Dr. Amit Shankhwar MD Radiologist (Indore)
 Dr. Sunil Ahirwar MD Microbiologist (Indore)
 Dr. Vivek Khare MD Pathologist (Bhopal)
 Dr. Shikha Ghanghoria MD Surgical Pathologist Fellow Tata Memorial Hospital, Mumbai. Asst. Professor NCM Medical College, M.Y. Hospital & Cancer Hospital, Indore

Main Branch : 151-FB, 5th. No. 94, Piplyahana Circle, Ring Road, INDORE (M.P.) Ph. : 0731 2970466

ISPL Cert DAC C8-022-MS

SHRISHA MALIK EC II

Shri Sai Baba Hospital & Research Centre

Patient's Name: **MISS NEHA D/O HARUN** Age/Sex: **26 / Female**
 Consultant Dr. **ARVIND PATIDAR** Date: **27/02/2015 / 68140**

WHOLE ABDOMEN (F) SONOGRAPHY

Liver, Spleen, Pancreas are normal in size, shape & echotexture. Biliary channels are normal.

C.B.D., Portal vein, major vessels are normal in calibre

Gallbladder is thin-walled with echofree lumen.

Both kidneys are normal in size, shape & echotexture. Corticomedullary differentiation is maintained.

Both ureters are unobstructed.

Urinary bladder is thin-walled with echofree lumen.

Uterus is anteverted normal in size measures 7.9 x 3.9 x 2.9 cm. Myometrium is homogeneous in echotexture.

Endometrial echo reflection is 10.8 mm

Both ovaries are normal in size & echopattern.

No ascites seen.

IC junction is pulled up in position.

Mild bowel wall thickening is seen involving approx 5 cm length of distal ileum with few small surrounding mesenteric lymph nodes. Needs lab correlation to rule out possibility of Koch's etiology.

Dr. Shilpa Barola Jain DNB, RD

All imaging studies have technical and biological limitations. Please correlate clinically as well as with other investigations findings. A review should be requested in case of discrepancy. This report is not valid for medico-legal purpose.

CHHATRI BAGH INDORE ☎ : 0731-2341790, 2343772

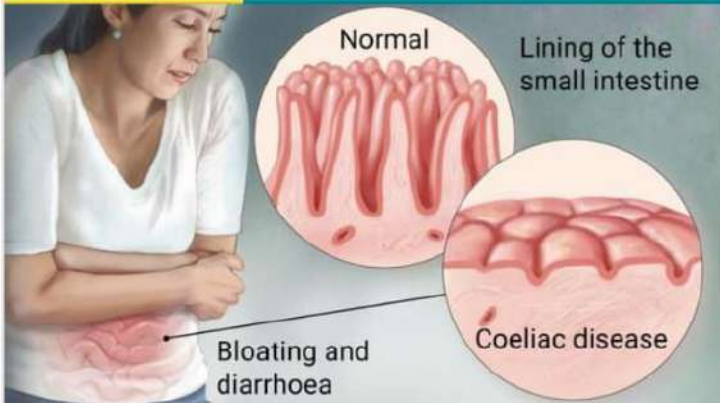
Report is not valid for Medico legal purposes

Celiac disease

ABOUT

SYMPTOMS

TREATMENTS



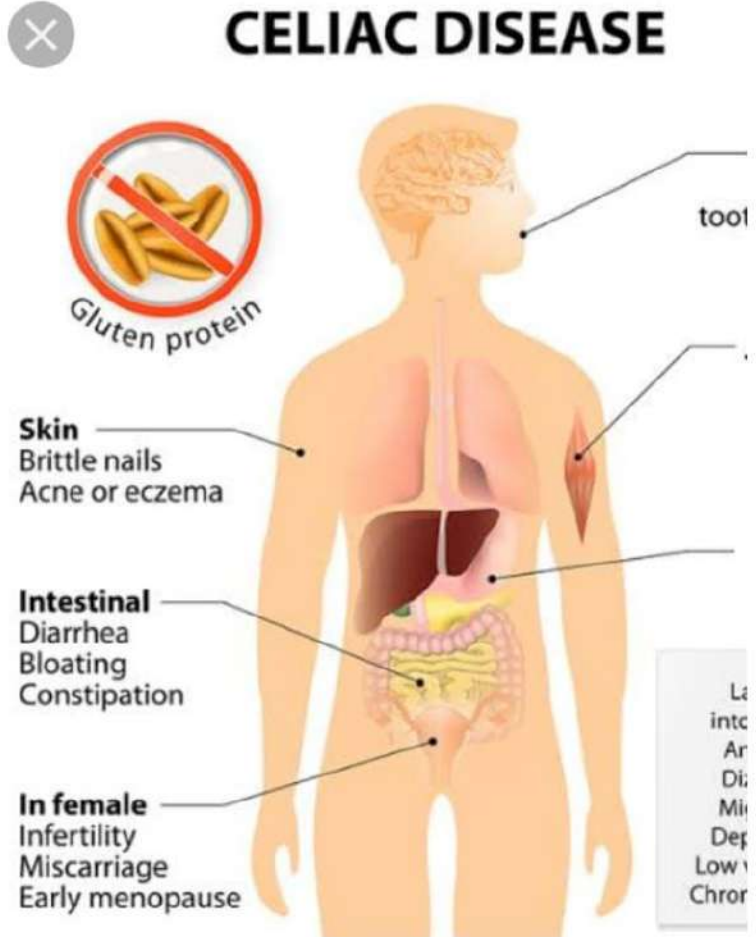
An immune reaction to eating gluten, a protein found in wheat, barley and rye.

Common

More than 1 million cases per year (India)

Treatment can help, but this condition can't be cured

CELIAC DISEASE



Central lab
Central India's First and Largest Super-specialty reference laboratory
For Feedback / Home Collection Call 786-99999-37 / 33

Charitable Centre- CC111

Name: VIBHI SEKSARIYA
Referred By: DR. ARPIT CHOPRA
Drawn On: 29-Apr-2018 10:17
Accession No.: 1804121632

Age: 8 Years
Sex: Female
Received On: 29-Apr-2018 10:20
Print Date: 04-May-2018 10:40

Parameter	Result	Unit	Biological Reference Interval
tTG-Tissue transglutaminase-IgA by E.I.A.			
tTG-Tissue transglutaminase-IgA by E.I.A.	6.571 (POSITIVE)	RATIO	CUT OFF 0.573

Comments:
This test is used for the determination of IgA autoantibodies to human tissue transglutaminase for the differential diagnosis of celiac disease / gluten sensitive enteropathy (GSE). Celiac disease is characterized by small intestinal villi atrophy. Tissue transglutaminase is one of the main immunogenic substrates that can be easily detected for the diagnosis of celiac disease. Other recommended tests are Endomorphin, Gliadin & Retriculin antibodies along with small intestinal biopsy. Negative serology does not exclude a diagnosis of GSE. IgA deficiency should be considered in patients with suggestive clinical presentation.

* Not in Scope of NABL

End Of Report

This is an electronically authenticated report.
Report ID: 102025
Generated On: 04-05-2018

Approved by: Dr. Salish Joshi
Approved On: 29-04-2018

Central lab
Central India's First and Largest Super-specialty reference laboratory
For Feedback / Home Collection Call 786-99999-37 / 33

Labre OPD

Name: Vibhi Seksariya
Age: 9 Years
Sex: Female

Referred By: [Blank]
Received On: 13-Mar-2019 14:34

Drawn On: 13-Mar-2019 14:34
Print Date: 20-Mar-2019 17:39

Accession No.: 19031108183
Reference: Dr. Arpit Chopra

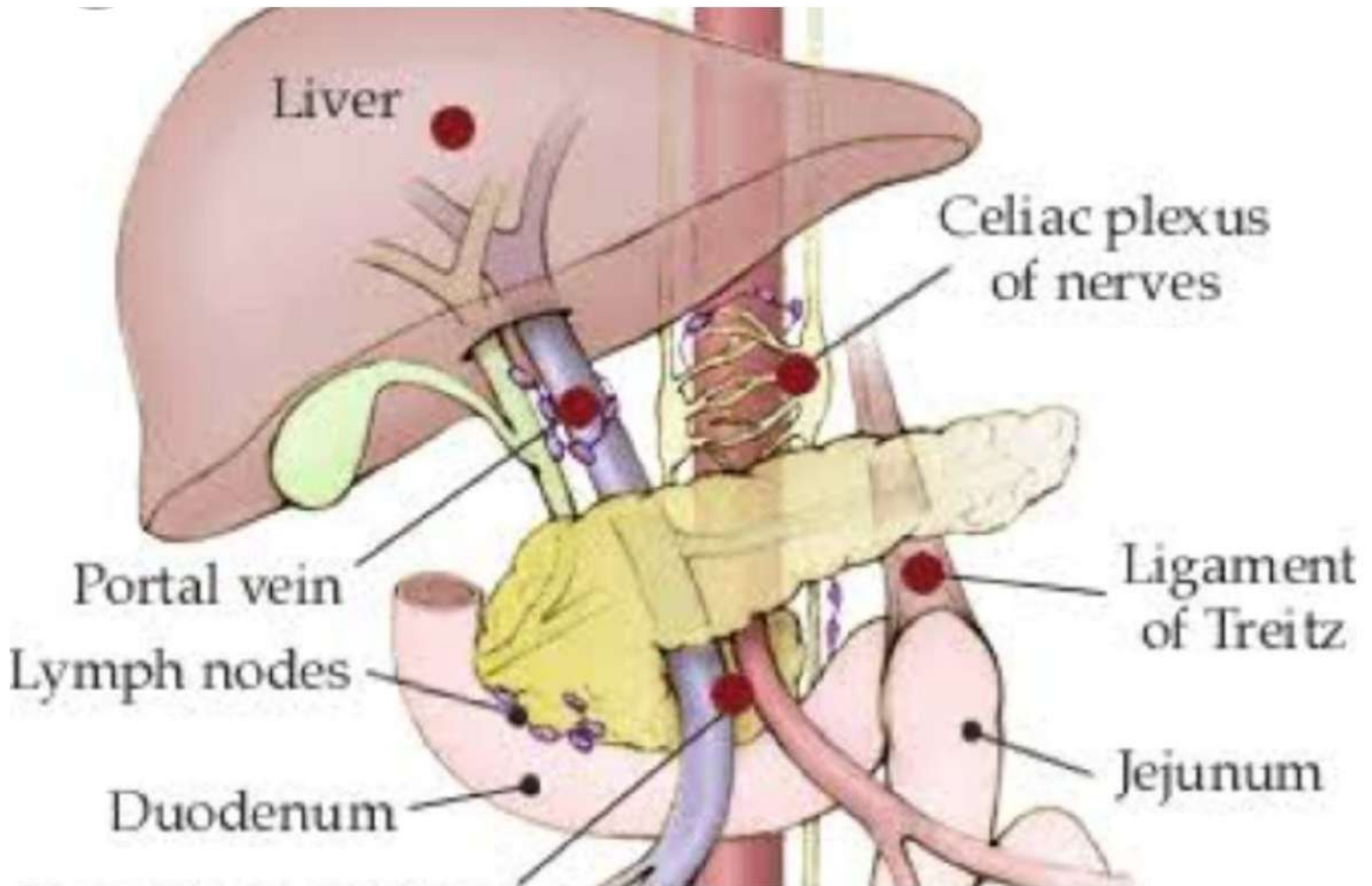
Parameter	Result	Unit	Biological Reference Interval
C - REACTIVE PROTEIN (QUANTITATIVE)			
CRP Quantitative	0.05	mg/dL	0.0 - 1.0
ESR			
ESR (Westergren)	22	mm	1 - 20
*Normal ESR does not exclude active disease. ESR increases with age, and is raised in pregnancy and in anemia; mild to moderate elevations should be interpreted with caution. It is increased in acute and chronic inflammatory disease and in neoplastic disease. ESR may be very high (>200 mm in 1 hour) in multiple myeloma, tuberculosis, and temporal arteritis. Low ESR is seen in hypothyroidism, sickle cell disease, iron deficiency, and in the first 3 days after myocardial infarction.			
tTG-Tissue transglutaminase-IgA by E.I.A.			
tTG-Tissue transglutaminase-IgA by E.I.A.	0.153 (NEGATIVE)	RATIO	CUT OFF 0.286

Comments:
This test is used for the determination of IgA autoantibodies to human tissue transglutaminase for the differential diagnosis of celiac disease / gluten sensitive enteropathy (GSE). Celiac disease is characterized by small intestinal villi atrophy. Tissue transglutaminase is one of the main immunogenic substrates that can be easily detected for the diagnosis of celiac disease. Other recommended tests are Endomorphin, Gliadin & Retriculin antibodies along with small intestinal biopsy. Negative serology does not exclude a diagnosis of GSE. IgA deficiency should be considered in patients with suggestive clinical presentation.

* Not in Scope of NABL

This is an electronically authenticated report.
Report ID: 846686747055
Generated On: 26-03-2019

Approved by: Dr. Salish Joshi
Approved On: 13-03-2019



SODANI DIAGNOSTIC CLINIC
 HO.: L.G.-1, Morya Centre, Opp. Basket Ball Club, 16/1, Race Course Road, Indore (M.P.)
 Phone : 0731 - 4766222, © 9617770150

Pt's Name : Mr. Niranjn Wakde
 Age : 50 Years / MALE
 By : Dr. Jain Sunil (Amol Hosp) MD(Gastro)
 NA

Visit Id : 1018065715
 Reg Date : 02/08/2018
 Reported : 02/08/2018 14:19

WHOLE ABDOMEN SONOGRAPHY
 Hepatic contour is smooth & span (13.8 cm) is normal. Parenchymal echotexture is normal. No focal lesion is seen. Intrahepatic biliary radicles are undilated.

Gall bladder is normally distended. Walls are thin. No sludge & calculi seen. No peri GB collection is noted.

Portal vein & CBD are normal in caliber.
Few (2-3) enlarged non-necrotic lymphnodes are seen at porta, largest of them measures 1.8 x 0.7 cm.

Pancreas is normal in shape & size. Parenchymal echoes are normal. Pancreatic duct is undilated.

Spleen is normal (11.1 cm). No focal lesion seen.

Both kidneys are normal in position & size. Right kidney is 9.7 x 3.4 cm & left is 10.3 x 4.3 cm in size. Cortical echoes are normal. Pelvicalyceal system is undilated. Both ureters are undilated. No calculi seen at PUJ & UVJ.

Urinary bladder is distended, shows normal walls & echofree lumen. No intra luminal lesion or calculi seen.

Prostate is normal in size. It measures 1.9 x 4.6 x 3.1 cm (vol. = 15 cc).

Minimal free fluid is seen at RIF.
 No significant bowel wall thickening / dilatation noted.
 A 5.9 mm diameter appendix is seen at RIF, however no acute inflammatory changes are seen at present scan.

Impression:
 - No hepatobiliary lesion seen.
 - Normal renal echotomography with undilated collecting system.
 - **Few mildly enlarged non-necrotic lymphnodes at porta? non specific.**
 - Minimal free fluid at RIF.
 Clinical correlation / followup suggested

DR. HITIN JADHAV
 DMRD DNS

Centre Address:- Morya Centre, 16/1, Race Course Road, Indore
 Printed on : 02/08/2018 14:00
 Authenticated by : SONICHACKO

Samarpan Imaging Solutions

Pt. Name: MR. NIRANJAN WAKDE
 Ref. By: DR ARPIT CHOPRA MD
 Age/Sex: 50 Years /Male
 Date: 23-Dec-2018

WHOLE ABDOMEN SONOGRAPHY
 Hepatic contour is smooth & span (15.3 cm) is normal. Parenchymal echotexture is normal. No focal lesion is seen. Intrahepatic biliary radicles are undilated.

Gall bladder is normally distended. Walls are thin. No sludge or calculus is seen.
 CBD & Portal vein are normal in caliber.

Visualized part of Pancreas is normal in shape & size. Parenchymal echoes are normal. Pancreatic duct is undilated.

Spleen is normal (10.9 cm). No focal lesion seen.

Both kidneys are normal in position & size. Renal contour is smooth. Cortical echoes are normal. Pelvicalyceal system is undilated.
Right kidney is 10.3 x 3.4 cm and left kidney is 10.8 x 3.7 cm in size.

Urinary bladder shows normal walls & echo free lumen.
Pre-void urine = 471 ml (approx), post-void residual urine nil.
 Prostate is normal (weight 22.9 grams). Seminal vesicles are normal.

No significant retroperitoneal lymphadenopathy seen.
 No free fluid seen in peritoneal cavity.
 The dependent pleural recess are normal.

IMPRESSION:- ESSENTIALLY NORMAL USG FINDINGS.

Clinical correlation.

DR. PRIYAL CHOUHAN,
 RADIOLOGIST
 REG. NO. MP-19601

समर्पण इमेजिंग सल्यूशन्स


09:00 मैं गैर-उसिद आरक्षण निवादी उपकरण को
 10:00 लगाया 4 माह के पिछले की समस्या थी
 मुझे बहुत बुरा (पास) रहे, मुझे पल्लव दानी थी।
 11:00 मैं लगाया 8 सप्तरों का (रिनाथ) था। सभी
 12:00 को मुझे आपरेशन की सलाह दी थी। मुझे
 आपरेशन नहीं करवाना था क्योंकि लगाया
 13:00 12 वर्ष के पहले मुझे आपरेशन करवा चुका था।
 परन्तु जब मैं चापस/काष्ठ के मिला, तब 3-4
 14:00 मुझे निरवाक दिनाथा की वो मुझे निरा आपरेशन
 की गीन कर रहे। आर 3-4 महीने मुझे 10 दिन
 15:00 पूरा रूप से गीन कर दिया। मुझे लीड में मुझे
 लीडिंग के अन्धकार देता है।

16:00

11/8/18

15 Thursday 11th Week • 074-291 ANAL FISSURE MARCH 2018

मेरा नाम समराज. मुझे
~~फिसस~~ की fissure की समस्या
 थी. इस मुझे just deal ले
 डॉ. सा. का लख मिला,
 मांस में डॉ. सा. मे consult किया
 दवाई की, मुझे 15.20 दि
 में ही काफी हद तक आराम
 मिला. डॉ. सा. महीने में मे
 total relief मिला है।

शरान वान : 
 7000589312
 940745686

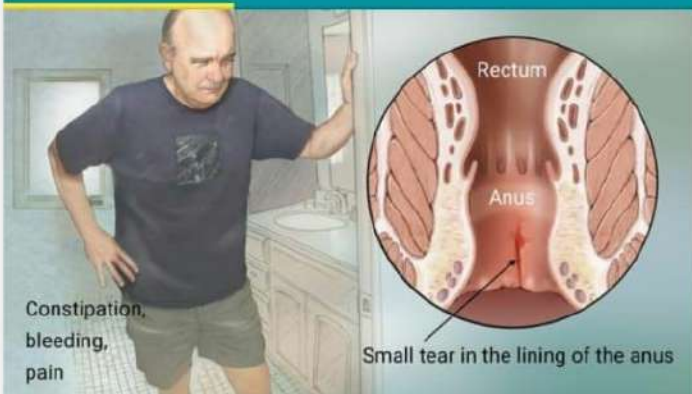
CURED

Dr. Arpit Chopra (M.D.)
 M.D. Homeopathy (Reg. No. 11351)
 AAROGYA SUPER SPECIALITY
 Modlin Hospital, 112, Phase 1, Sector 15, Gurgaon, Haryana

MAR 2018 18 19 20 21 22 23 24 25 26 27 28 29 30 31

Also called: anal crack

ABOUT SYMPTOMS TREATMENTS



Constipation, bleeding, pain

A small tear in the lining of the anus.

Common
 More than 1 million cases per year (India)

- Treatable by a medical professional
- Requires a medical diagnosis
- Lab tests or imaging rarely required

25

Saturday
34th Week • 237-128

PILES, बवासीर

AUGUST 2018

में मोटे नलक विशाकरणमा निवासी रडद्वोर
 क पुरुषों से पाइलस (बवासीर) की
 वृद्धन आनेवासी धमकीर समस्या परेशान था।
 इन पडवाषी में जगह-जगह जाकर काफा
 सारे इलाज लिड इसके बाद भी में पूरी
 वारु से ठीक नहीं हो पाया मुझे डर
 में आपुरेण करवान की सलए पिगई यी
 वष मुझे Dr. Arpit Chopra (Jain)
 के माइन होम्योपैथिक रलडिन के बारे में
 इन्टरनेट के द्वारा पता चला गया केवल
 1 दिन पिनो के अंदर मुझे कफी हद तक आराम
 मिल गया मुझे परद और खून आने की समस्या
 खण्ड हो गई और मूरसे का भी बहार नहीं
 आने ही मुझे अपनी सामान्य जीवन अनुभूती
 प्राप्त हुई बहुत - बहुत धनव्यवाप डी सलख

पता: 5058 | 185/11 अरुणायनगर
इंदौर

पुसई Mob. 9925899951
पौदालीए विगवहारा

Dr. Arpit Chopra (Jain)
 M.D. Homoeopathy (Reg. No. 14387)
AUROGYA SUPER SPECIALITY
 Homeopathic Clinic/Computerised
 AUG-14 First Floor, Krishna Tower,
 2018 19 20 21 22 23 24 25 26 27 28 29 30 31

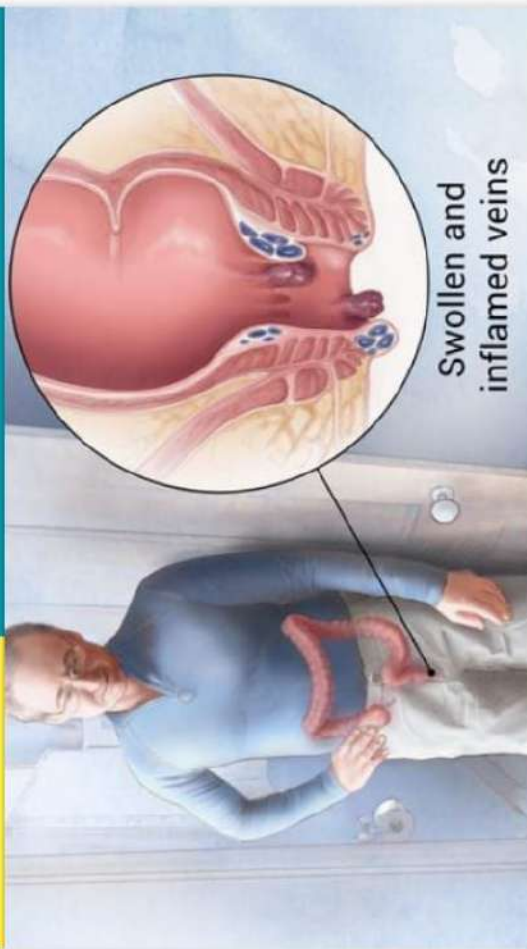
Hemorrhoids

Also called: piles

ABOUT

SYMPTOMS

TREATMENTS







Swollen and inflamed veins

Swollen and inflamed veins in the rectum and anus that cause discomfort and bleeding.

Very common

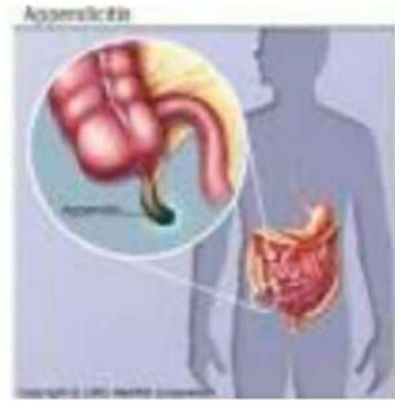More than 10 million cases per year (India)

-  Treatable by a medical professional
-  Usually self-diagnosable
-  Lab tests or imaging not required
-  Chronic: can last for years or be lifelong

THANK ♥ YOU

Modern Homoeopathy to save from Appendix surgery

26-Jan-2017 · Appendicitis is a medical emergency that almost always requires prompt surgery to remove the appendix. Left untreated, an inflamed appendix will eventually burst, or perforate, spilling infectious materials into the abdominal cavity.



Triveni Diagnostic & Research Centre

Reg. No: 178607
 Patient Name: MS. SHALINI
 Age / Sex: 14 YEARS / FEMALE
 Ref. By: Dr. PARDESH SINGH

SONOGRAPHY
USSG WHOLE ABDOMEN/FEMALE

Liver is normal in size with smooth contour and homogeneous echotexture. Intra/hepatic biliary radicles are not dilated. Portal & splenic veins are normal in caliber.

Gall bladder is normal in size with thin walls & lumen is free from calculi/gall stones & sludge. It is not dilated.

Pancreas is normal shaped with homogeneous echotexture.
 Spleen is normal in size and echotexture.

Kidneys are normal in size (Rt 11.4 X 7.4 Lt 10.6 X 7.9 cm), contour, position and show normal cortical echogenicity & CMJ. No evidence of calculus or calcification in either sides. Bilateral renal pelvis & ureters are undilated.

Urinary bladder is partially filled with anechoic contents.
 Mucosa is smooth and wall thickness measures normal.

Uterus is normal in size, contour & anterovert.
 Myometrium is homogeneous in echotexture.
 Endometrial echo is central. Cervix appears to be normal.
 Uterus Size 6.0 x 3.1 x 3.8 cm.
 Endometrium 4 mm.
 Ovaries are normal.

The appendicular lumen measures 5.7 cm diameter with mildly edematous wall & mildly inflamed surrounding mesentery. Mild probe tenderness is elicited over the region.
 There are multiple enlarged lymph nodes seen in RIF, largest measuring 23 x 7 mm.

There is moderate to gross amount of free fluid seen in pelvic cavity, more towards the right adnexa.

Kindly correlate with clinical & pathological findings.

MUKESH DUBEY DR. VIJAY SHARMA DR. T. S. SHARMA DR. P. S. SHARMA DR. SANJAY TAGI

GITA BHAWAN HOSPITAL
 Manomaganj (N. M. Vyas Marg), INDORE (M.P.)
 Phone : 4003315-16-17
 Website - gitabhawanhospital.com E-mail : gitabhawanhospital@yahoo.com

SONOGRAPHY DEPTT

PT'S NAME Mrs. Shalini Shukla
 AGE/SEX 14 yrs.F
 Date: 02/09/2018
 Ref. By Dr. Arpit Chopra

U.S.G. - WHOLE ABDOMEN

Liver is normal in size, shows normal parenchymal echotexture and contours. No evidence of focal parenchymal lesion seen.

CBD & Portal vein are normal in caliber at portal hepatics. IHBR/IHPR are undilated.

Gall Bladder is normally distended shows thin walls and anechoic lumen contents.

Spleen is 11.4cm in size & shows normal echotexture. No evidence of any focal lesion.

Pancreas is normal in size and shows normal echotexture. No evidence of any focal lesion.

Rt. Kidney is 12.2x4.0cm & Lt kidney is 11.0x4.3cm in size, show smooth contours, normal parenchymal echotexture with fair corticomedullary differentiation and compact central sinus echoes. No evidence of focal hypo/hyperechoic lesion/calculus seen.

Ureters are undilated. Both the PUJ/UJ are clear.

Urinary Bladder is normally distended shows thin walls and anechoic lumen contents.

Uterus is anteverted - 5.6x2.6x3.4cm, shows smooth contours, homogenous myometrial echotexture. No evidence of focal myometrial lesion or gest. Sac.
 Endometrial echoes are 5.6mm in thickness and centrally placed.
 Lt ovary is normal in size and echotexture. Rt ovary reveals 29x24mm functional cyst.

Small amount of free fluid noted in Pouch of Douglas / Rt lower abdomen.

There are few discrete mesenteric nodes noted upto 16x7mm in size.

No evidence of lump/inflamed appendix in RIF.

IMP: MILD HEPATOMEGALY WITH MILD ASCITIS & FEW FEW NONSPECIFIC REACTIVE NODES (16X7MM) IN RT MID LOWER ABDOMEN

SONOLOGIST
 DR. SWATI BHIDE
 M.D. R.D.

You and I are the best team of all

Anal fissure

Also called: anal ulcer



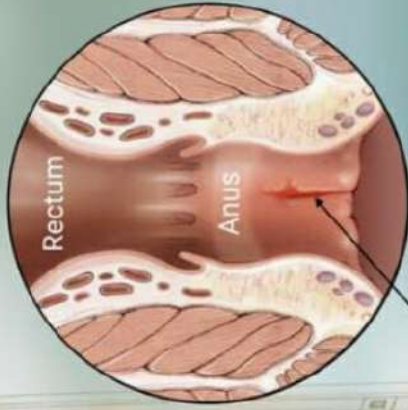
ABOUT

SYMPTOMS

TREATMENTS



Constipation, bleeding, pain



Small tear in the lining of the anus

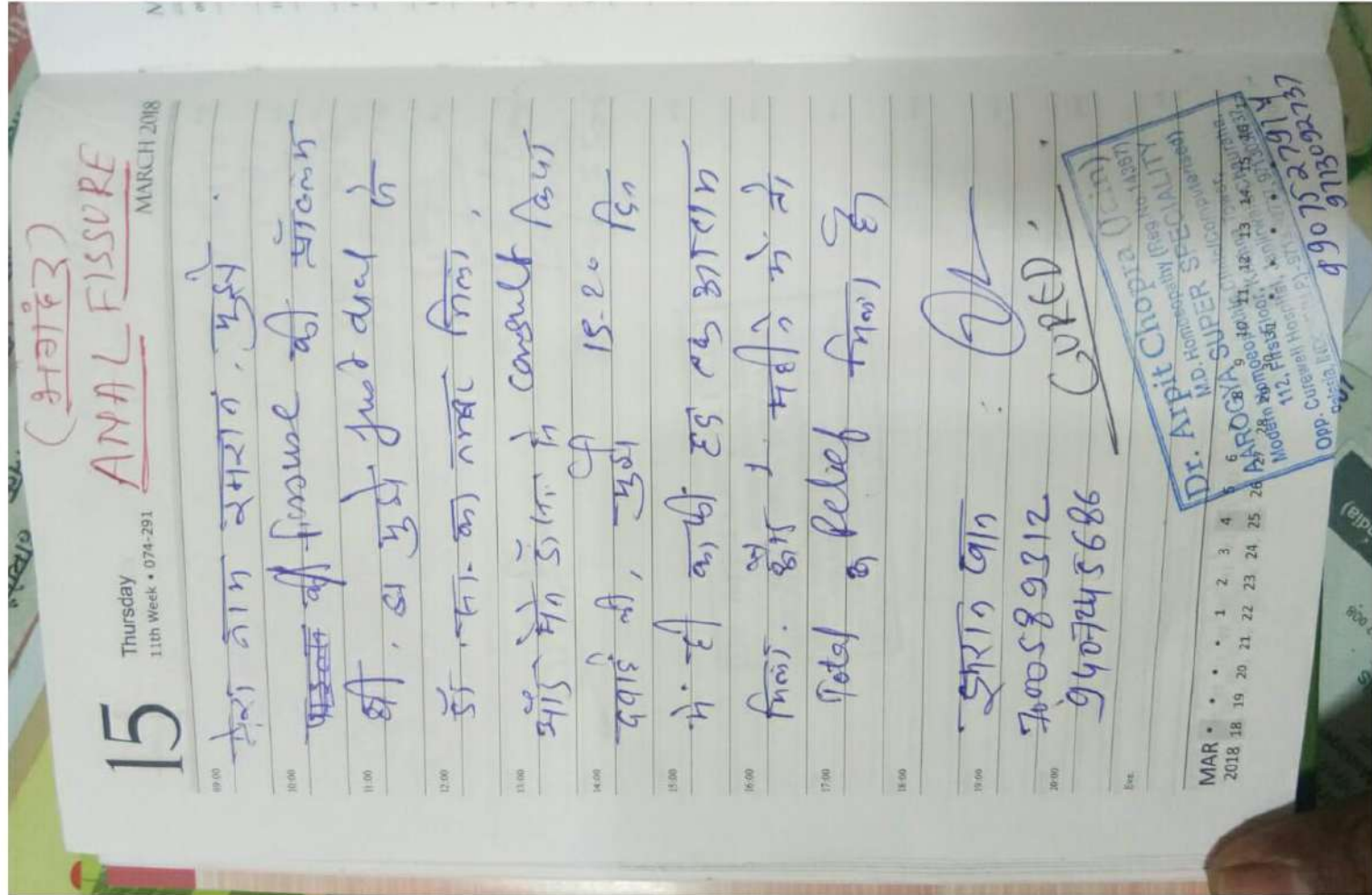
A small tear in the lining of the anus.

Common

More than 1 million cases per year (India)

- Treatable by a medical professional
- Requires a medical diagnosis
- Lab tests or imaging rarely required

Consult a doctor for medical advice



Very common

More than 10 million cases per year (India)



Treatment can help, but this condition can't be cured



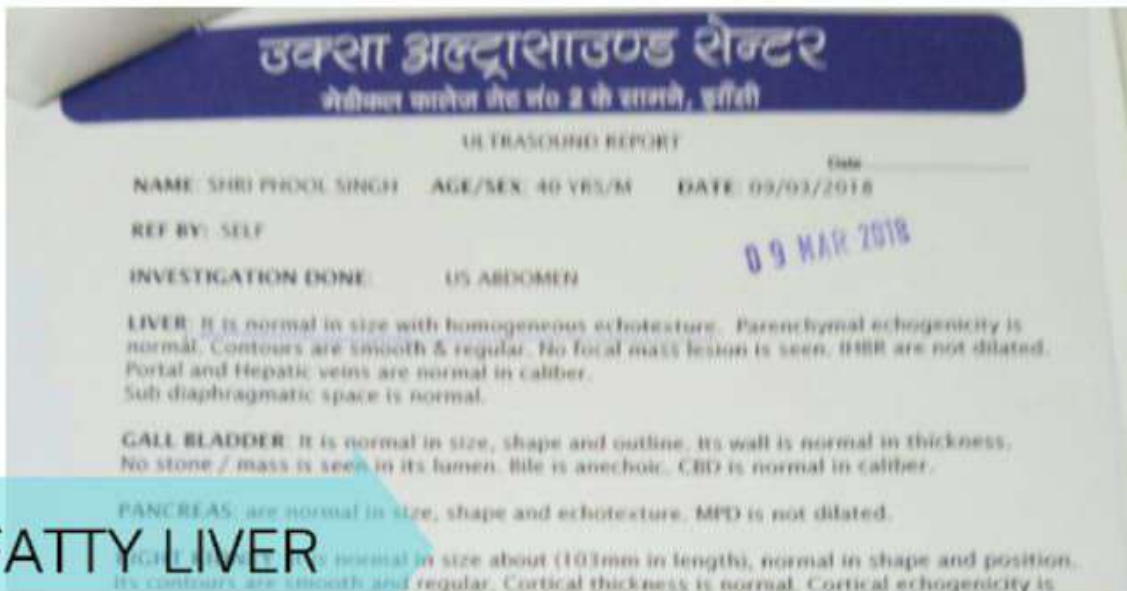
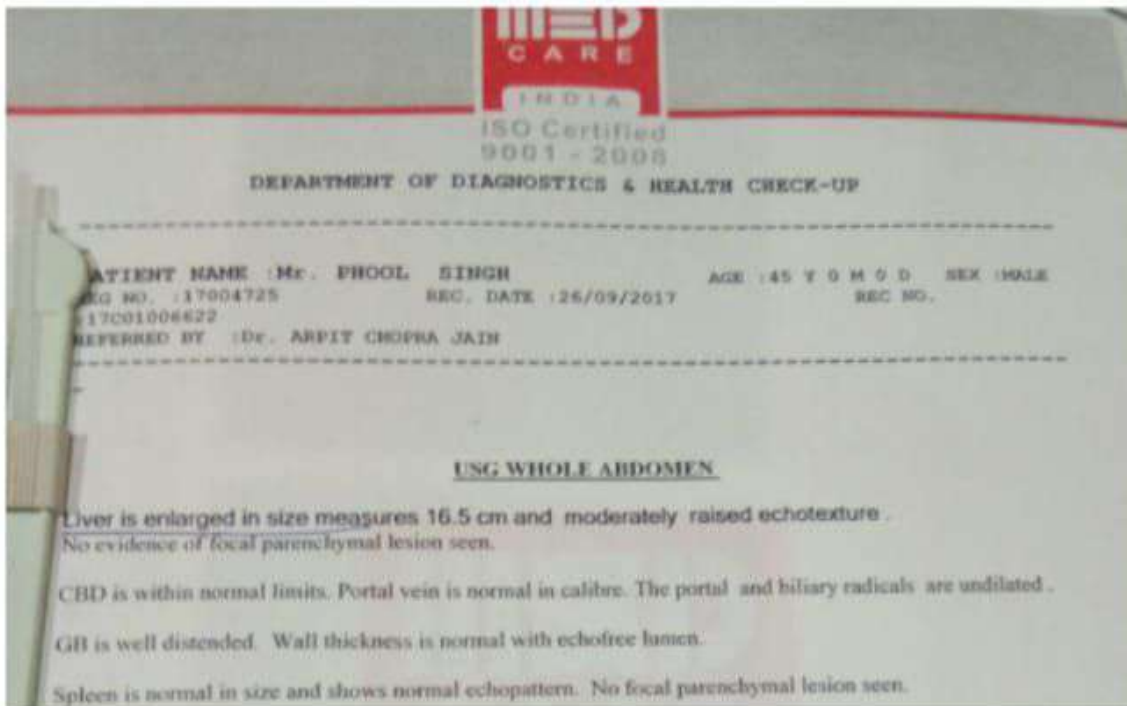
Requires a medical diagnosis



Lab tests or imaging always required



Chronic: can last for years or be lifelong



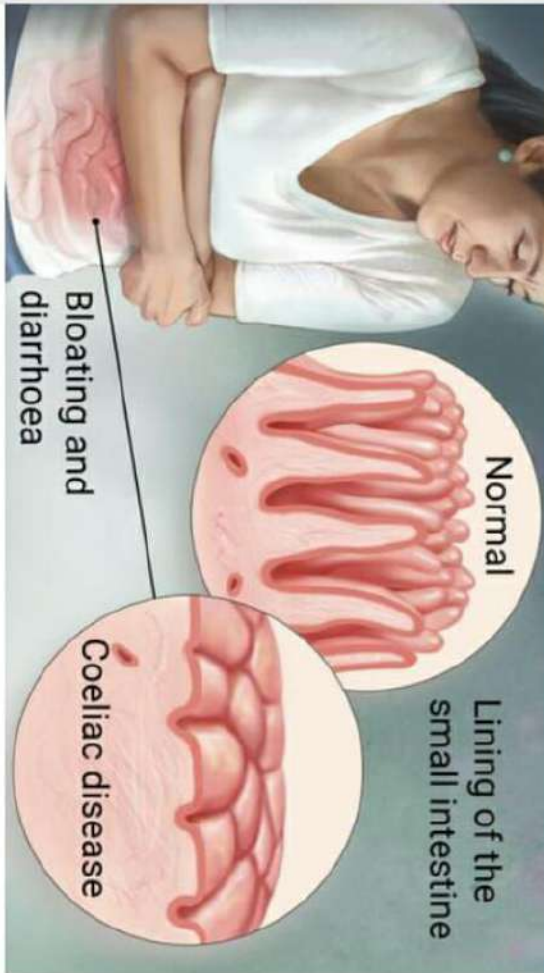
FATTY LIVER

Celiac disease

ABOUT

SYMPTOMS

TREATMENTS



An immune reaction to eating gluten, a protein found in wheat, barley and rye.

Common

More than 1 million cases per year (India)

Treatment can help, but this condition can't be cured

Requires a medical diagnosis

Lab tests or imaging often required

Central lab
Central India's First and Largest Super-specialty reference laboratory
For Free Home Collection, call - 786-99999-37

CHAIRITABLE CENTER -CC111

Name: (DUE -980) BABY VIBHI SEKSARIA Age: 7 Years Sex: Female
Referred By: Dr ASHISH BATHAM Received On: 07-Aug-2017 09:19
Drawn On: 07-Aug-2017 09:15 Report Date: 10-Aug-2017 18:58
Accession No.: 1708102976

Parameter	Result	Unit	Biological Reference Interval
tTG-Tissue transglutaminase-IgA by E.I.A.			
tTG-Tissue transglutaminase-IgA by E.I.A.	0.875 (POSITIVE) CUT OFF 0.487	RATIO	

Central lab
Central India's First and Largest Super-specialty reference laboratory
For Free Home Collection, call - 786-99999-37

CHAIRITABLE CENTER -CC111

Name: BABY VIBHI SEKSARIA Age: 7 Years Sex: Female
Referred By: Dr ASHISH BATHAM Received On: 24-Jul-2017 14:35
Drawn On: 24-Jul-2017 14:37 Report Date: 31-Jul-2017 11:58
Accession No.: 1767112650

Parameter	Result	Unit	Biological Reference Interval
C - REACTIVE PROTEIN (QUANTITATIVE)			
C - REACTIVE PROTEIN (QUANTITATIVE)	1.45 ↑↑	mg/dL	0.0 - 1.0

Central lab
Central India's First and Largest Super-specialty reference laboratory
For Feedback / Home Collection Call 786-99999-37 / 33

Charitable Centre - CC111

Name: VIBHI SEKSARIYA Age: 8 Years Sex: Female
Referred By: DR. ARPIT CHOPRA Received On: 29-Apr-2018 10:20
Drawn On: 29-Apr-2018 10:17 Print Date: 04-May-2018 10:40
Accession No.: 1804121632

Parameter	Result	Unit	Biological Reference Interval
tTG-Tissue transglutaminase-IgA by E.I.A.			
tTG-Tissue transglutaminase-IgA by E.I.A.	0.671 (POSITIVE) CUT OFF 0.573	RATIO	

Charitable Centre - CC111

Name: VIBHI SEKSARIYA Age: 8 Years Sex: Female
Referred By: DR. ARPIT CHOPRA Received On: 29-Apr-2018 10:20
Drawn On: 29-Apr-2018 10:17 Print Date: 04-May-2018 10:40
Accession No.: 1804121632

Parameter	Result	Unit	Biological Reference Interval
C - REACTIVE PROTEIN (QUANTITATIVE)			
C - REACTIVE PROTEIN (QUANTITATIVE)	0.64 ↓	mg/dL	0.0 - 1.0



कैंसर, किडनी फेलियर, अस्पताल में गंभीर रूप से
 भर्ती मरिजों का उपचार, कोमा, शल्य चिकित्सा योग्य रोग,
 ऑटो इम्यून रोग, जीवनभर दवाई लेने वाले रोगों की रोकथाम एवं
 300 प्रकार के असाध्य जटिल रोगों की चिकित्सा।



डॉ. अर्पित चौपड़ा (जैन)
 एच. डी. होम्योपैथी
 जटिल, असाध्य एवं
 शल्य रोग विशेषज्ञ

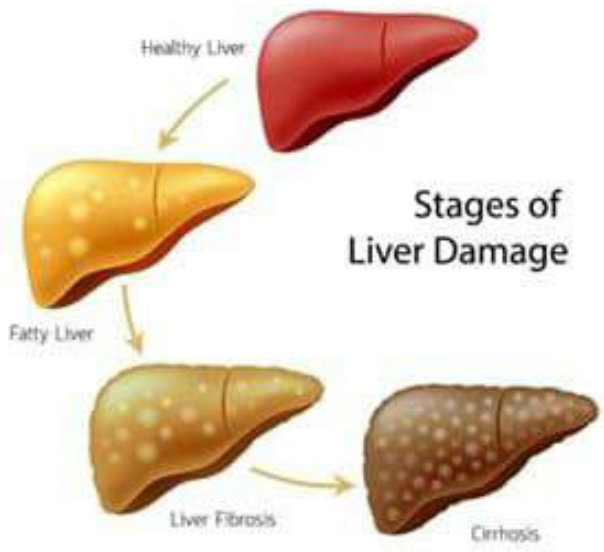
आरोग्य सुपर स्पेशलिटी माडर्न होमियोपैथी

कम्पलिट, परमानेन्ट, ईजी, सेफ, फास्ट एण्ड कॉस्ट इफैक्टिव

102, प्रथम मंजिल, कृष्णा टॉवर, क्योरवेल हॉस्पिटल के सामने, जंजीरवाला चौराहा, न्यू पलासिया, इन्दौर म.प्र.

📞 99075 27914 संपर्क : 0731-4977076, 79999 78894

www.homoeopathy cure.in, www.aarogyahomoeopathyindore.com Email : arpit Chopra23@gmail.com



Stages of liver damage. Healthy, fatty, liver fibrosis and Cirrhosis.

होम्यो



माडर्न होम्योपैथी



Modern Homeopathy -



Dr. Arpit Chopra (Jain) AAROGYA SUPERSPECIALITY MODERN HOMEOPATHY CLINI
 (MD) HOMEOPATHY Complete, Safe, Fast & Cost- Effective Modern Homeopathy Cured With Advanced Lifestyle
 PHYSICAL & MENTAL DISEASES SPECIALIST
 Founder Of Super Speciality Modern Homeopathy Phone : 0731-4977076, Mobile : 97130-92737, 97130-37737, 79999-78894, For Whatsapp, 99075-279

Overview

Symptoms

Treatment

A chronic, inflammatory bowel disease that causes inflammation in the digestive tract.

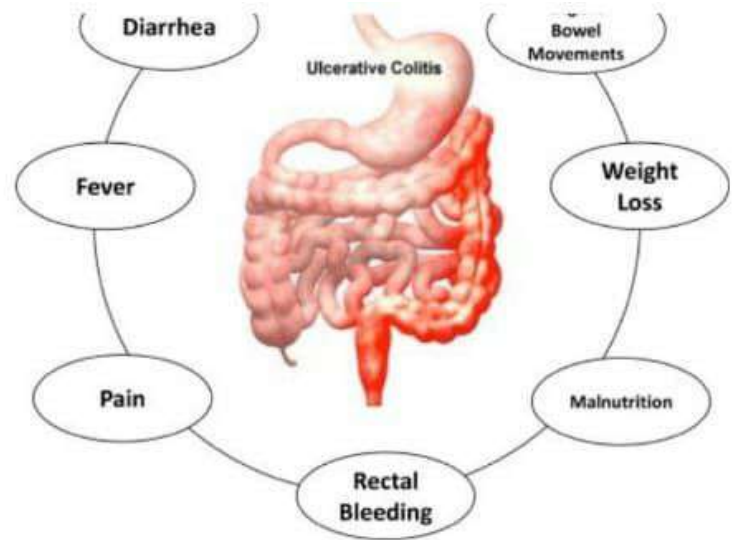
Ulcerative colitis is usually only in the innermost lining of the large intestine (colon) and rectum. Forms range from mild to severe. Having ulcerative colitis puts a patient at increased risk of developing colon cancer.

Common

More than 1 million cases per year (India)

+ Treatment can help, but this condition can't be cured

📅 Requires a medical diagnosis



Ulcerative colitis symptoms can vary, depending on the severity of inflammation and where it occurs. Signs and symptoms may include:

- Diarrhea, often with blood or pus
- Abdominal pain and cramping
- Rectal pain
- Rectal bleeding — passing blood with

मॉडर्न होम्योपैथी
Modern Homeopathy - Complete, Permanent, Easy, Safe, Fast & Cost Effective Cure

Seema Badjatiya
Mandsaur (M.P.)

Dr. Arpit Chopra (Jain) AAROGYA SUPERSPECIALITY MODERN HOMEOPATHY CLINIC
Complete, Safe, Fast & Cost-Effective Modern Homeopathy Cured With Advanced Lifestyle
Phone: 0731-4977076, Mobile: 97130-92737, 97130-37737, 79999-78894, For WhatsApp, 99073-2211

ALLBLADDER STONE, HEREDITARY DISEASES, INCRUCIATED

मॉडर्न होम्योपैथी
Modern Homeopathy - Complete, Permanent, Easy, Safe, Fast & Cost Effective Cure

Dr. Arpit Chopra (Jain) AAROGYA SUPERSPECIALITY MODERN HOMEOPATHY CLINIC
Complete, Safe, Fast & Cost-Effective Modern Homeopathy Cured With Advanced Lifestyle
Phone: 0731-4977076, Mobile: 97130-92737, 97130-37737, 79999-78894, For WhatsApp, 99073-2211

ALLBLADDER STONE, HEREDITARY DISEASES, INCRUCIATED

Then I came to know about the Dr. Arpit sir

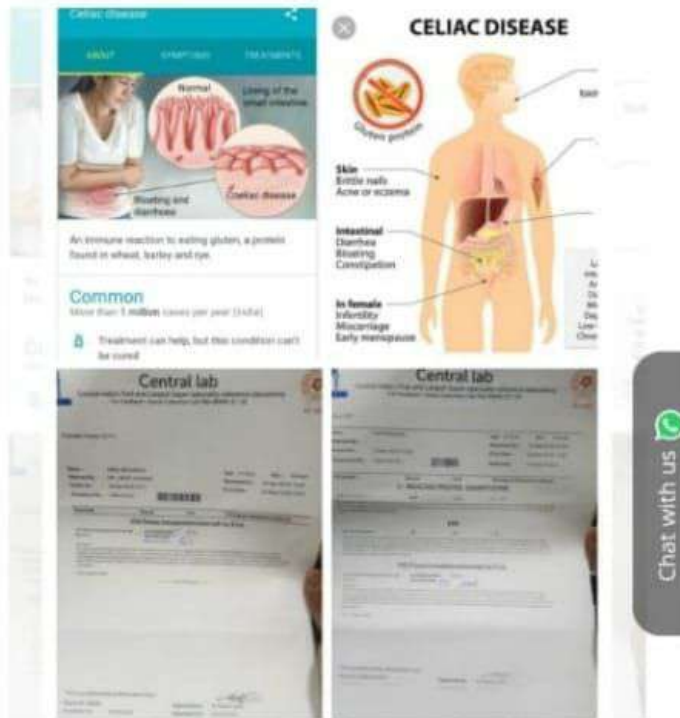
ULCERATIVE COLITIS

क्रिटिकल केस का सफल ईलाज मो. इल्यास फारुकी

Dr. Arpit Chopra Jain (MD Homoeopathy Critical & Surgical Case Specialist)

सक्सेस 15:39

मॉडर्न होमियापथा क द्वारा



🖱️ CELIAC DISEASE another very
UNCURABLE DECLARED , complicated,
AUTO IMMUNE DISEASE successfully
 miracally responded & cured by Modern
 Homoeopathy with significant **REVERSAL**
 OF **POSITIVE tTG -IGA (TRANS**
GLUTAMINASE)level 0.671 to NEGATIVE
LEVEL 0.153 . This reports & efforts with

कैंसर, किडनी फेलियर, अस्पताल में गंभीर रूप से भर्ती मरीजों का उपचार, कोमा, शल्य चिकित्सा योग्य रोग, ऑटो इम्यून रोग, जीवनभर दवाई लेने वाले रोगों की रोकथाम

300 प्रकार के असाध्य जटिल रोगों की चिकित्सा

आरोग्य सुपर स्पेशलिटी मॉडर्न होमियोपैथिक क्लिनिक

बनारसी, पटना रोड, हुंजी, बंग, कृष्ण एच बीए इन्वेंचर 102, बंगल नैशनल, कृष्ण टॉवर, कलकत्ता इन्वेंचर के समाने, जटिलरोगों के लिए, न्यू पारसिफ, इन्टेल प.क., कोरगाव, 999075 22914 (बनारस) फोन : 0731-4977076, 79999 78884

www.homeopathycare.in
 www.aarogyahomeopathyindia.com
 Email: aarochopra23@gmail.com

कैंसर, किडनी फेलियर, अस्पताल में गंभीर रूप से भर्ती मरीजों का उपचार, कोमा, शल्य चिकित्सा योग्य रोग, ऑटो इम्यून रोग, जीवनभर दवाई लेने वाले रोगों की रोकथाम

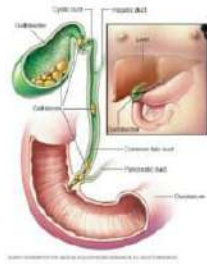300 प्रकार के असाध्य जटिल रोगों की चिकित्सा

आरोग्य सुपर स्पेशलिटी मॉडर्न होमियोपैथिक क्लिनिक

बनारसी, पटना रोड, हुंजी, बंग, कृष्ण एच बीए इन्वेंचर 102, बंगल नैशनल, कृष्ण टॉवर, कलकत्ता इन्वेंचर के समाने, जटिलरोगों के लिए, न्यू पारसिफ, इन्टेल प.क., कोरगाव, 999075 22914 (बनारस) फोन : 0731-4977076, 79999 78884

www.homeopathycare.in
 www.aarogyahomeopathyindia.com
 Email: aarochopra23@gmail.com

Gallstones are hardened deposits of digestive fluid that can form in your gallbladder. Your gallbladder is a small, pear-shaped organ on the right side of your abdomen, just beneath your liver. The gallbladder holds a digestive fluid called bile that's released into your small intestine.



Gallstones

आरोग्य सुपर स्पेशलिटी मॉडर्न होम्योपैथिक क्लीनिक

होम्योपैथिक • पल्पानेन्ट • इन्टी • सेफ • फास्ट एण्ड कॉस्ट इफिक्टिव

डॉ. अरपि चोपड़ा
पु. अ. इण्डिया अथवा
अमेरिका में काम करे बिना

• कैंसर • किडनी फेलियर • जलवायु में नंगीर रूप से • भूतों भड़कों का उपचार • कोमा
• शल्य चिकित्सा योग्य रोग • अतीव दुर्लभ रोग • ब्रिचर पर दवाई देने वाले रोगों की शोकसाम
एवं 300 प्रकार के प्रभावजनक जटिल रोगों की चिकित्सा।

122, 104 प्रथम मंजिल, कृष्णा टॉवर, कवोरेवेल प्रॉस्पेक्ट के सामने, जेजीवाला चौक, अ. प. पारिवारिका, इन्दौर (म.प.)
फोन : 0731-4977076, मो. : 97130-92737, 97130-37737, 79999-78594, 99075-27914
www.homoeopathycare.in, www.aarogyahomoeopathyindore.com Email : arpilchoora23@gmail.com



RUBY MEDICAL SERVICES, WAGHOLI
MAIN BRANCH | Cat No. 847, Opposite Lifeline Hospital, Behind Babunagar Cloth Store,
Pune Nagar Road, Wagholi, Pune - 412207.
UNIT 2 | Shop No. 19, 9 Kruneshwari Commercial Complex, Cat No. 848/2, Near Lifeline Hospital,
Wagholi - Pune - 412207.

Name Of Patient: Mrs. Amrapali Jathar
Ref By: Dr. Eknath Khete
(Abdominal fat limits evaluation.)

AGE/SEX: 40 Yrs/ F
Date: 11/10/2021

USG ABDOMEN & PELVIS

LIVER: Normal in size and shows diffusely raised echogenicity. No evidence of focal space occupying lesion noted. Intrahepatic biliary radicals are not dilated. Hepatic veins appear normal.

PORTAL VEIN: Normal in caliber. No evidence of internal thrombus seen.

GALL BLADDER: Normally distended. Echogenic 9.1 mm calculus is noted in the neck region. No wall edema seen. Sludge is seen in the lumen.

PANCREAS: Visualized part is normal in size and echotexture. No evidence of focal lesion noted. MPD not dilated.

SPLEEN: Normal in size. No focal lesion noted. Splenic vein is not dilated.

KIDNEYS & URETERS: Both the kidneys show normal echotexture and normal corticomedullary differentiation.

Right Kidney: Normal in size (10.4 x 4.1 cm). PCS not dilated. Echogenic 4.5 mm calculus is noted in the mid pole calyx.

Left Kidney: Normal in size (10.7 x 4.5 cm). Echogenic 5.8 mm calculus is noted in the mid pole calyx. Mild hydronephrosis and proximal hydroureter is noted on left side secondary to a partially obstructing 9.0 mm calculus in left lower ureter distal to the iliac vessels.

URINARY BLADDER: Normally distended. No wall thickening noted. No calculus or mass lesion seen in the lumen.

UTERUS: Normal in size. Myometrium is normal in echoes. No focal lesion noted. Endometrial thickness measures - 7.5 mm.

OVARIES:
Right ovary: Normal in size.
Left ovary: Normal in size.

OTHER FINDINGS:
Visualized bowel loops are normal in caliber.
No ascites/free fluid is noted within peritoneal/abdominal & pelvic cavity.
No e/o mesenteric lymphadenopathy.
Retroperitoneum, aorta is visualized normal.

IMPRESSION:

- Mild hydronephrosis and proximal hydroureter is noted on left side secondary to a partially obstructing 9.0 mm calculus in left lower ureter distal to the iliac vessels.
- Bilateral non-obstructive renal calculi.
- Cholelithiasis.
- Grade 1 fatty liver.

before treatment

For Appointment ☎ 8956022355, 8956022356 | For Night Emergency USG ☎ 8956022355
rubymedicalserviceswagholi@gmail.com www.rubymedicalserviceswagholi.com
DR. SAMEER DHUMALE
CONSULTANT RADIOLOGIST

RUBY MEDICAL SERVICES, WAGHOLI
MAIN BRANCH | Cat No. 847, Opposite Lifeline Hospital, Behind Babunagar Cloth Store,
Pune Nagar Road, Wagholi, Pune - 412207.
UNIT 2 | Shop No. 19, 9 Kruneshwari Commercial Complex, Cat No. 848/2, Near Lifeline Hospital,
Wagholi - Pune - 412207.

Name Of Patient: Mrs. Amrapali Jathar
Ref By: Dr. Eknath Khete
(Abdominal fat limits evaluation.)

AGE/SEX: 40 Yrs/ F
Date: 03/12/2021

USG ABDOMEN & PELVIS

LIVER: Normal in size and shows diffusely raised echogenicity. No evidence of focal space occupying lesion noted. Intrahepatic biliary radicals are not dilated. Hepatic veins appear normal.

PORTAL VEIN: Normal in caliber. No evidence of internal thrombus seen.

GALL BLADDER: Normally distended. No evidence of calculus noted. No wall edema seen. No pericholecystic collection seen. No sludge seen in the lumen.

PANCREAS: Visualized part is normal in size and echotexture. No evidence of focal lesion noted. MPD not dilated.

SPLEEN: Normal in size. No focal lesion noted. Splenic vein is not dilated.

KIDNEYS & URETERS: Both the kidneys show normal echotexture and normal corticomedullary differentiation.

Right Kidney: Normal in size (10.4 x 4.1 cm). PCS not dilated. Echogenic 4.5 mm calculus is noted in the mid pole calyx.

Left Kidney: Normal in size (10.7 x 4.5 cm). Echogenic 6.0 mm calculus is noted in the mid pole calyx. Mild hydronephrosis and proximal hydroureter is noted on left side secondary to a partially obstructing 9.1 mm calculus at the left VUJ.

URINARY BLADDER: Normally distended. No wall thickening noted. No calculus or mass lesion seen in the lumen.

UTERUS: Normal in size. Myometrium is normal in echoes. No focal lesion noted. Endometrial thickness measures - 9.6 mm.

OVARIES:
Right ovary: Normal in size.
Left ovary: Normal in size.

OTHER FINDINGS:
Visualized bowel loops are normal in caliber.
No ascites/free fluid is noted within peritoneal/abdominal & pelvic cavity.
No e/o mesenteric lymphadenopathy.
Retroperitoneum, aorta is visualized normal.

IMPRESSION:

- Mild hydronephrosis and proximal hydroureter on left side secondary to a partially obstructing 9.0 mm calculus at the left VUJ.
- Bilateral non-obstructive renal calculi.
- Grade 1 fatty liver.

after 1 month modern homoeopathy treatment

For Appointment ☎ 8956022355, 8956022356 | For Night Emergency USG ☎ 8956022355
rubymedicalserviceswagholi@gmail.com www.rubymedicalserviceswagholi.com
DR. SAMEER DHUMALE
CONSULTANT RADIOLOGIST

Gallstones

Also called: cholelithiasis

OVERVIEW SYMPTOMS TREATMENTS NEWS

A hardened deposit within the fluid in the gallbladder, a small organ under the liver.

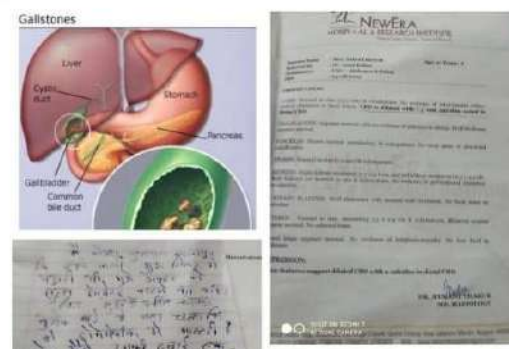
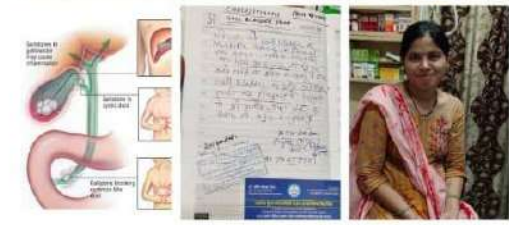

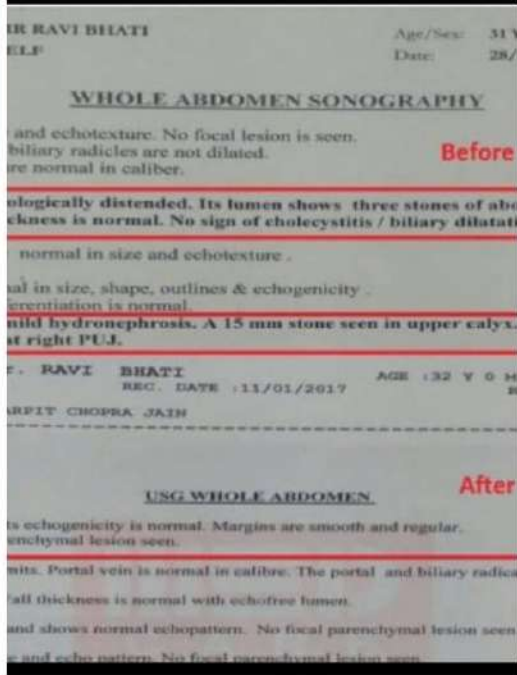
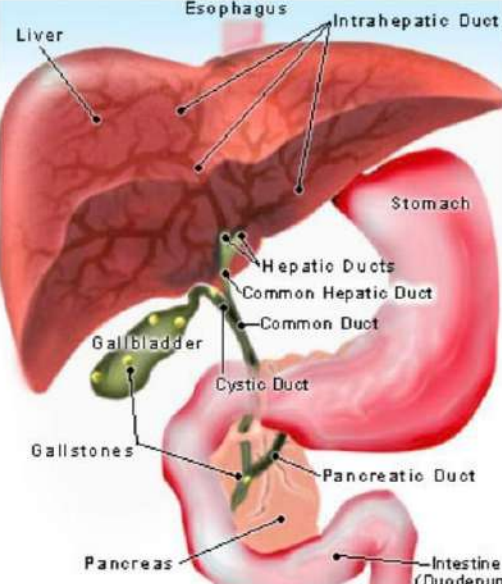
Gallstones are hardened deposits of digestive fluid.

Very common

More than 10 million cases per year (India)

- Treatable by a medical professional
- Requires a medical diagnosis
- Lab tests or imaging always required
- Chronic: can last for years or be lifelong

What Are Gallstones?



Dr. Arpit Chopra (Jain)
M.D. HOMOEOPATHY
(Critical & Surgical Diseases Specialist)

9907527914, 971303713092737, 799997

AAROGYA SUPER SPECIALITY MODERN HOMOEOPATHIC CLINIC

Complete, Easy, Safe, Fast & Costeffective
Permanent Modern Homoeopathy Cure With Advance Lifestyle
102, First Floor Krishna Tower In front of Curewell Hospital
Janjeer Wala Churahra, INDORE (M.P.)
Time : 10 am to 3pm & 5 pm to 10 pm, Sunday : 12.00 am to 2.00 pm
Please Take Appointment Before Consultancy as Possible, Ph.: 0731-4977
www.homoeopathycure.com, Email - arpitchopra23@gmail.com

Dr. Arpit Chopra (Jain)
M.D. HOMOEOPATHY
(Critical & Surgical Diseases Specialist)

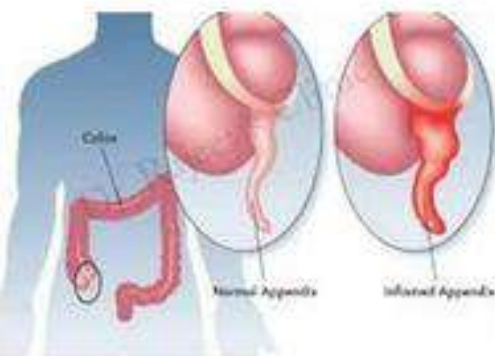
AAROGYA SUPER SPECIALITY MODERN HOMOEOPATHIC CLINIC

Complete, Easy, Safe, Fast & Costeffective
Permanent Modern Homoeopathy Cure With Advance Lifestyle
102, First Floor Krishna Tower In front of Curewell Hospital
Janjeer Wala Churahra, INDORE (M.P.)
Time : 10 am to 3pm & 5 pm to 10 pm, Sunday : 12.00 am to 2.00 pm
Please Take Appointment Before Consultancy as Possible, Ph.: 0731-4977
www.homoeopathycure.com, Email - arpitchopra23@gmail.com

Dr. Arpit Chopra (Jain)
M.D. HOMOEOPATHY
(Critical & Surgical Diseases Specialist)

AAROGYA SUPER SPECIALITY MODERN HOMOEOPATHIC CLINIC

Complete, Easy, Safe, Fast & Costeffective
Permanent Modern Homoeopathy Cure With Advance Lifestyle
102, First Floor Krishna Tower In front of Curewell Hospital
Janjeer Wala Churahra, INDORE (M.P.)
Time : 10 am to 3pm & 5 pm to 10 pm, Sunday : 12.00 am to 2.00 pm
Please Take Appointment Before Consultancy as Possible, Ph.: 0731-4977
www.homoeopathycure.com, Email - arpitchopra23@gmail.com



Appendicitis

Overview

Symptoms

Treatment

A condition in which the appendix becomes inflamed and filled with pus, causing pain.

The appendix is a pouch-like structure attached at the start of the large intestine that has no known purpose.

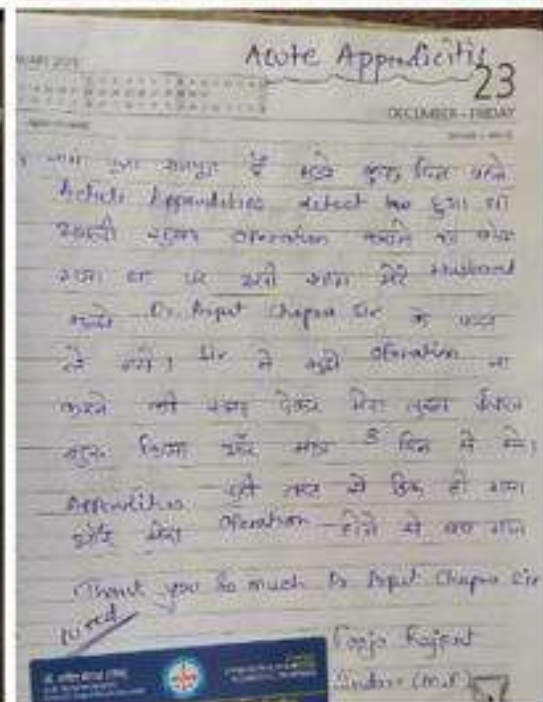
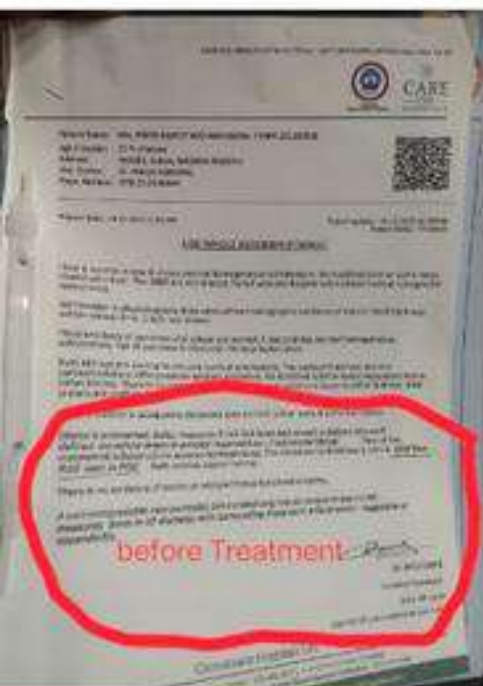
Common

More than 1 million cases per year (India)

- Requires a medical diagnosis
- Lab tests or imaging often required
- Treatable by a medical professional

Acute appendicitis

Acute appendicitis is the sudden and severe inflammation of the appendix. It can cause pain in the abdomen, and this pain



ऑपरेशन या सर्जरी के बगैर पाए अपनी समस्याओं का इलाज

26-Jan-2017 - Appendicitis is a medical emergency that almost always requires prompt surgery to remove the appendix. Left untreated, an inflamed appendix will eventually burst or perforate, spilling infectious



पेट संबंधित सभी प्रकार की बीमारियों का मॉडर्न होम्योपैथी द्वारा चमत्कारिक संभव इलाज

• हमरी 1 वर्ष से 45 वर्षों तक की पुराने पेट, फिलर, विस्फुरण, फ्लोइडल सिनस (Fluoidal Sinus) बिना ऑपरेशन के सही हुए एवं बार-बार होने वाली पेशाबों की जड़ से समाप्त हुए। - नमन बधवासा, मोन्द्र सिंह, अमित अक्कहास, इंपेत जर्मा, गिरजा शंकर, संगीत विजयकर्मा, विनेश चाल्सीय, दिपेन, राजेश, डॉ हेमराज बनकर, मोहनलाल विजयर्मा, प्रदीप सिंह, धनेन्द्र हाईडिया।

• हमरी 4 से 40 वर्षी पुराने ल्यूसाज अल्टेइमम बीमारी अप्पेंडिसाइटिस (Ulcerative colitis) पूरी तरह ठीक हुए और हमें जीवन भर दर्दों खाने से बचाव। - ज्ञानी चौरवाल रातलम, संगीता बहुजालिया मंडोले, इतिहास फारुकी इंदौर।

• हमरी वर्षी पुराने Acidity, GERD & IBS को सफल जड़ से खत्म हुए। - अमित कुम्वार, सविन कुंजरी, प्रमोद चौहान, सुनिल शिंदे इंदौर, साधुराज खान उज्जैन।

• हमरी गंधी बीमारी Celiac Disease, Lactose Intolerance किसी भी कच्चे फलों करने पड़े, या पुरे तरह जड़ से खत्म हुए और हमरी ITG रिपोर्ट भी समाप्त हो गई। - मेधी विधि सभारिया, दिक्षु परिहार।

• गंधी गंधी बीमारी Intestinal Obstruction & Appendicitis बिना किसी ऑपरेशन के सही हुए। - यदोच झा, सुधय चाल्सीय।

• हमरी ल्यूसाज निगर को सफल जैसे- Fatty Liver, Chronic Liver Disease, Liver Cirrhosis, पीलिया को ल्यूसाज में घाबरा लेकर खत्म जीवन जी पा रहे हैं। - संदीप जर्मा, अमित मिश्र, धंवर सिंह, प्रमोद मेहरा, लाल बहादुर, सोमराजी।

• हमरी पिडाल को पथी (Gall Bladder Stone)

5 से 28 mm की सफल बिना किसी पथी ठीक हुए। - पुंकेज चरणम मिश्र, अश्वी मिश्र (गैब), अश्वकरी चरण, अर्जुन मेवट।

• हमरी Chronic Pancreatitis, Pancreatic Retroperitoneal Cancer को 60x40mm पथन,

Rectal Cancer को पथन, Esophageal Cancer को सफल बिना ऑपरेशन एवं बिना किसी मेरी, पेटको मेरी के पुरे तरह ठीक हुए। - आकाश गजें हरदा, परमार्थ मोड़, सूरिख जैन इंदौर, फालीय श्री सागर, विंकिन अर्पेटे

पेट संबंधित सभी प्रकार की बीमारियों का समाधान : डॉ अर्पित चोपड़ा मॉडर्न होम्योपैथी

• डॉ. अर्पित चोपड़ा (डॉ.) को केन्द्रीय स्वास्थ्य मंत्री की सहायक सचिविता द्वारा सर्वोच्च पुरस्कार मिला।

• वैसाय • सिविल फेलोशिप • अलसर्टिक एडमिशन • अस्पताल में सफ़ीर रूप से डॉ. अर्पित को अस्पताल • कोला • अन्ध विदियन चोपड़ा टोप • अर्पित इन्फ़ुयू टोप • अर्पित चोपड़ा डॉ. को पुराने टोपों की रोकथाम एवं 300 प्रकार के अलसर्टिक एडमिशन की सिफ़ारिश।

• मॉडर्न होम्योपैथी के अतिथक के लिए डॉ. अर्पित चोपड़ा (डॉ.) को कई राष्ट्रीय और अंतरराष्ट्रीय पुरस्कारों से भी सम्मानित किया जा चुका है।

आरोग्य सुपर स्पेशलिटी मॉडर्न होम्योपैथिक क्लिनिक
 कम्प्यूटर | प्लानेट | डीपी | लेक | फास्ट | कॉस्ट इफेक्टिव
 102, 104, 3रा मंजिल, कृष्णा टॉवर, एनोपेल हॉस्पिटल के सामने, अजीबलाल चौक, न्यू चाल्सीय, इंदौर
 मोबा. 99075 27914 79999 78894 फोन - 0735-4977076 सप्ताह सुका न से राती 8 बजे तक (रुमकाज से सफ़ीर)
 YouTube channel-Dr Arpit Chopra's super speciality modern homeopathic
 www.aarogyahomeopathyindore.com, E-mail: arpitchopra23@gmail.com



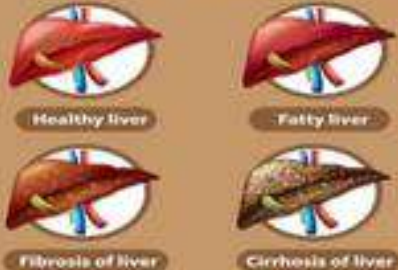Description

Gastric Problem Cured | Gastric Disease Success Stories | Dr. Arpit Chopra Jain | Modern Homeopathy


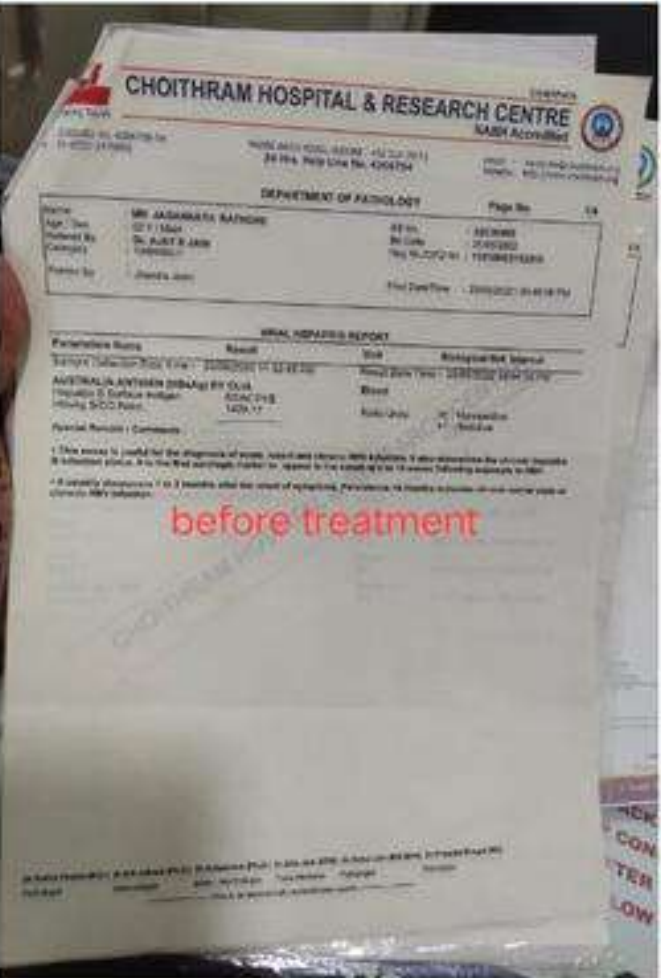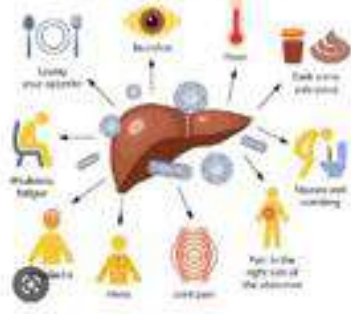
Most Common Digestive System Problems or Diseases

- Kidney stones
- Irritable bow syndrome (IBS)
- Crohn's disease
- Constipation
- Appendicitis
- Ulcers
- Gas in Intestines
- Gastritis

Stages of Liver Disease Leading to Cirrhosis



SYMPTOMS OF HEPATITIS B



डॉ. अरुण चोप्रा (Dr. Arpit Chopra)
 आरोग्य सुपर स्पेशलिटी मॉडर्न होमियोपैथी
 कम्प्लिमेंटरी, पर्यावरण, इंजीनी, शैव, फारम एण्ड कॉस्ट इकोनॉमिक
 102, प्राण शक्ति, पृथ्वी टॉवर, आर्य समाज सोसायटी के सामने, जवाहरनगर रोड, नू. वसतिगंगा, इन्डौर म.प.
 495015-27914, 795000-78884
 0731-4877076, 795000-78884
 www.homioecoclinic.com, www.arpitchoprahomeopathy.com, Email: arpitchopra23@hotmail.com

कैंसर, किडनी फेलियर, अस्पताल में गंभीर रूप से भर्ती मरिजों का उपचार, कोमा, शल्य चिकित्सा योग्य रोग, ऑटो इम्यून रोग, जीवनर दवाई लेने वाले रोगों की रोकथाम एवं 300 प्रकार के अग्रगण्य जटिल रोगों की चिकित्सा।

आरोग्य



कैंसर, किडनी फेलियर, अस्पताल में गंभीर रूप से भर्ती मरिजों का उपचार, कोमा, शल्य चिकित्सा योग्य रोग, ऑटो इम्यून रोग, जीवनभर दवाई लेने वाले रोगों की रोकथाम एवं 300 प्रकार के असाध्य जटिल रोगों की चिकित्सा।



अर्पित चौपड़ा (जैन)
एम. डी. होम्योपैथी
टेल, असाध्य एवं
न्यून रोग विशेषज्ञ

आरोग्य सुपर स्पेशलिटी मॉडर्न होमियोपैथी

कम्पलिट, परमानेंट, ईजी, सेफ, फास्ट एण्ड कॉस्ट इफैक्टिव

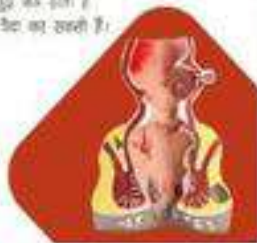102, प्रथम मंजिल, कृष्णा टॉवर, क्योरवेल हॉस्पिटल के सामने, जंजीरवाला चौराहा, न्यू पलासिया, इन्दौर म.प्र.

99075 27914 संपर्क : 0731-4977076, 79999 78894

www.homoeopathy cure.in. www.aaromahomoeopathyindore.com Email : arpitchopra23@gmail.com

पाइल्स (बवासीर) क्या हैं ?

पाइल्स को दुहरे शरीर में बढ़ती कठोर है।
वे विकारे गुदा और मलमार्ग में घुसी हुई खरे होती हैं
जो गुदा में और उसके आसपास गंद पैदा कर सकती हैं।



क्या आपको सभी डॉक्टरों ने ऑपरेशन की अंतिम सलाह दी है



6:17

अब नहीं करवाना पड़ेगा ऑपरेशन या कोई सर्जरी



4:26

ऑपरेशन या सर्जरी के बगैर पाए अपनी समस्याओं का इलाज



5:45

किसी प्रकार की सर्जरी या ऑपरेशन से बचाएगा ये वीडियो



5:53

किसी भी प्रकार की सर्जरी से पहले ये वीडियो ज़रूर देखे



5:07

Ulcerative colitis

Also called: UC, colitis ulcerosa

Overview

Symptoms

Treatments

A chronic, inflammatory bowel disease that causes inflammation in the digestive tract.

Ulcerative colitis is usually only in the innermost lining of the large intestine (colon) and rectum. Forms range from mild to severe. Having ulcerative colitis puts a patient at increased risk of developing colon cancer.

Common

More than 1 million cases per year (India)

कैंसर, किडनी फेलियर, अस्पताल में गंभीर रूप से भर्ती मरिजों का उपचार, कोमा, शल्य चिकित्सा योग्य रोग, ऑटो इम्यून रोग, जीवनभर दवाई लेने वाले रोगों की रोकथाम एवं 300 प्रकार के असाध्य जटिल रोगों की चिकित्सा।



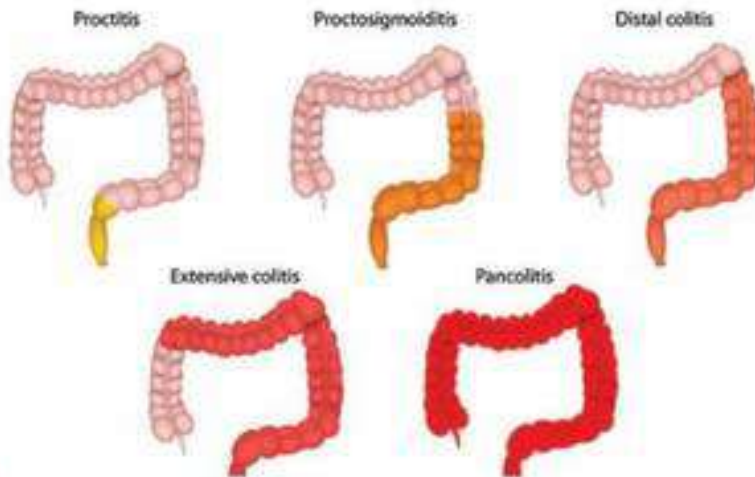
आरोग्य सुपर स्पेशलिटी मॉडर्न होमियोपैथी

कम्प्लिट, परमानेंट, इन्जी, सेफ, फास्ट एण्ड कॉस्ट इफेक्टिव

102, प्रथम मंजिल, कृष्णा टॉवर, क्योस्टेल इन्डिस्ट्रियल के सामने, जंजीरवाला वीरगढ़, न्यू पलासिया, इन्दौर म.प्र.

99075 27914, 0731-4877076, 79999 78894

TYPES OF ULCERATIVE COLITIS

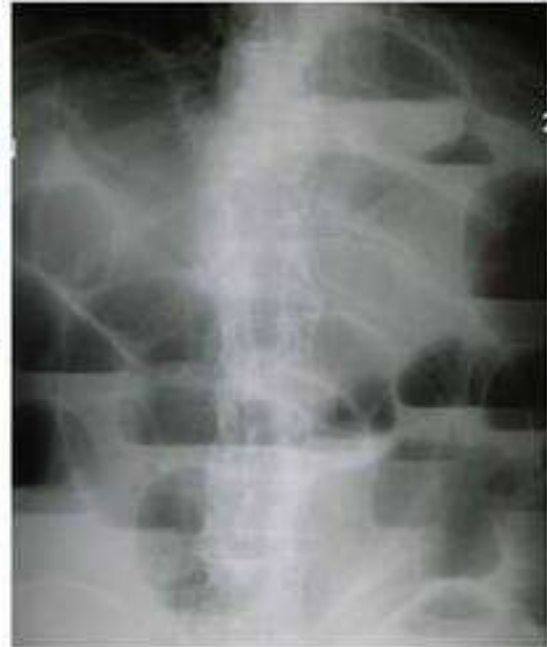
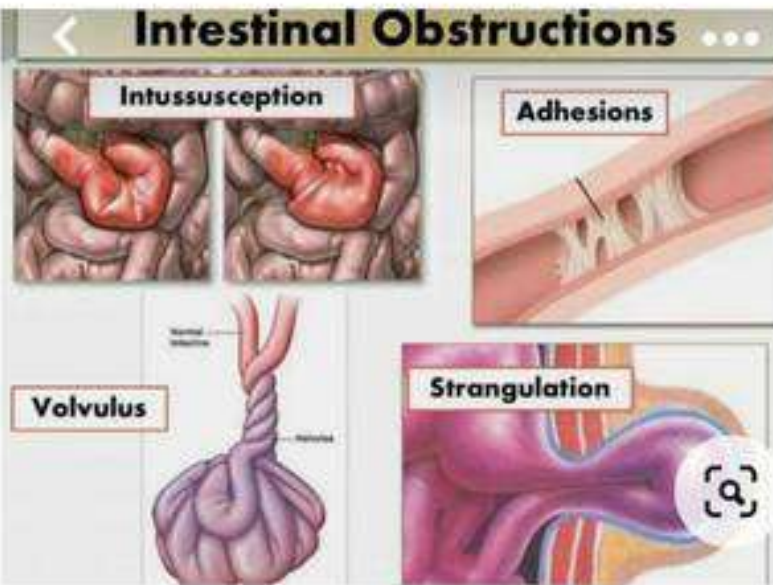
मॉडर्न होम्योपैथी

SHANTA PORWAL
RATLAM (M.P.)

Dr. Arpit Chopra (Jain)
JAIN HOMEOPATHY
DIRECTOR & SENIOR HOMEOPATHY SPECIALIST
Master of Super Speciality Homeopathy

AARDGYA SUPERSPECIALITY MODERN HOMEOPATHY CLINIC
Complete, Safe, Fast & Cost-Effective Modern Homeopathy Cured With Advanced Lifestyle
Phone: 0731-4877076, Mobile: 97130-82732, 97130-37732, 79999-78894, For Whatsapp: 99075-27914



आंतों में रुकावट

INTESTINAL OBSTRUCTION

CHRONIC CASE CURED

मोनिशा झा

सक्सेस 17:30

डॉ. अर्पित चोपड़ा जैन (MD Homoeopathy Critical & Surgical Case Specialist)

कैंसर, किडनी फेलियर, अस्पताल में गंभीर रूप से भर्ती मरीजों का उपचार, कोमा, शल्य चिकित्सा योग्य रोग, ऑटो इम्यून रोग, जीवनभर दवाई लेने वाले रोगों की रोकथाम एवं 300 प्रकार के असाध्य जटिल रोगों की चिकित्सा।

आरोग्य सुपर स्पेशलिटी माईन होमियोपैथी

कम्प्लिट, परमानेंट, ड्रग्स, सोफ, फास्ट एण्ड कॉस्ट इफेक्टिव

102, प्रथम मंजिल, सुभा टीवर, नवोत्पल हॉस्पिटल के सामने, जे-बी-रोड, गुरु परचरिया, इ.
 99075 27914 | वॉपर्स : 0131-4077076, 79000 78894
www.homoeopathycurer.in, www.aarogysuperhomoeopathyindia.com | Email : arpitchopra23@gmail.com



WORLD LIVER DAY

Dr. Arpit Chopra's Su... 241 views • 1 year a...

HCC HEPATOCYLLULAR CA... 358 views • 1 year a...

liver Abscess Cured | Liver Abs... 445 views • 7 mont...

Hepatitis B with Liver Cirrhosis re... 121 views • 4 mont...

हेपेटाइटिस बी लीवर 71 views • 3 months...

Irritable bowel Syndrome | IBS Ir... 191 views • 2 mont...

Irritable bowel Syndrome | IBS Ir... 122 views • 2 mont...

Hyper Acidity | Gastritis | GERD 157 views • 3 mont...

Recurrent Aphthous Stomat... 122 views • 2 mont...

Liver Cirrhosis CURED FIBROSIS Dr. Arpit Chopra's Su... 241 views • 1 year a...

HCC HEPATOCYLLULAR CA Dr. Arpit Chopra's Su... 358 views • 1 year a...

liver Abscess Cured | Liver Abs Dr. Arpit Chopra's Su... 445 views • 7 mont...

Hepatitis B with Liver Cirrhosis re Dr. Arpit Chopra's Su... 121 views • 4 mont...

हेपेटाइटिस बी लीवर Dr. Arpit Chopra's Su... 71 views • 3 months...

Irritable bowel Syndrome | IBS Ir Dr. Arpit Chopra's Su... 191 views • 2 mont...

Irritable bowel Syndrome | IBS Ir Dr. Arpit Chopra's Su... 122 views • 2 mont...

Hyper Acidity | Gastritis | GERD Dr. Arpit Chopra's Su... 157 views • 3 mont...

Recurrent Aphthous Stomat Dr. Arpit Chopra's Su...

USG IN WHOLE ABDOMEN

Name of Patient: MR. NITIN CHOPRA, Age: 50yrs 255/84

Reporting Date: 27/02/2023, URG: 6046-23

Ref. By: DR. ARPIT CHOPRA

Imaging Findings:

Liver is normal in size, measures approximately 12.4 cm. It shows normal echotexture. Margins are smooth. No HIDA dilatation seen. Portal vein measures 10.5 mm, shows sluggish flow.

Gall bladder is distended and shows normal wall thickness. Lumen appears anechoic.

Visualized pancreas appears normal in bulk, outline and echotexture.

Spleen is enlarged in size, measures approximately 13.5cm and shows normal echotexture. Splenic vein appears normal. Multiple collaterals are seen in perisplenic region, in epigastric and supraumbilical region.

Both kidneys are normal in size, outline and position. Cortical echogenicity is normal with maintained corticomedullary differentiation. No hydronephrosis is seen.

Right kidney measures: 10.7x4.0 cm. Left kidney measures: 11.1x4.7 cm.

Urinary bladder is well distended with normal wall thickness & anechoic lumen.

Conclusion: (2)

After Dr Arpit Chopra Modern Homeopathy Treatment

ULCERATIVE COLITIS CURED Dr. Arpit Chopra's Su... 1.1K views • 1 year...

GERD Disease Hyper Acidity Gastritis GERD G... Dr. Arpit Chopra's Su... 961 views • 10 mon...

IBS cured | IBS Recovery Patient Dr. Arpit Chopra's Su... 1K views • 9 month...

ULCERATIVE COLITIS CURED Dr. Arpit Chopra's Su... 1.1K views • 1 year...

Hiatus hernia with Severe Gastritis Dr. Arpit Chopra's Su... 156 views • 7 mont...

Hiatus hernia with Severe Gastritis Dr. Arpit Chopra's Su...

IBS IRRITABLE BOWEL SYNDRO... Dr. Arpit Chopra's Su... 245 views • 1 year a...

IBS cured | IBS Recovery Patient Dr. Arpit Chopra's Su... 1K views • 9 month...

ULCERATIVE COLITIS CURED Dr. Arpit Chopra's Su... 1.1K views • 1 year...

Ulcerative Colitis Cured | Ul... Dr. Arpit Chopra's Su... 1.6K views • 11 mo...

Colitis Abdominal pain Gastritis Dr. Arpit Chopra's Su...

HEPATOCELLULAR CARCINOMA Dr. Arpit Chopra's Su 241 views • 2 years...

Hepatocellular Carcinoma | HC... Dr. Arpit Chopra's Su 166 views • 1 year a...

Gastrointestinal & Hepatic disease. Dr. Arpit Chopra's Su 215 views • 3 mont...

Hepatocellular Carcinoma | HC... Dr. Arpit Chopra's Su 85 views • 1 month...

संभव (Sambhav) advertisement with a doctor's image and text in Hindi.

HEPATOCELLULAR CARCINOMA Dr. Arpit Chopra's Su 241 views • 2 years...

Hepatocellular Carcinoma | HC... Dr. Arpit Chopra's Su 166 views • 1 year a...

Gastrointestinal & Hepatic disease. Dr. Arpit Chopra's Su 215 views • 3 mont...

Hepatocellular Carcinoma | HC... Dr. Arpit Chopra's Su 85 views • 1 month...

CARE CHL-HOSPITALS

DEPARTMENT OF GASTROENTEROLOGY

Small Endoscopy Report:

Trifurcation: Nosophagal varices, Dr. RST.

Esophagus: Grade II & 4 Esophageal varices, var reflux.

Stomach: PHG present.

Duodenum: D1 and D2 normal.

Impression: Esophageal varices, EST done, PHG.

After Dr Arpit Chopra Modern Homeopathy Treatment

रूप से मर्ली मरिजों का उपचार, कोमा, अंतिम अवस्था रोग, ऑटो इम्यून रोग, शल्य चिकित्सा योग्य रोग, सेरिब्रल एड्रॉफी, मस्कुलर डिस्ट्रॉफी, पार्किन्सन रोग, एप्लास्टिक एनिमिया, स्प्लेनोटाइड आर्थिराइटिस, स्प्लेनल स्टेनोसिस, स्त्रिीय डिस्क, फेटी लीवर एवं लीवर सिर्रोसिस, ब्रेन स्टोक के बाद आने वाली मर्ली समन्यारं पक्षाघात, एनकेलोसिंग स्पेन्डि लाइटिस बंधों का उपचार, गुदा संबंधी रोग थायरॉईड संबंधी रोग, नपुंसकता, बौद्धिपन, गुम रोग, रुकिया, कमर दर्द, साइटिका, माइग्रेन, घुटनों में दर्द, डायबिटीज, स्तन एवं गर्भाशय की कठाने, प्रोस्टेट एवं मूत्र सम्बंधी रोग, गुदा एवं पित्त नली कि पथरी, वंशानुगत रोग, पुराने, असाध्य एवं मानसिक रोग

✓ c/o Chronic liver disease ✓ Mild PH (Chyptogenic) ✓ Before Dr Arpit Chopra Modern Homeopathy Treatment ✓

→ Splenomegaly 13cm ✓

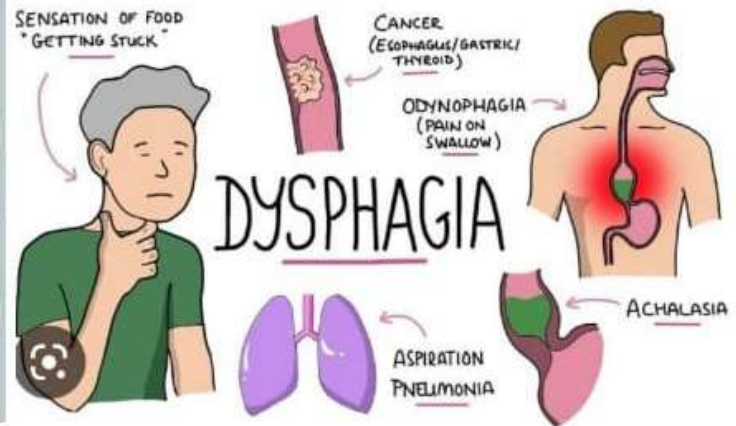
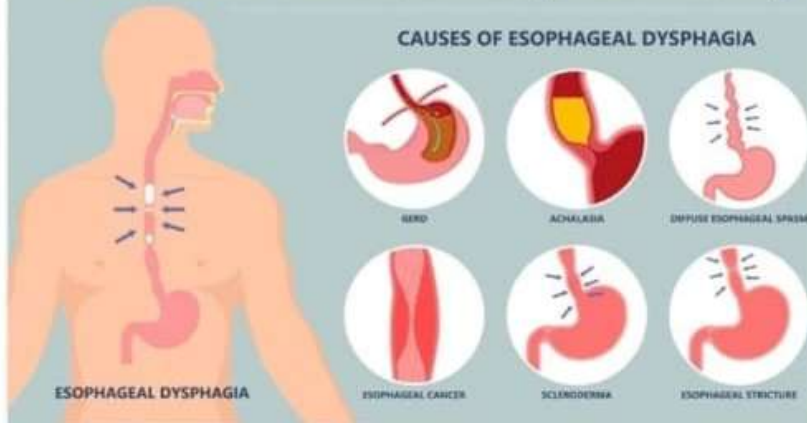→ H/o Ascites ✓

→ large Esophageal Grade III ✓

→ EVL done ✓

→ Difficulty digestion ✓

DIFFICULTY SWALLOWING (DYSPHAGIA)



Difficulty swallowing

Also called: Dysphagia

Overview

Treatments

Difficulty swallowing foods or liquids, arising from the throat or oesophagus, ranging from mild difficulty to complete and painful blockage.

COMMON CAUSES

Difficulty swallowing can have causes that aren't due to underlying disease. Examples include large bites of food, inadequate chewing, dry mouth, pills or food that's too hot



Title

Dysphagia difficulty & pain in swallowing foods & liquid ,cured by Dr Arpit chopra Modern Homeopathy



डॉ. अर्पित चोपड़ा (मैन)
एम.बी. होम्योपैथी
एच.डी. असाध्य रोग
सायबे रोग विशेषज्ञ

आरोग्य सुपर स्पेशलिटी मॉडर्न होम्योपैथिक क्लीनिक



कम्पलिट * परमानेन्ट * ईजी * सेफ * फास्ट एण्ड कॉस्ट इफैक्टिव

* कैंसर * किडनी फेलियर * अस्पताल में गंभीर रूप से भर्ती मरिजों का उपचार * कोमा *
* शल्य चिकित्सा योग्य रोग * आँटो इम्यून रोग * जीवनभर दवाई लेने वाले रोगों की रोकथाम
एवं 300 प्रकार के असाध्य जटिल रोगों की चिकित्सा ।

102, 104, प्रथम मंजिल, कृष्णा टॉवर, क्योरवेल हॉस्पिटल के सामने, जंजीखाला चौराहा, न्यू पलासिया, इन्दौर (म.प्र.)

फोन : 0731-4977076, मो. : 97130-92737, 97130-37737, 799999-78894, 99075-27914

www.homoeopathyure.in, www.aarogyahomoeopathyindore.com Email : arpitchopra23@gmail.com

Gallstones

Also called: cholelithiasis

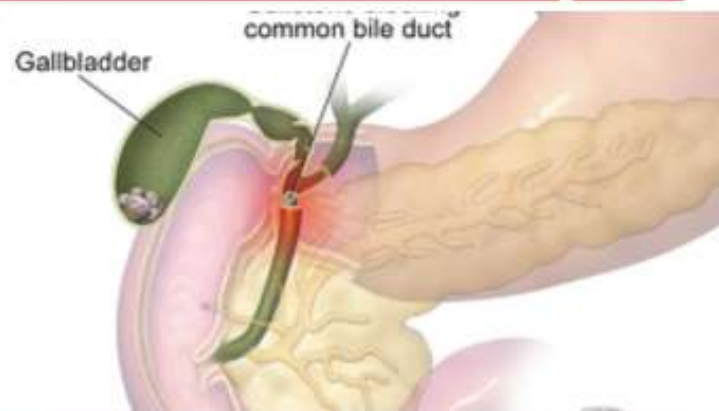OVERVIEW

SYMPTOMS

TREATMENTS

SPE

A hardened deposit within the fluid in the gallbladder, a small organ under the liver.



MODERN PATHOLOGY

- BLOOD BANK
- DIGITAL X-RAY
- ULTRASONOGRAPHY
- COLOUR DOPPLER
- BIOCHEMISTRY
- MICROBIOLOGY
- HISTOPATHOLOGY

Patient Name : Mr Mukesh Mishra
S.NO. 101

Patient ID : 0000057

Age & Sex : 67 Year - Male

Referred By : Dr ASHOK MOHANTY
D.H.S.
M.I.M.S.,M.A.A.V.R

Registration Date : 01/03/2018 02:08 PM

Accession Date : 01/03/2018 02:08 PM

Report Date : 01/03/2018 02:08 PM

Center Name : MODERN LAB

Ultrasound examination of Whole Abdomen

Liver is normal in size (12.0 cm in MCL) and parenchymal echotexture of liver is normal. The intra hepatic biliary radicles look normal. No focal lesion seen. Portal vein is normal in caliber.

The gall bladder is well distended and show slightly thick walls. Its lumen is filled with sludge. Few small echogenic foci noted in the GB lumen. The larger one measuring about 5-6 mm in size. The CBD is normal.

Spleen is normal in size (8.3 cm) and pancreas are normal.

The aorta, inferior vena, cava, pre and para aortic regions look normal.

Abdominal lymph nodes are not enlarged.

Visceral bowel loops show normal peristalsis.

Right kidney : 8.6 x 3.7 cm Left kidney : 8.5 x 4.5 cm

Both Kidneys appear normal in size, shape and echogenicity. No calculus, hydronephrosis, or perinephric pathology seen.

Urinary bladder is partially distended and normal. Its wall shows normal thickness. No focal mass seen.

Prostate appears normal in size (3.4 x 2.5 x 3.4 cm, wt-15-16 gm) and echogenicity. No free fluid seen in the peritoneal cavity.

IMPRESSION :- Cholelithiasis with ? Cholecystitis with GB sludge.

Please correlate clinically.

Note - Not valid for M.L.C. purpose. USG is an aid to diagnosis. All findings must be correlated clinically. Case may be reviewed if necessary. All abnormalities could not be detected by USG. Further investigation may be needed if advised by consultant.

MODERN PATHOLOGY

- BLOOD BANK
- DIGITAL X-RAY
- ULTRASONOGRAPHY
- COLOUR DOPPLER
- BIOCHEMISTRY
- MICROBIOLOGY
- HISTOPATHOLOGY

Patient Name : Mr MUKESH NARAYAN S.NO. 25

Registration No. : 0000037

Age & Sex : 70 Year - Male

Referred By : DR ARPIT CHOPRA M.D

Reg Date : 05/08/2020 12:05 PM

Printed Date : 05/08/2020 12:54 PM

Ultrasound examination of Whole Abdomen

Liver is normal in size (11.1 cm in MCL) and parenchymal echotexture of liver is normal. The intra hepatic biliary radicles look normal. No focal lesion seen. Portal vein is normal in caliber.

The gall bladder is semi distended. Walls are thickened and echogenic causing dense posterior acoustic shadowing (WES complex). Lumen contains linear echogenic shadows along with hyperechoic solid contents. The CBD is normal.

Spleen is normal in size (8.1 cm) Homogenous echotexture

Pancreas is normal in size with normal echogenicity. MPD is un dilated. peripancreatic fat planes are thickened. No peripancreatic collection.

Right kidney : 8.7 cm Left kidney : 9.0 cm

Both kidneys appear normal in size, shape and echogenicity. No calculus, hydronephrosis, or perinephric pathology seen.

Urinary bladder is partially distended. Walls are thickened. Non lithiasic

Prostate appears normal in size (4.3 x 2.7 x 3.5 cm, wt - 22-23 gm) Calcifications are noted in the parenchyma.

Provoid : 133 ml Postvoid : 8 ml

No free fluid seen in the peritoneal cavity.

IMPRESSION :- Cholelithiasis with Chronic cholecystitis ? Prolitic GB.
:- Features of cystitis (PVR - 8 ml)

Please correlate clinically.

End Of Report

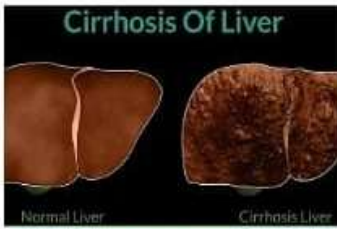IMPORTANT INSTRUCTIONS
Not valid for M.L.C. purpose. USG is an aid to diagnosis. All findings must be correlated clinically. Case may be reviewed if necessary. All abnormalities could not be detected by USG. Further investigation may be needed if advised by consultant.

DR. LIPENDRA SOLANKI

DR. MANISHA SHARMA

DR. ANIL SHARMA

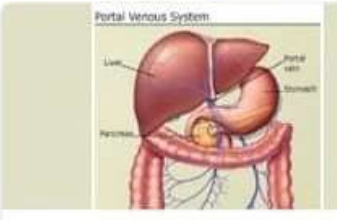
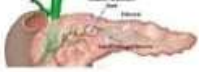
DR. MONISH DUBEY



Normal Liver Cirrhosis Liver

CHRONIC PANCREATITIS

- Chronic pancreatitis is a continuous, prolonged, inflammatory and fibrosing process of the pancreas.
- Progressively destroyed as it is replaced with fibrotic tissue.
- Strictures and calcification may also occur in pancreas



Portal hypertension is an increase the blood pressure within a system veins called the **portal venous system** coming from the stomach, intestine, spleen, and pancreas me into the **portal vein**, which then branches into smaller vessels and travels through the liver. Dec 21, 2018

Plasma: Adults
Ref No: 4430000
Investigation: HEMATOLOGY
Specimen: Whole Blood
Test: Hemoglobin
Result: 15.5 g/dL
Reference Range: 13.5-16.5 g/dL
Test: Hematocrit
Result: 47.5 %
Reference Range: 37-47 %
Test: Hematocrit (Corrected)
Result: 47.5 %
Reference Range: 37-47 %
Test: Hemoglobin (Corrected)
Result: 15.5 g/dL
Reference Range: 13.5-16.5 g/dL
Test: Hemoglobin A1c
Result: 5.6 %
Reference Range: 4.0-6.0 %
Test: Hemoglobin A1c (Corrected)
Result: 5.6 %
Reference Range: 4.0-6.0 %

Plasma: Adults
Ref No: 4430000
Investigation: CHEMISTRY
Specimen: Serum
Test: Total Bilirubin
Result: 1.2 mg/dL
Reference Range: 0.1-1.2 mg/dL
Test: Total Bilirubin (Corrected)
Result: 1.2 mg/dL
Reference Range: 0.1-1.2 mg/dL
Test: Total Bilirubin (Corrected) (MCHC)
Result: 1.2 mg/dL
Reference Range: 0.1-1.2 mg/dL
Test: Total Bilirubin (Corrected) (MCHC) (Corrected)
Result: 1.2 mg/dL
Reference Range: 0.1-1.2 mg/dL

Plasma: Adults
Ref No: 4430000
Investigation: CHEMISTRY
Specimen: Serum
Test: Aspartate Aminotransferase (AST)
Result: 12 U/L
Reference Range: 0-37 U/L
Test: Alanine Aminotransferase (ALT)
Result: 18 U/L
Reference Range: 0-40 U/L
Test: Gamma-Glutamyl Transaminase (GGT)
Result: 120 U/L
Reference Range: 0-60 U/L
Test: Alkaline Phosphatase (ALP)
Result: 120 U/L
Reference Range: 0-120 U/L
Test: Total Bilirubin
Result: 1.2 mg/dL
Reference Range: 0.1-1.2 mg/dL
Test: Total Bilirubin (Corrected)
Result: 1.2 mg/dL
Reference Range: 0.1-1.2 mg/dL
Test: Total Bilirubin (Corrected) (MCHC)
Result: 1.2 mg/dL
Reference Range: 0.1-1.2 mg/dL
Test: Total Bilirubin (Corrected) (MCHC) (Corrected)
Result: 1.2 mg/dL
Reference Range: 0.1-1.2 mg/dL

KARAN X-Rays, Sonography & Color Doppler Clinic
 14, Bhagatji Market opp. vijayaraje school, Freeranj Ujjain - 456001
 Clinic : 2514235, 4370376
 Date: - 24/07/2019
 Pt. Name: - Mr. Ashwin Boiragi
 Ref. By Dr: - Arpit Chopra.
 Ultrasonography of: - WHOLE ABDOMEN. SCREENING.
 Pleural cavities are clear.
 No ascites seen.
 Liver: Is normal in size, with echogenic firm looking texture. Outlines slightly irregular. Biliary tree is unaltered. No focal mass seen. Right lobe measures 14 cm CC in MCL.
 Gallbladder: Is normal in size, smooth with smooth walls and nonthick.
 Pancreas: Is small and atrophied CBD 5 mm. No peri pancreatic cyst or collection. Portal cavernoma seen extending to right lobe liver.
 Spleen: Slightly enlarged with homogenous texture. It measures 11.7 cm in size.
 Kidneys: Both are normal in size, shape and texture with smooth outlines and normal calyces. Cortical thickness and cortico-medullary differentiation is adequate.
 Ureters: Both are normal in upper and lower third.
 Bladder: Is normal, with smooth walls and nonthick.
 Prostate: Is normal with smooth homogenous texture.
 Bowel loops normal.
 RIF is clear.
 No mass, adenopathy or free fluid seen.
IMPRESSION: Chronic liver disease and chronic pancreatitis. Better than previous report.
 Dr. Suresh Sharma, DMRD

Chronic Liver Cirrhotic with Chronic pancreatitis & portal Hypertension
 THURSDAY 01 AUGUST
 श्री पुत्र अश्विन वैरागी जिसको करीब एक वर्ष से चिकित्सा के लिए आ रहे हैं। वे पानी पीने से बचना, खाने में तुरंत रुकना, और पेट में दर्द महसूस करना शुरू कर चुके हैं। इनके लक्षणों और प्रयोग किए गए दवाओं के बारे में जानकारी के लिए हमें सलाह देना है।
 श्री अश्विन वैरागी के लक्षणों और प्रयोग किए गए दवाओं के बारे में जानकारी के लिए हमें सलाह देना है।
 श्री अश्विन वैरागी के लक्षणों और प्रयोग किए गए दवाओं के बारे में जानकारी के लिए हमें सलाह देना है।
 श्री अश्विन वैरागी के लक्षणों और प्रयोग किए गए दवाओं के बारे में जानकारी के लिए हमें सलाह देना है।
 श्री अश्विन वैरागी के लक्षणों और प्रयोग किए गए दवाओं के बारे में जानकारी के लिए हमें सलाह देना है।
CURED.
 9754370900
 आरोग्य सुपर स्पेशलिटी मॉडर्न होम्योपैथिक क्लिनिक
 102 प्रथम मंजिल कृष्ण टॉवर बंगलावाट इन्डोर के सामने, जलौपाला रोड, न्यू पालीवाट, इन्दौर
 संपर्क: सुबह 10 बजे से रात 10 बजे तक, 24x7 सहायता: सुबह 12 बजे से रात 10 बजे तक
 संपर्क: सुबह 10 बजे से रात 10 बजे तक, 24x7 सहायता: सुबह 12 बजे से रात 10 बजे तक
 संपर्क: सुबह 10 बजे से रात 10 बजे तक, 24x7 सहायता: सुबह 12 बजे से रात 10 बजे तक

AAROGYA SUPERSPECIALITY MODERN HOMOEOPATHIC CLINIC (Computerised)
Dr. Arpit Chopra (Jain)
 (MD HOMOEOPATHY)
 CRITICAL CASE SPECIALIST
 Reg. No: 14367
 Phone: 0231-4977076, 2532737
 Mobile: 97130 82737, 87130-37737
 WhatsApp: 9999-78894, 99075 2791475
 Website: www.homoeopathy.com
 102, First Floor, Krishna Tower in front of Curawal Hospital Jangar Was Square, INDORE (M.P)
 Time: Morning 10 am to 3 pm, 5 pm to 10 pm
 Sunday: 11 am to 2 pm
 Email: arpitchohra2@gmail.com
 www.aarogyasuperspecialty@gmail.com
 Name: Ashwin Boiragi, Age: 28, Sex: M, Date: 12/01/19
 Address: Daba Road, Indore, Dist: M.P.
 Phone: 8770667674, Ref No: 1201193.
 Chronic Pancreatitis & Cirrhotic lesions
 Liver Cirrhosis
 Portal Hypertension
 Moderate Splenomegaly
 Ascites
 Abdominal pain (++)
 Vomiting
 Gas (++) / Constipation (+)
 23/07/19
 12/02/19
 12/02 to 12/03
 800/- Paid

आरोग्य सुपर स्पेशलिटी मॉडर्न होम्योपैथी क्लिनिक

अल्सरेटिव कोलाइटिस (पुसी)
ULCERATIVE COLITIS (UC)

DR. ARPIT CHOPRA JAIN
Modern Homoeopathy

आरोग्य सुपर स्पेशलिटी मॉडर्न होम्योपैथी क्लिनिक (आरोग्य सुपर स्पेशलिटी मॉडर्न होम्योपैथी क्लिनिक) का पता: 201, 202, 203, 204, KRISHNA TOWER, JANGERWALA SQUARE, IN FRONT OF GURUNANAK HOSPITAL, ROAD, NEW PALAZA, INDORE, MADYA PRADESH 472001

आरोग्य सुपर स्पेशलिटी मॉडर्न होम्योपैथी क्लिनिक

गैस्ट्रिक समस्या
GASTRIC PROBLEM

DR. ARPIT CHOPRA JAIN
Modern Homoeopathy

आरोग्य सुपर स्पेशलिटी मॉडर्न होम्योपैथी क्लिनिक (आरोग्य सुपर स्पेशलिटी मॉडर्न होम्योपैथी क्लिनिक) का पता: 201, 202, 203, 204, KRISHNA TOWER, JANGERWALA SQUARE, IN FRONT OF GURUNANAK HOSPITAL, ROAD, NEW PALAZA, INDORE, MADYA PRADESH 472001

Title
Gastric Problem Gas Flatulence
Dyspepsia में राहत मिली - Dr Arpit Chopra
Jain Modern Homoeopathy

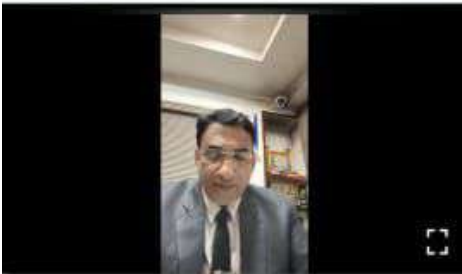12

आरोग्य सुपर स्पेशलिटी मॉडर्न होम्योपैथी क्लिनिक

आरोग्य सुपर स्पेशलिटी मॉडर्न होम्योपैथी क्लिनिक (आरोग्य सुपर स्पेशलिटी मॉडर्न होम्योपैथी क्लिनिक) का पता: 201, 202, 203, 204, KRISHNA TOWER, JANGERWALA SQUARE, IN FRONT OF GURUNANAK HOSPITAL, ROAD, NEW PALAZA, INDORE, MADYA PRADESH 472001

आरोग्य सुपर स्पेशलिटी मॉडर्न होम्योपैथी क्लिनिक (आरोग्य सुपर स्पेशलिटी मॉडर्न होम्योपैथी क्लिनिक) का पता: 201, 202, 203, 204, KRISHNA TOWER, JANGERWALA SQUARE, IN FRONT OF GURUNANAK HOSPITAL, ROAD, NEW PALAZA, INDORE, MADYA PRADESH 472001

आरोग्य सुपर स्पेशलिटी मॉडर्न होम्योपैथी क्लिनिक (आरोग्य सुपर स्पेशलिटी मॉडर्न होम्योपैथी क्लिनिक) का पता: 201, 202, 203, 204, KRISHNA TOWER, JANGERWALA SQUARE, IN FRONT OF GURUNANAK HOSPITAL, ROAD, NEW PALAZA, INDORE, MADYA PRADESH 472001



Description

Gastrointestinal disease
गैस्ट्रोलाँजी रोगों का सुरक्षित उपचार
आरोग्यसुपरस्पेशियलिटीआधुनिकहोम्योपैथी

3 Likes 33 Views 13 Oct 2025

Gastrology diseases safe & fast treatment by Dr Arpit Chopra Jain Aarogya super speciality modern homoeopathy Indore
अर्पित चोपड़ा जैन आरोग्य सुपर स्पेशियलिटी आधुनिक होम्योपैथी इंदौर द्वारा गैस्ट्रोलाँजी रोगों

BENCHMARK DIAGNOSTICS
a small light of hope can lead you your whole life
Dr. Parul Pandit
 MBBS, MD (Radiology)
 Reg. No. 900
 Consultant - Radiology Hospital, Indore
 * Ex-Consultant - ILS Hospital, Indore
 - Liver, Hepato Biliary

NAME OF PT: **MR LAKSHYA PRAJAPAT (47/M)**
 RES. BY: **DR A K SHAKYA**
 DATED: **19 September, 2025.**

Before Treatment

SONOGRAPHY OF WHOLE ABDOMEN AND PELVIS

Liver is normal in size, shape and outline. It measures 10.7 cm in AP diameter. Its parenchymal echo pattern shows increase in periportal echogenicity. A hypoechoic heterogeneous lesion seen in left lobe of liver in segment IV showing irregular wall and no internal vascularity. It shows mobile echoes within. Findings are s/o liquefied liver abscess. It measures 40x44x44mm (volume 30cr).

Portal vein and CBD are of normal caliber. Multiple periportal nodes are seen larger one measuring 2x14mm.

Gall bladder is well distended, shows fine bright internal echoes. A calculus of 5-6mm seen in fundus region. Its walls are smooth.

Spleen, pancreas and para-aortic areas do not show any abnormality. Spleen measures 7 cm in long axis.

Both kidneys show normal size, shape and echotexture. Right kidney measures 6.9x3 cm and left kidney measures 7x3.5 cm. Parenchymal echogenicity and Cortico-medullary difference is normal. No mass lesion, calculus or hydronephrotic changes seen. Ureters are not dilated. Urinary bladder is partially filled with smooth and regular outline. No free fluid seen in abdomen.

Please correlate. Further evaluation and follow up is suggested.

Dr. Parul Pandit
 MBBS, MD (Radiology)

This Report is not valid for medico-legal purpose.
 Office: 211, 2nd Floor, Benchmark Business Park, Near Surya San Square, Opposite Gujarat Sahitya, Vidya Vihar,
 For Appointment: Sonography: 9999044444, Pathology: 9999044444

SHRI KRISHNA DIAGNOSTIC CENTER
 18 GE, Sub. No. 04, Near Shantari & Jyoti Hospital, Opp. Mughalpur Garden, Vijay Nagar, Indore - 492010
 ☎ 0731-2600958, 0731-2601089
 ☎ 01119-108600 Timings: 8 am to 11 PM
 ✉ shrikshnadiagnostics@gmail.com | 24x7 Emergency services available

3D + 4D SONOGRAPHY | PATHOLOGY | MRI | CT SCAN | 2D ECHO | TMT | ECG | DIGITAL X-RAY | EEG

Name: **Master Lakshya Prajapat** Age: **4 Y/M**
 Ref: **Dr. A.K Shakya** Date: **26.09.2025**

USG WHOLE ABDOMEN

Liver: Liver is mildly enlarged size measuring approximately 10.6 cm with normal echotexture. A liquefied lesion is noted in left hepatic lobe measuring approximately 19 cr in volume with minimal adjacent edema noted.

No evidence of intrabiliary or extrahepatic biliary dilatation noted. Portal vein appears unremarkable. Common bile duct appears unremarkable.

Gallbladder: Gall bladder appears normal. No wall thickening is noted. No calculus is noted.

Pancreas: Pancreas appears normal in size, shape and position.

Spleen: Spleen is normal in size measuring approximately 5.0 cm.

Kidneys: Bilateral kidneys are normal in size, shape and position. Right kidney measures approximately 6.0 cm. Left kidney measures approximately 6.2 cm. Normal cortical medullary differentiation is noted. No evidence of hydronephrosis is noted. Both the ureters not dilated. No evidence of calculus is noted. No focal lesion is noted.

Urinary bladder: Urinary bladder is normal. No calculus is noted.

Bowel loops appear unremarkable. No evidence of significant ascites or lymphadenopathy noted in the abdomen. No evidence of significant pleural effusion seen on either side. Aorta and IVC appears unremarkable.

IMPRESSION:

> **Mild hepatomegaly with liquefied abscess in left hepatic lobe.**

Dr. Nirmal Phulwani
 MBBS, MD, PhD
 Consultant Radiologist
 Reg. No. MP-20973

Note: Ultrasonnd finding have limitation, it has to be correlated with the clinical findings. In case of any discrepancy a report was advise. Not for medico-legal purpose. Typographical errors is reported in case of double please contact us for correction.

During Dr Arpit Chopra Jain Modern Homoeopathy Treatment

Types of Liver Abscess

A pyogenic abscess (pus-filled cavity) may be caused by an infection due to illness or trauma

LIQUEFIED LIVER ABSCESS : SEP 25

MEASURES 40X44X44MM (19/09/25)

आरोग्य सुपर स्पेशलिटी मॉडर्न होम्योपैथीक वि
AAROGYA SUPER SPECIALITY MODERN HOMOEOPATHIC C

केसर, किडनी केलिया, अस्त्राल में रंगीत रूप से भरी मीठा का उपचार, कोमा, शल्य चिकित्सा योग्य अतिरिक्त रोग, ऐंसेमिया, मस्तिष्क किडनी, जीवात भर रोग जैसे गले रोगोंकि रोकथाम एवं 3000 प्रकार के अस्त्राल जलिन रोगों की

Consultation Available
 0731-4977076 • +91 790999-76894 • +91 97130-92737 • +91 03404-95672 • +91 99075-27914 • +91 97130-37737, 080461-32033, +91

Address: 101, 102, 103, 104, Krishna Tower, Janjeerwala Square, in front of Curewell Hospital Road, New Palasia, Indore, Madhya Pradesh 452001
 Email:- arpitchopra23@gmail.com



222 Yashwantrao Road, Indore (M.P.)
 Plot No. 2, Dussehra Market Road, Showapur
 Colony, Annapurna Main Road, Indore (M.P.)
 www.sangamranging.com

Before treatment

PATIENT NAME - SHANNDRA SINGH GOUR	DATE - 19/06/2021
REF. BY DR. ARPIT CHOPRA	AGE/SEX - 54/M/MALE

WHOLE ABDOMEN SONOGRAPHY

Hepatic contour is smooth & span (18.5 cm) is enlarged. Parenchymal architecture is raised. No focal lesion is seen. Intrahepatic biliary radicles are unremarkable.
 Gall bladder is normally distended. Walls are thin. No sludge or calculus is seen. CBD & Portal vein are normal in caliber.
 Visualized part of Pancreas is normal in shape & size. Parenchymal echoes are normal. Pancreatic duct is unremarkable.
 Spleen is normal 9.4 cm. No focal lesion seen.
 Both kidneys are normal in position & size. Renal contour is smooth. Cortical echoes are normal. Pelvicalyceal system is unremarkable.
 Right kidney is 10.3 x 4.9 cm and Left kidney is 10.7 x 5.3 cm in size.
 A calculus of size 4 mm seen mid calyx of left kidney.
 Urinary bladder shows normal wall & echo free lumen.
 Prostate is normal in size & echotexture. Weight is 24.4 grams.
 No significant retroperitoneal lymphadenopathy seen.
 No free fluid seen in peritoneal cavity. The dependent pleural spaces are normal.

- IMPRESSION:-**
- Hepatomegaly with fatty liver grade II.
 - Left renal calculus.

Clinical Correlation / further evaluation.
 DR. VAISHALI KUNDU
 MD, RADIO DIAGNOSTIC, FETAL
 MEDICINE SPECIALIST (SIBCO), (DELHI),

Cure your Fatty Liver



क्या आप **फैटी लिवर** समस्या से परेशान है **फैटी लिवर को कैसे खतम करे** सबसे **स्टोरी** By pat

Successful treatment by **Modern Homeopathy**



BANSAL DIAGNOSTIC CENTRE
 Pathology | Sonography | X-Ray | ECG | Echo | Dermatology | CT Scan

11 Anand Nagar, Indore, M.P. 472001

WHOLE ABDOMEN SONOGRAPHY

Both kidneys are normal in position & size. Renal contour is smooth. Cortical echoes are normal. Pelvicalyceal system is unremarkable.
 Right kidney is 10.3 x 4.9 cm and Left kidney is 10.7 x 5.3 cm in size.
 Urinary bladder shows normal wall & echo free lumen.
 Prostate is normal in size & echotexture. Weight is 24.4 grams.
 No significant retroperitoneal lymphadenopathy seen.
 No free fluid seen in peritoneal cavity. The dependent pleural spaces are normal.

IMPRESSION:-

- Grade II fatty changes in liver.
- Prostate is enlarged 24.4 gm (normal 18-22 gm).
- Small, umbilical hernia noted of 1.5 cm (Content - Fat).
- Adv - clinical correlation.

After Dr. Arpit Chopra Jain Modern Homoeopathy

Fatty Liver Patient From Indore Treatment at Dr. Ar...
 Dr Arpit Chopra's SuperSpecialty ModernHomoeopathic · 189 views · ...

क्या **फैटी लिवर** से परेशान हैं **फैटी लिवर को कैसे खतम करे**

Stages of Liver Damage

reversible irreversible

Healthy Non-Alcoholic Fatty Liver Disease Cirrhosis

Patient - Amit Mishra Dr. Arpit Chopra Jain

Treatment Of Fatty Liver By Modern Homeopathy

क्या **फैटी लिवर** से परेशान हैं **फैटी लिवर को कैसे खतम करे**

Dr. Arpit Chopra Jain Patient - Sandeep Singh

Treatment Of fatty liver By Modern Homeopathy

Fatty Liver Grade 3 | Cured by Dr Arpit Chopra's SuperSpecialty

ULCERATIVE COLITIS CURED
 Dr Arpit Chopra's SuperSpecialty
 1.7K views · 1 year ago

WORLD LIVER DAY

Gastric and Hepatic disorders treated by Dr. Arpit Chopra Jain

IBS IRRITABLE BOWEL SYNDROME
 Dr Arpit Chopra's SuperSpecialty
 2.6K views · 1 year ago

आरोग्य सुपर स्पेशलिटी मॉडर्न होम्योपैथिक क्लिनिक

AAROGYA SUPER SPECIALITY MODERN HOMOEOPATHIC CLINIC

कैंसर, किडनी फेलियर, अस्पताल में गंभीर रूप से भर्ती मरीज का उपचार, कोमा, शल्य चिकित्सा योग्य ऑटोइम्यून रोग, अप्लास्टिक ऐनीमिया, मस्क्युलर डिस्टॉफी, जीवन भर दवा लेने वाले रोगी की रोकथाम व 300 प्रकार के जसायज जटिल रोगों की चिकित्सा

Online Consultation Available

0731-4877676 (+91) 97240-87767 (+91) 80951-82994
 (+91) 90076-27924 (+91) 97240-92157 (+91) 97240-87767 (+91) 93404-05871 (+91) 79919-78984

Aarogya Super Spec...

Chronic Liver disease
Cirrhosis & Moderate...

Chronic Liver Disease
with ANA positive to...

Liver Disease Under
Control: Patient...

Visit >

WORLD LIVER DAY

For further information visit our website...

Chronic Liver Disease Under Control: Patient...

Chronic DIGESTIVE DISORDERS

Visit >

Liver Cirrhosis

Healthy liver

Chronic hepatitis

Hepatocellular carcinoma

Cirrhosis

Dr. Arpit Chopra Jain
(MD Homeopathy & Critical & Surgical Disease Specialist)

आरोग्य सुपर स्पेशलिटी मॉडर्न होम्योपैथिक क्लिनिक

LIVER CIRRHOSIS

Dr. Arpit Chopra Jain
(MD Homeopathy & Critical & Surgical Disease Specialist)

LIVER CIRRHOSIS का होम्योपैथिक से इलाज़

Responded story of
Liver Cirrhosis / लीवर...

Visit >

Aarogya Super Spec...
a day ago

Chronic Liver disease Cirrhosis & Moderate...

Visit >

Aarogya Super Spec...

Chronic Liver Disease with ANA positive to...

Visit >

आरोग्य सुपर स्पेशलिटी मॉडर्न होम्योपैथीक क्लिनिक
AAROGYA SUPER SPECIALITY MODERN HOMOEOPATHIC CLINIC

केसर, किडनी फेलिचर, अस्पताल में गंभीर रूप से घाती मरिजी का उपचार, कोषा, शल्य चिकित्सा योग्य अटो इन्फ्लूएंजा रोग, अजातकारिक प्लीहापिण्ड, मसूलापन हिस्ट्रीकी, जीवन भर दवा लेने वाले रोगीकी रोकथाम एवं 300 प्रकार के अलायम जटिल रोगों की चिकित्सा।

0731-4877076 • 02-79999-78894 • 01-97130-92737 • 01-93404-95872 • 01-99076-27014 • 01-97130-37737 • 01-80451-32033 • 01-7828318923

Address: 101, 102, 103, 104, Krishna Tower, Janjirwala Square, in front of Curramul Hospital Road, New Palasia, Indore, Madhya Pradesh 452001

Email: arpit Chopra23@gmail.com

DR. ARPIT CHOPRA JAIN
MD HOMOEOPATHY & MODERN & SURGICAL
SPECIALIST

AAROGYA SUPER SPECIALITY MODERN HOMOEOPATHIC CLINIC

DR ARPIT CHOPRA JAIN
MD HOMOEOPATHY CRITICAL & SURGICAL DISEASE SPECIALIST

Liver Disease Under Control: Patient From Morena Responds ...

Stages of Liver Disease Leading to Cirrhosis

before treatment

after Dr Arpit Chopra Jain Modern Homoeopathy treatment

कैंसर, किडनी फेलियर, अस्पताल में गंभीर रूप से भर्ती मरिजों का उपचार, कोमा, शल्य चिकित्सा योग्य रोग, ऑटो इम्यून रोग, जीवनभर दवाई लेने वाले रोगों की रोकथाम एवं 300 प्रकार के असाध्य जटिल रोगों की चिकित्सा।



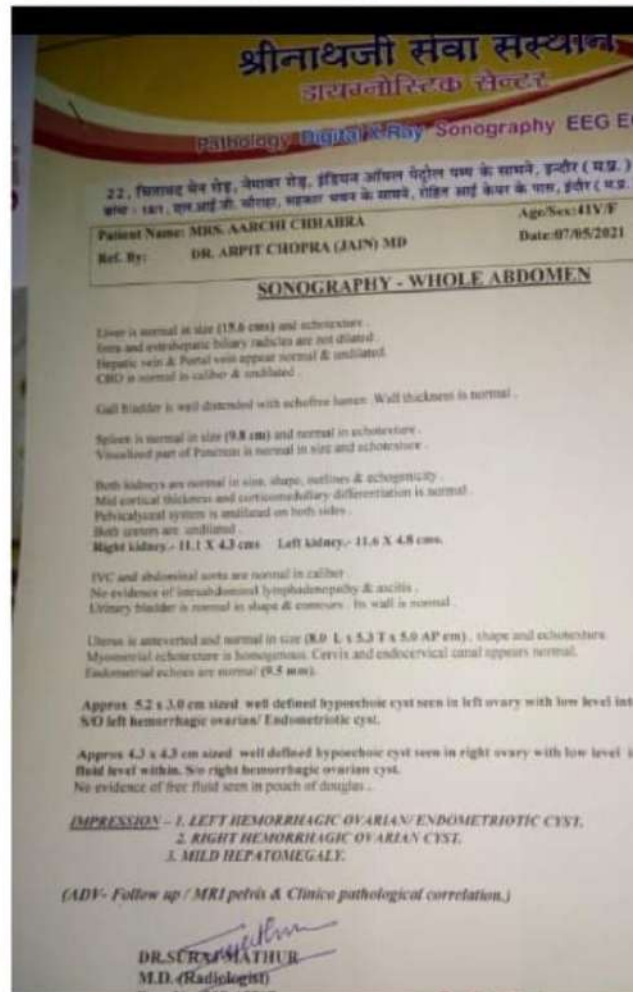
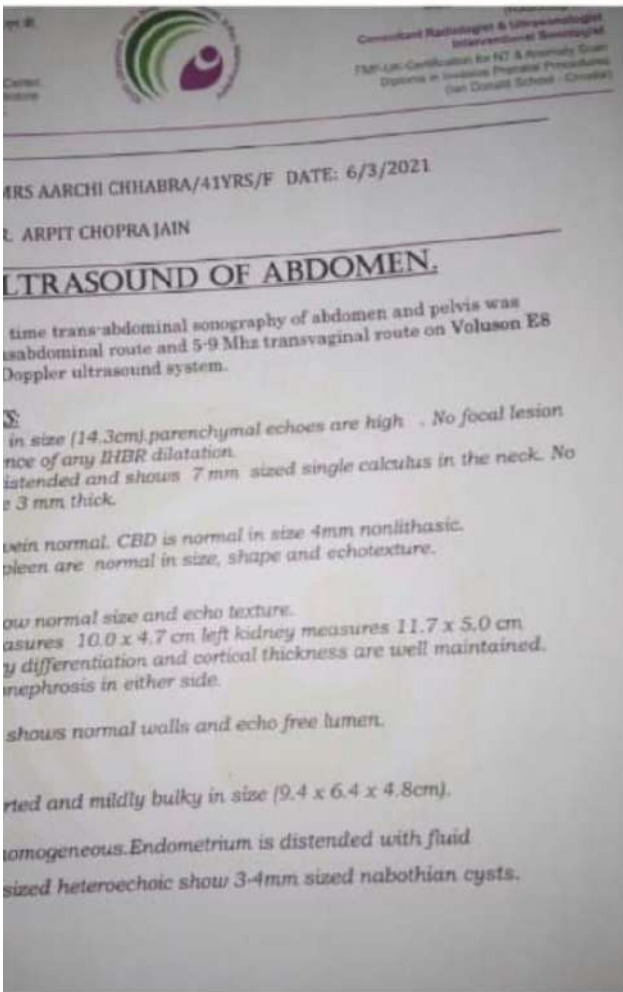
आरोग्य सुपर स्पेशलिटी मॉडर्न होमियोपेथी

कम्पलिट, परमानेन्ट, ईजी, सेफ, फास्ट एण्ड कॉस्ट इफैक्टिव

2, प्रथम मंजिल, कृष्णा टॉवर, क्योरवेल हॉस्पिटल के सामने, जंजीरवाला चौराहा, न्यू पलासिया, इन्दौर

99075 27914 संपर्क : 0731-4977076, 79999 78894

homoeopathycure.in, www.aarogyahomoeopathyindore.com Email : arpitchopra23@gmail.com



stones

Medical condition: cholelithiasis

View

Symptoms

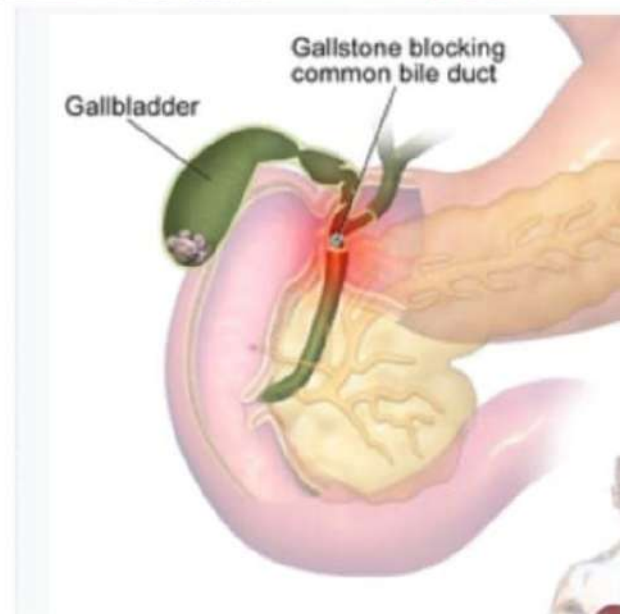
Treatments

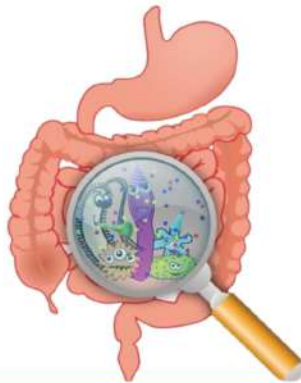Hard deposit within the fluid in the gallbladder, an organ under the liver.

They are hardened deposits of digestive fluid.

Common

There are 10 million cases per year (India)





Symptoms of Gastritis

- Nausea or recurrent upset stomach
- Loss of appetite
- Black, tarry stools
- Abdominal bloating
- Vomiting blood or coffee ground-like material
- Abdominal pain
- Indigestion
- Burning or gnawing feeling in the stomach between meals or at night
- Hiccups

गैस बनने के कारण

पेट में अत्यधिक गैस होने के लक्षण

कब्ज CONSTIPATION

DAIRY PRODUCTS

गैस्ट्रोइंटेस्टाइनल GASTRO INTESTINAL

SIDE-EFFECTS

गैस्ट्रिक समस्या GASTRIC PROBLEM

गुड और बेड बैक्टीरिया GOOD AND BAD BACTERIAS

क्यों होती है गैस की समस्या

कब्ज

ACUTE APPENDICITIS

Pooja Rajput Indore (M.P.)

HEPATOCELLULAR CARCINOMA

Chandrasingh Singh Parbhar Indore, M.P.

Understanding IBS

Bal Thakur

GERD

Pramod Chouhan Indore (M.P.)

- NO SURGERY
- COST EFFECTIVE
- NO SIDE EFFECT
- FAST TREATMENT
- PERMANENT CURE
- AGGRESSIVE THERAPY

LIVER CIRRHOSIS

Lal Bahadur Gupta Etawah, U.P.

Gall Stones

Anika Sayyad Indore (M.P.)

PANCREATITIS

Akash Gargur Haridwar, U.P.

CELIAC DISEASE

Urmila Sahu Bhopal (M.P.)



Service Project Infrastructure: Making Medical Care Accessible to All

"Medical facilities should be accessible to the common man in every way." Dr. Arpit Chopra Jain

To make his groundbreaking medical invention available to the general public, Professor Dr. Arpit Chopra Jain has established the Aarogya Super Speciality - Modern Homoeopathy Clinic, equipped with state-of-the-art facilities, at Janjirwala intersection in the heart of Indore city. At this clinic, patients have access to comprehensive consultation, diagnosis, and treatment for various diseases, all under one roof.

In addition, a dedicated consultation room for online patients has been set up to offer virtual consultations. Medicines are delivered through courier services, ensuring that even the most serious conditions can be treated from the comfort of one's home. Dr. Arpit Chopra Jain's initiative ensures that high-quality healthcare is not just limited to in-person visits but is also accessible to those in distant locations.



Dr. Arpit Chopra Jain: A Commitment to Service and Responsibility

Dr. Arpit Chopra Jain, raised in a family of doctors, embodies the true essence of a dedicated medical professional. With a deep sense of responsibility toward human welfare, he has revolutionized healthcare through his groundbreaking invention of Super Speciality Modern Homoeopathy treatment. His work has provided a new direction in treating complex diseases, ensuring that even those who once felt hopeless have found relief.

campaign to combat sickle cell anemia, Dr. Arpit Chopra Jain is also working tirelessly in tribal areas. His efforts contribute significantly to the permanent and successful treatment of this genetic disorder, further reflecting his unwavering commitment to the welfare of humanity.



Dr. Arpit Chopra Jain also organizes medical camps aimed at diagnosing complex diseases, providing free consultations to those in need. His sense of duty was especially evident during the devastating COVID-19 pandemic, where he took extraordinary measures to help his community. Understanding the gravity of the situation, he distributed free Corona prevention medicines to approximately 2,25,000 people, including Corona Warriors, potentially saving many lives.





Dr. Arpit Chopra Jain exemplifies what it means to be a physician who balances medical practice with social responsibility, continuing to make a profound impact on both individual lives and society as a whole.



Recognizing the significance of his role, Dr. Arpit Chopra Jain extends his responsibilities beyond medical practice. He considers it his moral and national duty to contribute to various social service activities. Along with treating complicated medical conditions, Dr. Arpit Chopra Jain is committed to shaping the future of homoeopathy. He actively mentors and educates new students entering the field, helping them gain the knowledge necessary to advance in medical science.





Samman Awards: A Tribute to Responsibility and Service

"Respect received from society increases responsibility." Dr. Arpit Chopra Jain

Dr. Arpit Chopra Jain believes that when one contributes responsibly and at the right time, society offers its respect. However, with that respect comes an even greater sense of responsibility.

Dr. Arpit Chopra Jain, through his groundbreaking invention of the Arogya Super Speciality Modern Homoeopathy medical system and his numerous social contributions, has garnered widespread recognition. His dedication to improving the health and well-being of others has not gone unnoticed. He has been honored by many prominent ministers, intellectuals, and senior artists across various dignified platforms. These awards have been bestowed upon him by social, national, and international institutions, further acknowledging his remarkable contributions to the field of medicine and humanity.

This recognition only fuels Dr. Arpit Chopra Jain's determination to continue serving society with even greater dedication and responsibility.











Media Recognition: A Source of New Enthusiasm and Energy

"Appreciation received through media gives us new enthusiasm and new energy." Dr. Arpit Chopra Jain

The work carried out by Professor Dr. Arpit Chopra Jain, especially his modern invention of the Aarogya Super Speciality Modern Homoeopathy treatment, has been widely acknowledged across various communication platforms. His dedication to serving humanity and offering innovative medical solutions has captured the attention of many renowned newspapers, news channels, and social media outlets.

स्वास्थ्य और चिकित्सा शिक्षा मंत्री ने किया 'संभव' का विमोचन

पुस्तक का लेखन एवं संपादन वरिष्ठ पत्रकार विजय कौशिक ने किया है

दिल्ली की भाई, कार्य प्रारंभ के बाद ही कोमेडोपैथी विचारधारा, प्रोफेसर डॉ. अरुण शर्मा जी ने अपने 20 वर्षों के चिकित्साकर्मियों अनुभव एवं विचारों के अन्वय में 'संभव' नामक पुस्तक लिखी है। डॉ. अरुण शर्मा जी का उद्देश्य है कि आम जनता को चिकित्सा शिक्षा और चिकित्सा व्यवस्था के बारे में सही जानकारी मिले, जिससे उनकी जीवन शैली, जीवन, चिकित्सा इत्यादि में सुधार आ सके।



पुस्तक का लेखन एवं संपादन वरिष्ठ पत्रकार विजय कौशिक ने किया है। डॉ. अरुण शर्मा जी का उद्देश्य है कि आम जनता को चिकित्सा शिक्षा और चिकित्सा व्यवस्था के बारे में सही जानकारी मिले, जिससे उनकी जीवन शैली, जीवन, चिकित्सा इत्यादि में सुधार आ सके।

होम्योपैथी में अनुसंधान और साक्ष्य-आधारित ट्रीटमेंट से भारत के साथ अन्य 19+ देशों में भी पहचान बनाने वाले डॉक्टर अरुण शर्मा



हैलथ भास्कर

अपनी मेहनत और जुनून से होम्योपैथी को नई पहचान दिला रहे- डॉ. अरुण शर्मा

आपका स्वास्थ्य ही आपकी पहचान है। डॉ. अरुण शर्मा जी का उद्देश्य है कि आम जनता को चिकित्सा शिक्षा और चिकित्सा व्यवस्था के बारे में सही जानकारी मिले, जिससे उनकी जीवन शैली, जीवन, चिकित्सा इत्यादि में सुधार आ सके।

जानिए 'मॉडर्न होम्योपैथी' के अविष्कार से कर रहे जादुई लाइफटाइम चेंजिंगों का सफल उदाहरण, चमत्कारपूर्ण परिणाम देकर लोगों को रहे हैं हैलथ

डॉ. अरुण शर्मा जी का उद्देश्य है कि आम जनता को चिकित्सा शिक्षा और चिकित्सा व्यवस्था के बारे में सही जानकारी मिले, जिससे उनकी जीवन शैली, जीवन, चिकित्सा इत्यादि में सुधार आ सके।

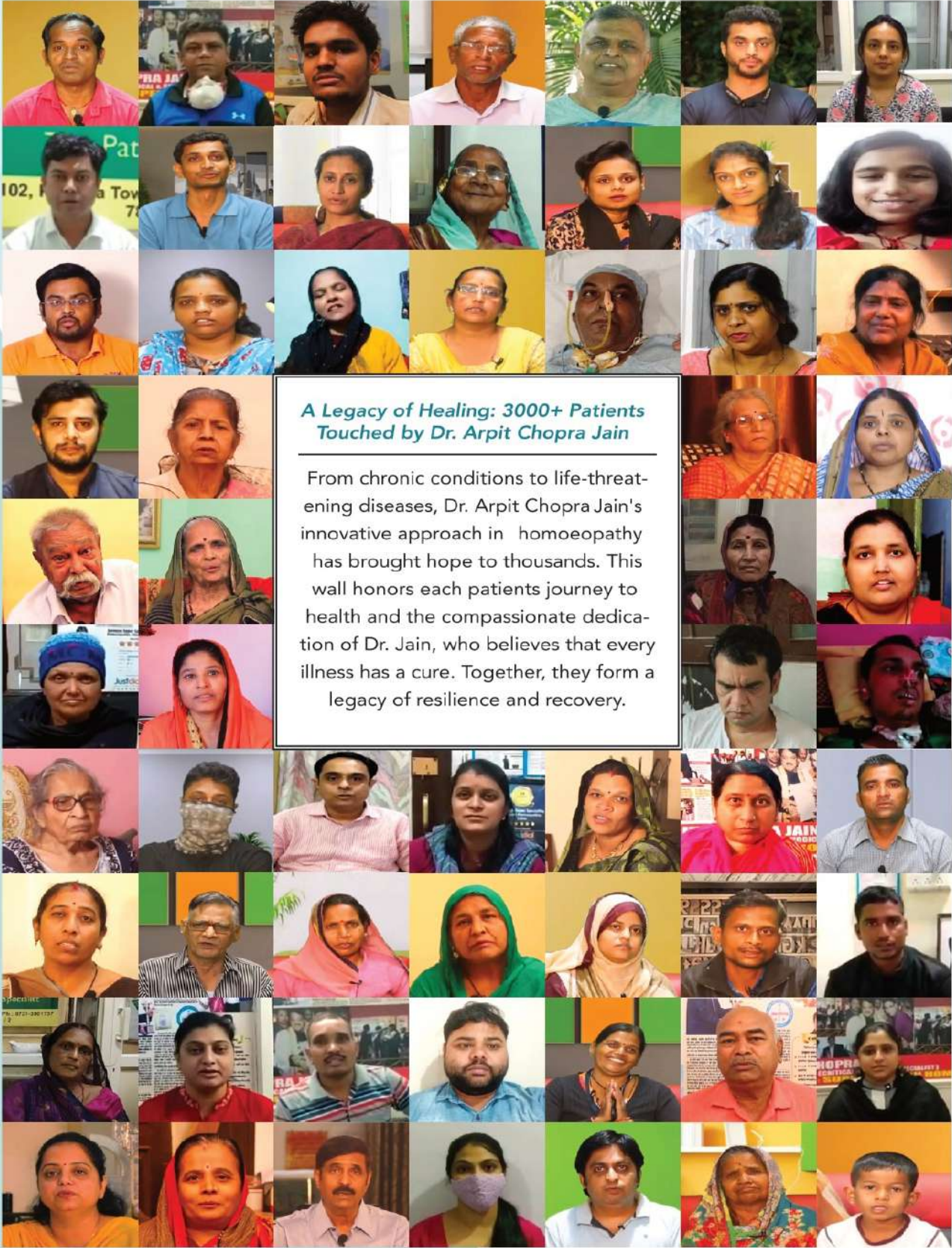सवालियाँ टीम करते हैं डॉक्टर

डॉ. अरुण शर्मा जी का उद्देश्य है कि आम जनता को चिकित्सा शिक्षा और चिकित्सा व्यवस्था के बारे में सही जानकारी मिले, जिससे उनकी जीवन शैली, जीवन, चिकित्सा इत्यादि में सुधार आ सके।

अरोग्य सुपर स्पेशलिटी मॉडर्न होम्योपैथी क्लीनिक

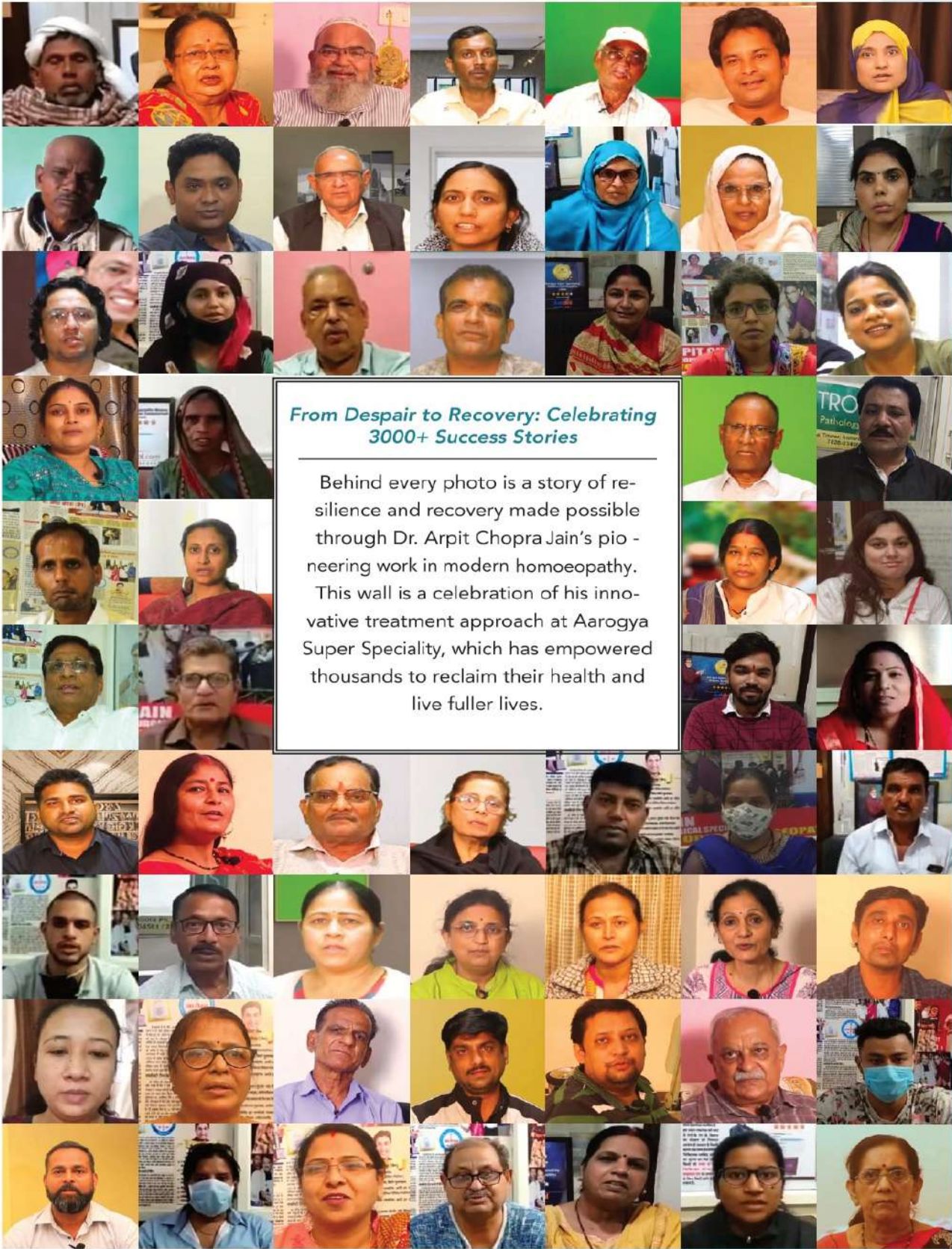Dr. Arpit Chopra Jain expresses his gratitude to the entire media world for their immense support in highlighting and promoting the future of homeopathy. Their coverage not only amplifies his efforts but also motivates him to continue on this path with renewed vigour and energy.





A Legacy of Healing: 3000+ Patients Touched by Dr. Arpit Chopra Jain

From chronic conditions to life-threatening diseases, Dr. Arpit Chopra Jain's innovative approach in homoeopathy has brought hope to thousands. This wall honors each patients journey to health and the compassionate dedication of Dr. Jain, who believes that every illness has a cure. Together, they form a legacy of resilience and recovery.



From Despair to Recovery: Celebrating 3000+ Success Stories

Behind every photo is a story of resilience and recovery made possible through Dr. Arpit Chopra Jain's pioneering work in modern homoeopathy. This wall is a celebration of his innovative treatment approach at Aarogya Super Speciality, which has empowered thousands to reclaim their health and live fuller lives.



Thank
You!



Possible solutions to complex, incurable and impossible diseases. Harmless, quick, economical and permanent treatment system, Homoeopathy of the future, Thank you for giving your valuable time to Super Speciality Modern Homoeopathy treatment system.


May you always live a happy life by staying physically,
mentally and socially healthy and fulfill the WHO standards


This is my wish, This is my effort...

Aarogya Super Speciality Modern Homoeopathy

101-104, First Floor, Krishna Tower, Opposite Curewell Hospital
New Palasia, INDORE (M.P.)

ONLINE CONSULTATION ALSO AVAILABLE

 @ 99075-27914, 79999-78894
@ 97130-92737, 97130-37737

 aarogya101

 [instagram.com/aarogyahomeopathy](https://www.instagram.com/aarogyahomeopathy)

 www.aarogyahomeopathyindore.com

www.aarogyahomeopathyindore.com
www.homoeopathycure.in
besthomoeopapathdoctorind.com

email : arpitchopra23@gmail.com, aarogyamodernhomeopathy@gmail.com

You Tube Link  - [drarpitchopramodernhomeopathic](https://www.youtube.com/channel/UCdrarpitchopramodernhomeopathic)